



ASNR Career Center

The Go-To Job Site for Neuroradiology Employers and Job Seekers
Start here: careers.asnr.org

AJNR

MR Imaging of Spinal Epidural Lipoma

James U. Morano, Jimmy D. Miller and John J. Connors

AJNR Am J Neuroradiol 1989, 10 (5 suppl) S102
http://www.ajnr.org/content/10/5_suppl/S102.citation

This information is current as
of June 3, 2023.

MR Imaging of Spinal Epidural Lipoma

Spinal epidural lipoma is an unusual lesion that most often causes signs and symptoms of spinal cord compression [1-3]. In the past, this lesion has been evaluated preoperatively by using myelography and CT. However, MR is now the diagnostic technique of choice because of the unique signal characteristics of fatty tissue, the noninvasive nature of the examination, and the ease of sagittal imaging.

Case Report

A 38-year-old man had a 2-month history of progressive numbness involving the left arm and subsequently both legs. He described tingling sensations in both legs but had no associated pain. He had no history of trauma or steroid use. The neurologic examination was normal with the exception of decreased vibratory and pain sensation below the T4 level; bilateral Babinski signs were present. Both CT and MR (Fig. 1) showed anterior displacement of the dural sac throughout a considerable length of the thoracic region by tissue located dorsally in the epidural space and having density and signal characteristics consistent with fat. While the patient was in the hospital, urinary retention developed. A laminotomy was performed from T2 to T8, and an abnormal increase of epidural fat, some of which appeared encapsulated, was removed. Postoperatively, the paraesthesia in the lower extremities cleared, and the patient required only occasional urinary catheterizations.

Discussion

Spinal epidural lipoma or lipomatosis usually occurs in the thoracic region, and most of the tumors are located within the epidural space dorsal to the dural sac [1, 3, 4]. The association of this lesion with steroid therapy or morbid obesity is high [1, 2, 5-7]. However, occasionally a patient has no known underlying cause [2, 5]. These lesions frequently cause signs and symptoms of spinal cord compression due to the increased mass effect of the fat tissue.

MR has supplanted CT and myelography as the imaging technique of choice in the evaluation of spinal epidural lipomas [4, 5]. No ionizing radiation or intrathecal administration of contrast material is necessary. In addition, MR is noninvasive and does not require a lumbar puncture. The ease in obtaining sagittal images facilitates evaluation of the full extent of the lesion.

As on the CT scan, fat does present a characteristic appearance on MR. Fat has a short T1 relaxation time, which is responsible for its high signal intensity on short TR, short TE images. A medium T2 relaxation time is responsible for the intermediate signal intensity of fat on long TR, long TE images.

James U. Morano

Jimmy D. Miller

John J. Connors

University of Mississippi, Medical Center
Jackson, MS 39216-4505

REFERENCES

- Goyal RN. Epidural lipoma causing compression of the spinal cord. *Surg Neurol* 1980;14:77-79
- Marks SM, Miles JB, Shaw MDM. Idiopathic spinal extradural lipomas: three cases and review of the literature. *Surg Neurol* 1985;23:153-156
- de Bruine JF, Bongartz EB. Spinal extradural lipomas. *Clin Neurol Neurosurg* 1983;85(3):181-190
- Toshinwal PK, Glick RP. Spinal epidural lipomatosis: report of a case secondary to hypothyroidism and review of literature. *J Neurol* 1987;234:172-176
- Healy ME, Hesselink JR, Ostrup RC, et al. Demonstration by magnetic resonance of symptomatic spinal epidural lipomatosis. *Neurosurgery* 1987;21(3):414-415
- Russell NA, Belanger G, Benoit BG, et al. Spinal epidural lipomatosis: a complication of glucocorticoid therapy. *J Can Sci Neurol* 1984;11(3):383-386
- Wiedemayer H, Nau HE, Reinhardt V, et al. Spinal cord compression by extensive epidural lipoma. *Eur Neurol* 1987;27:46-50

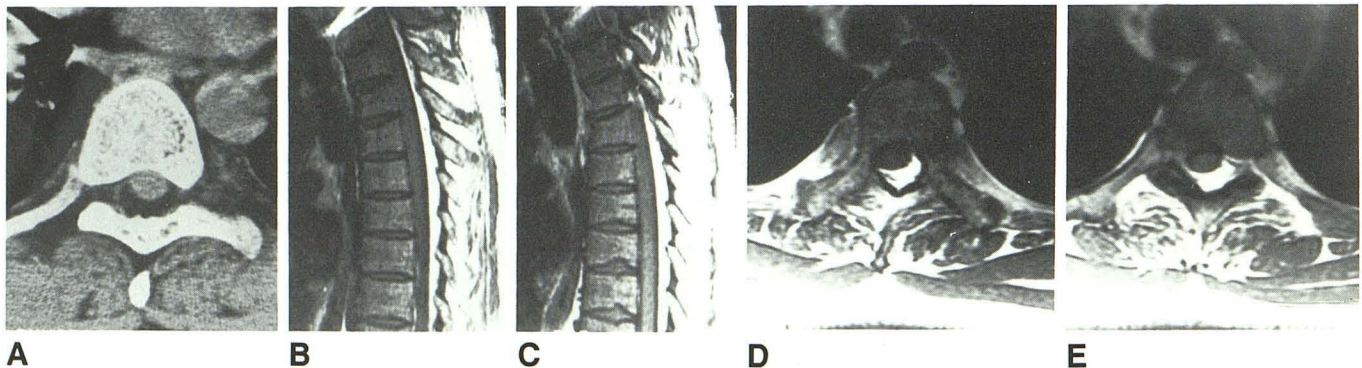


Fig. 1.—Spinal epidural lipoma.

A, CT scan at midthoracic level shows increased amount of fat density in an epidural location dorsal to thecal sac. Faint encapsulation of lesion is suggested on this image.

B and C, Sagittal T1-weighted MR images (800/20, four excitations) show high signal intensity consistent with an abnormal increase of fat in epidural space dorsal to thecal sac and extending over several levels in thoracic region.

D and E, Axial T1-weighted MR images (800/20) show increased accumulation of fat in epidural space of thoracic region, displacing thecal sac anteriorly.