

Are your **MRI contrast agents** cost-effective?

Learn more about generic **Gadolinium-Based Contrast Agents**.



FRESENIUS
KABI

caring for life

AJNR

Chronic Hematic Cysts of the Orbit

J. Geoffrey Wiot and Clifford W. Pleatman

AJNR Am J Neuroradiol 1989, 10 (5 suppl) S37-S39

http://www.ajnr.org/content/10/5_suppl/S37.citation

This information is current as
of May 5, 2024.

Chronic Hematic Cysts of the Orbit

J. Geoffrey Wiot¹ and Clifford W. Pleatman

Chronic hematic cyst is a rare intraorbital mass that presents with painless displacement of the globe and is usually caused by remote trauma [1, 2]. The imaging characteristics of orbital masses are frequently nonspecific; however, we believe that chronic hematic cysts have a characteristic appearance. We present two cases in which CT showed an expansile erosive mass in the roof of the orbit adjacent to the lacrimal fossa and MR revealed signal changes characteristic of hemorrhage, thereby confirming the diagnosis of chronic hematic cyst.

Case Reports

Case 1

A 38-year-old woman presented with a 10-year history of right frontal headaches and a 4-month history of an abnormal appearance around her right eye. The patient denied any history of trauma and admitted to frequent aspirin use. Examination revealed normal extraocular muscle function with diplopia on extreme right and upward gaze. Exophthalmometry showed 5 mm of right-sided exophthalmos and 6 mm of inferior displacement of the right globe.

CT showed a nonenhancing soft-tissue mass in the right lacrimal fossa that was isodense with muscle (Figs. 1A and 1B). There was smooth, nonsclerotic expansile erosion of the adjacent orbital roof and rim with no intracranial extension. A surgical biopsy revealed acute and organized hemorrhage.

Orbital MR was performed to exclude an occult hemorrhagic neoplasm before definitive surgery. The MR showed a well-defined extraconal mass in the lacrimal fossa displacing the globe and superior rectus muscle inferiorly and medially (Figs. 1C and 1D). The mass exhibited hyperintensity on T1- and T2-weighted sequences, which is characteristic of hemorrhage. At surgery, a blue-green subperiosteal encapsulated mass was found and removed. Histologic examination revealed acute and organized hemorrhage with foamy macrophages, cholesterol clefts, and chronic inflammation and fibrosis, but no evidence of tumor.

Case 2

A 37-year-old man presented with a several-year history of swelling of his right brow and a feeling of pressure around his right eye. The patient reported a history of blunt trauma to the right brow as a child

and chronic warfarin therapy for recurrent pulmonary emboli for 3 years.

Careful examination showed slight limitation to right and upward gaze in the right eye without diplopia. Exophthalmometry showed 5 mm of proptosis.

Noncontrast CT revealed a homogeneous soft-tissue mass in the lacrimal fossa of the orbit with associated expansion of the orbital roof (Figs. 2A and 2B). The diagnosis of chronic hematic cyst was suggested, and MR was performed for confirmation. A 2-cm extraconal mass was identified, displacing the superior rectus muscle and globe and showing hyperintense signal on T1- and T2-weighted sequences (Figs. 2C and 2D). A subperiosteal mass was found at surgery; histologic findings were similar to those of case 1.

Discussion

The term *chronic hematic cyst* was introduced by Milne et al. [3] to distinguish this lesion from other entities, including subperiosteal hematoma, blood cyst, and hematocele. *Subperiosteal hematoma* refers to a recent blood collection that usually is the result of acute trauma. *Blood cyst* is a general term that has been used to describe hemorrhagic orbital lesions that may be caused by a dermoid cyst, lymphangioma, or cavernous hemangioma [3]. *Hematocele* is an even less precise term; its use is discouraged.

The clinical presentation of chronic hematic cyst is nonspecific. The patient typically presents with painless and progressive displacement of the globe over months or years, often accompanied by diplopia. These cysts are usually found in young men after remote trauma to the orbit [3]. Often the trauma either is considered insignificant or totally forgotten by the patient [4]. A history of blood dyscrasia or anticoagulant therapy may be elicited, as in our cases.

Chronic hematic cysts commonly occur in a subperiosteal location, in the temporal portion of the orbital roof where the frontal bone forms the largest continuous concave surface of the orbit and the periosteum is less firmly attached [5]. Long-standing lesions cause smooth, curvilinear bony erosion and expansion of the orbital roof and rim. The mechanism of this slow, progressive expansion is unknown, but it has been suggested that the accumulation of hematogenous debris results in an osmotic gradient with subsequent accumulation

Received May 2, 1988; revision requested July 13, 1988; revision received August 29, 1988; accepted September 8, 1988.

¹ Both authors: University of Cincinnati Medical Center, University Hospital, Department of Radiology, 234 Goodman St., Cincinnati, OH 45267-0742. Address reprint requests to C. W. Pleatman.

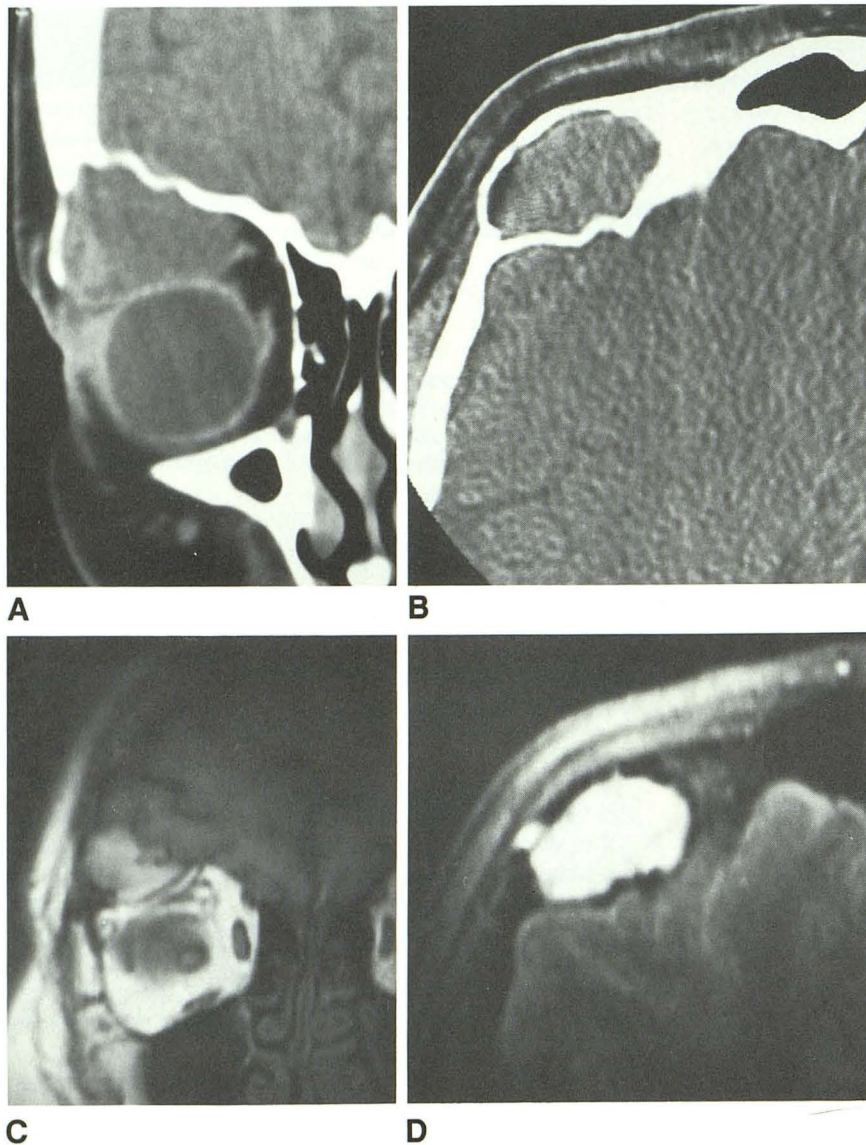


Fig. 1.—Case 1: Chronic hematic cyst.
 A and B, CT scans. Noncontrast coronal (A) and postcontrast axial (B) images show expansion of lacrimal fossa and downward displacement of globe by a nonenhancing extraconal mass.

C and D, MR images. Coronal T1-weighted image (800/20/4, 3-in. [7.62-cm] round surface coil) (C) and axial T2-weighted image (2000/80) (D) show an extraconal, lacrimal fossa mass with signal characteristics of nonacute hemorrhage.

of fluid and enlargement of the cyst. Recurrent hemorrhage due to fibrinolytic activity within the neomembranes of the chronic hematoma has been proposed, akin to the mechanism of enlargement of chronic subdural hematomas [6].

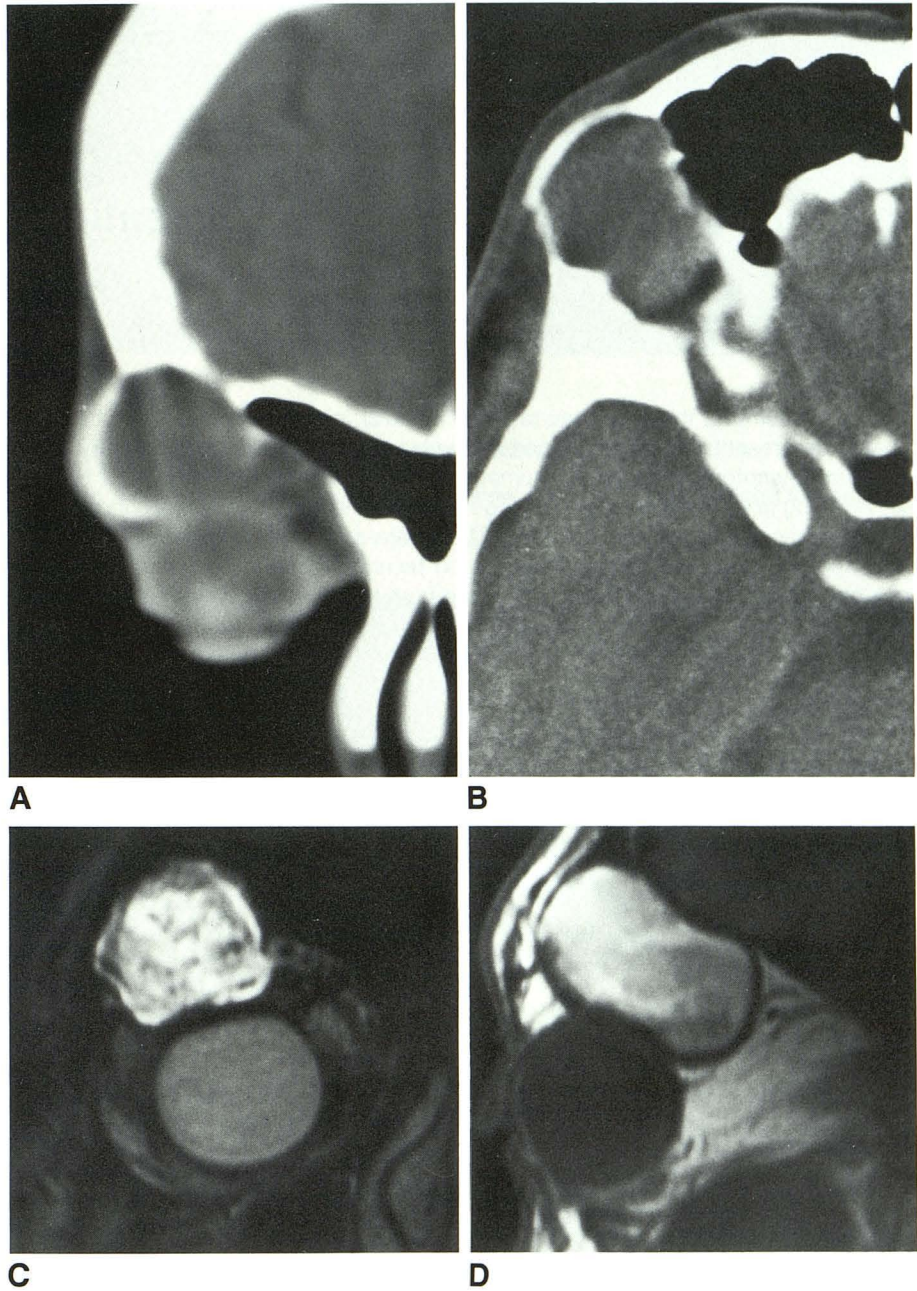
Histopathologic examination consistently reveals a fibrous pseudocapsule surrounding lipid-laden macrophages, chronic inflammatory cells, red blood cells, hemosiderin, and cholesterol clefts. This histologic picture is seen also in cholesterol granulomas of the petrous apex. However, cholesterol granulomas differ from hematic cysts in their etiology, typically arising as either a complication of chronic serous otitis media or an obstruction to both ventilation and drainage of the pneumatized spaces of the petrous apex [7].

Frequently the appearance of orbital masses is nonspecific; in our cases, CT raised the possibility of a lacrimal gland neoplasm, and MR showed an encapsulated mass with signal

changes characteristic of hemorrhage (which suggested the diagnosis of chronic hematic cyst). Other differential diagnoses, which conceivably could have identical MR characteristics, included infected dermoid, chronic mucocele, and hemorrhagic tumor. The lack of clinical evidence of infection and the clear separation of the mass from the frontal sinus indicated that the correct diagnosis was neither infected dermoid nor mucocele. Nonenhancement on CT and MR characteristics of hemorrhage pointed away from tumor. The diagnosis of chronic hematic cyst was therefore most likely. This information is important in the surgical planning and management of lacrimal fossa masses, because complete resection of a benign lacrimal gland tumor without incisional biopsy is necessary to avoid external seeding [8].

In conclusion, we believe that the CT demonstration of a lacrimal fossa mass with bony expansion and erosion is

Fig. 2.—Case 2: Chronic hematic cyst.
A and B, CT scans. Noncontrast coronal (A) and axial (B) images show expansion of lacrimal fossa by a soft-tissue mass.
C and D, MR images. Coronal T2-weighted image (1800/80) (C) and sagittal T1-weighted image (600/20) (D) show a lacrimal fossa mass with signal changes of hemorrhage.



suggestive of a chronic hematic cyst, and MR can reveal signal changes characteristic of hemorrhage to support this diagnosis.

ACKNOWLEDGMENTS

We would like to thank Robert Lukin for his editorial assistance and Susan Whisenhunt for preparation of the manuscript.

REFERENCES

1. Reese AB. *Tumors of the eye*, 3rd ed. Hagerstown, MD: Harper & Row, 1976
2. Henderson JW. *Orbital tumor*. Philadelphia: Saunders, 1973
3. Milne HL, Leone CR, Kincaid MC, Brennan MW. Chronic hematic cyst of the orbit. *Ophthalmology* 1987;94:271-277
4. Mund ML. Subperiosteal hematic cyst of the orbit. *Ophthalmology* 1981; 88:992-996
5. Seigel RS, Williams AG, Hutchison JW, Wolter JR, Carlow TJ, Rogers DE. Subperiosteal hematomas of the orbit: angiographic and computed tomographic diagnosis. *Radiology* 1982;143:711-714
6. Ito H, Yamamoto S, Komai T, Mizukoshi H. Role of local hyperfibrinolysis in the etiology of chronic subdural hematoma. *J Neurosurg* 1976;45:26
7. Lo WWM, Solti-Bohman LG, Brackmann DE, Gruskin P. Cholesterol granuloma of the petrous apex: CT diagnosis. *Radiology* 1984;153:705-711
8. Lloyd GAS. Lacrimal gland tumors: the role of CT and conventional radiology. *Br J Radiol* 1981;54:1034-1038