

MR Imaging of a Spinal Epidermoid Tumor

Primary epidermoid tumors are congenital lesions of ectodermal origin. Their appearance has been described with MR and CT in the calvarium [1-7]. Primary and secondary epidermoid tumors of the spine are rare tumors, and their MR appearances have not been described. We present a case of epidermoid tumor of the spinal canal that probably was caused by a lumbar puncture performed approximately 20 years earlier. The MR appearances both before and after administration of Gd-DTPA are illustrated.

Case Report

A 47-year-old woman presented with a left L5 radiculopathy and mild leg weakness. The patient had undergone a myelogram about 20 years earlier. A lumbar myelogram performed via an L2-L3 approach showed a complete block beginning at the mid-L3 level by an intradural mass. A postmyelogram CT through the L3-L4 disk showed complete blockage to flow by a mass with features of an intradural lesion. The density of the mass was similar to that of CSF (Fig. 1A). Before administration of gadolinium-DTPA (Gd-DTPA), MR showed the signal intensity of the mass to be similar to that of CSF on short-TR/TE images (Fig. 1B) and higher than that of CSF on long-TR/TE images (Fig. 1C). The MR findings after Gd-DTPA administration are shown in Figure 1D. At surgery, an intradural epidermoid tumor was found and a focal buttonlike area of scar tissue was seen at the dorsum of the sac at the level of the tumor. This most likely was scar tissue from the previous lumbar puncture, and the epidermoid tumor probably was caused by that lumbar puncture. Also noted at surgery was an L4-L5 herniated disk.

Discussion

Previously described MR images of intracranial epidermoid tumors include signal intensity that is both homogeneous and inhomogeneous, with either sharp or irregular margination and signal characteristics different from those of CSF and brain on short-TR and long-TR images [6]. Short-TR/TE images were said to show signal intensity intermediate between brain and CSF, with signal intensity higher than that of brain and CSF on long-TR/TE images [6]. Our case differs

from this in that the short-TR/TE signal is homogeneous and similar to that of CSF, whereas the long-TR/TE signal is higher than that of CSF. MR appearance of epidermoid tumors after Gd-DTPA administration has not been described previously; however, our case shows thin rim enhancement with smooth margination.

Epidermoid tumors have been shown to have signal characteristics different from CSF because they grow by desquamation of epithelial cells, which break down into keratin and solid cholesterol within the tumor capsule [7]. Thus, because the signal intensity differs from that of CSF on long-TR/TE images, differentiation from an arachnoid cyst can be made in our case [8]. Other differential diagnostic possibilities include cysticercus cyst, dermoid cyst, cystic astrocytoma, cystic ependymoma, and hemangioblastoma.

Cysticercus cysts usually have signal characteristics similar to those of CSF on all imaging sequences, whereas dermoid cysts may contain areas of calcifications [7]. Use of contrast material with MR imaging has helped differentiate between benign and malignant cysts within the spinal canal because contrast material can be used to enhance neoplastic foci [9]. Since very small neoplasms can be associated with cysts in the spinal canal [10], enhancement of soft-tissue tumor components should help in localizing benign cysts and differentiating them from malignant cystic tumors. In cases of hemangioblastoma, Gd-DTPA can pinpoint the nidus of the lesion [9].

Our case showed no areas of enhancement to suggest a soft-tissue component. Thus, this epidermoid tumor could be differentiated from cystic astrocytoma, cystic ependymoma, and hemangioblastoma. Because of the CT results and the MR findings (both before and after Gd-DTPA administration), epidermoid tumor was suspected before surgery.

Malcolm K. Hatfield
University of Chicago Hospital
Chicago, IL 60637

Richard H. Udesky
Arnold M. Strimling
B. H. Kim

Saint Mary's Hospital
Racine, WI 53405

Richard Silbergleit
University of Michigan Medical Center
Ann Arbor, MI 48109

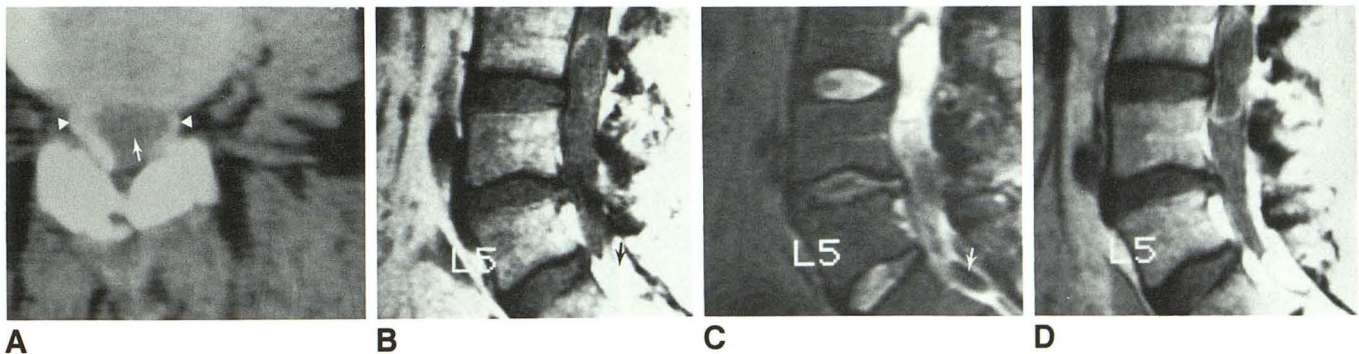


Fig. 1.—A, Axial CT through L3-L4 disk after intrathecal contrast administration shows intradural mass with density similar to CSF (arrow). Note contrast material around mass (arrowheads).

B and C, Before administration of Gd-DTPA, sagittal spin-echo images show ovoid, fairly sharply circumscribed intradural lesion with signal intensity similar to CSF on short-TR/TE (600/20/2) images (B); however, on long-TR/TE (2500/80/2) images, signal intensity of lesion is higher than CSF (C). Chemical shift artifact is noted along cephalad aspect of tumor. There is also a herniated disk at L4-L5, as well as a known prominent globule of Pantopaque in caudal sac (arrows).

D, After administration of Gd-DTPA, image in sagittal (600/20/2) plane shows thin rim enhancement, which is sharply marginated and somewhat irregular. No additional areas of enhancement to suggest a tumor nidus or soft-tissue component were seen.

REFERENCES

1. Davis KR, Roberson GH, Taveras JM, New PF, Trevor R. Diagnosis of epidermoid tumor by computed tomography. Analysis and evaluation of findings. *Radiology* **1976**;119:347-353
2. Braun IF, Naidich TP, Leeds NE, Koslow M, Zimmerman HM, Chase NE. Dense intracranial epidermoid tumors. Computed tomographic observations. *Radiology* **1977**;122:717-719
3. Vion-Dury J, Vincentelli F, Jiddane M, et al. MR imaging of epidermoid cysts. *Neuroradiology* **1987**;29:333-338
4. Inoue H, Toya S, Ohtani M, et al. Characteristic findings of metrizamide CT cisternography in epidermoids. *Acta Neurochir (Wien)* **1984**;73:207-211
5. Olson JJ, Beck DW, Crawford SC, Menezes AH. Comparative evaluation of intracranial epidermoid tumors with computed tomography and magnetic resonance imaging. *Neurosurgery* **1987**;21(3):357-360
6. Steffey DJ, DeFilipp GJ, Spera T, Gabrielsen TO. MR imaging of primary epidermoid tumors. *J Comput Assist Tomogr* **1988**;12(3):438-440
7. Yuh WT, Barloon TJ, Jacoby CG, Schultz DH. MR of fourth-ventricular epidermoid tumors. *AJNR* **1988**;9(4):794-796
8. Heier LA, Zimmerman RD, Russel EJ, et al. MR imaging of arachnoid cysts. Presented at the annual meeting of the Radiological Society of North America, Chicago, November **1985**
9. Sze G, Krol G, Zimmerman RD, Deck MDF. Intramedullary disease of the spine: diagnosis using gadolinium-DTPA-enhanced MR imaging. *AJNR* **1988**;9:847-858
10. Epstein F, Epstein N. Surgical treatment of spinal cord astrocytomas of childhood: a series of 19 patients. *J Neurosurg* **1982**;57:685-689