

Increased Density of the Thalamus on CT Scans in Patients with GM₂ Gangliosidoses

Jan Brismar¹
 Gudrun Brismar²
 Robert Coates¹
 Generoso Gascon³
 Pinar Ozand³

In 13 patients, the GM₂ gangliosidoses, Sandhoff disease and Tay-Sachs disease, were found to be constantly associated with homogeneously and symmetrically increased CT attenuation within the thalami. In the only patient examined with MR imaging, a T2-weighted sequence showed hypointense thalami. It is suggested that this finding is caused by an accumulation of calcium, associated with the intracellular storage of GM₂ ganglioside.

The finding of dense thalami may be useful as a specific diagnostic criterion for GM₂ gangliosidoses. In a few patients with blocks in adjacent steps in the sphingolipid metabolism, this finding was not present.

AJNR 11:125-130, January/February 1990

The GM₂ gangliosidoses are rare disorders of the sphingolipid metabolism in which a hexosaminidase defect causes a metabolic block leading to an abnormal accumulation of GM₂ ganglioside in brain tissue. The most common GM₂ disorder, Tay-Sachs disease [1], has a pronounced predilection for Ashkenazy Jews. A rarer GM₂ disorder, Sandhoff disease [2], of which a total of less than 100 cases has been reported, shows no racial preference. Both these disorders belong to the group of amaurotic idiocies and are autosomal recessively inherited. Though genetically different, they are phenotypically indistinguishable.

The affected child appears normal during the first half year of life, then developmental arrest is followed by regression, decerebrate rigidity, blindness, a "cherry red spot" in the macula, and a characteristic myoclonic arousal reaction to sound. The child usually dies before the age of 3 years.

The GM₂ gangliosidoses, especially Sandhoff disease, are not extremely rare in Saudi Arabia. During the last 3 years we have personally seen 13 cases of GM₂ gangliosidosis. Twelve were verified as Sandoff disease. These 13 cases form the basis for this report.

Biochemical Background [3-5]

The degradation of the ganglioside GM₂ to GM₃ is dependent on the enzyme lysosomal *N*-acetyl hexosaminidase, which consists of three isoenzymes, two major (A and B) and one minor (S). These isoenzymes are composed of two different polypeptide chains (alpha and beta) with gene locus on chromosomes 15 and 5, respectively. While isoenzyme A is composed of both alpha and beta chains, isoenzymes B and S consist exclusively of chains beta and alpha, respectively. A defect in the alpha locus thus causes a deficiency of both A and S isoenzymes (Tay-Sachs disease) while in a patient with a mutation in the beta locus, only the isoenzyme S is operable (Sandhoff disease). The total hexosaminidase activity is preserved in Tay-Sachs disease, but within the brain the isoenzyme B is unable to hydrolyze GM₂ ganglioside, which therefore accumulates. In Sandhoff disease the

Received February 7, 1989; revision requested April 27, 1989; revision received June 22, 1989; accepted July 3, 1989.

¹ Department of Diagnostic Radiology, King Faisal Specialist Hospital & Research Centre, P.O. Box 3354, Riyadh 11211, Saudi Arabia. Address reprint requests to J. Brismar.

² Department of Surgery, Section of Ophthalmology, King Faisal Specialist Hospital & Research Centre, Riyadh 11211, Saudi Arabia.

³ Department of Pediatrics, King Faisal Specialist Hospital & Research Centre, Riyadh 11211, Saudi Arabia.

0195-6108/90/1101-0125
 © American Society of Neuroradiology

total hexosaminidase activity is reduced to less than 2–3%; in this condition, in addition to the accumulation of GM₂ gangliosides in the brain, globoside is also stored in the liver, spleen, and kidneys, which may be enlarged. The GM₂ ganglioside accumulates within the cytoplasm of the neurons of the cerebral cortex, the neuronal cell body is distended, and the nucleus displaced. Later extensive neural cell loss and white matter degeneration with storage of lipid breakdown products leads to brain atrophy.

Materials and Methods

The King Faisal Specialist Hospital & Research Centre is the principal tertiary referral center for the entire Kingdom of Saudi Arabia and the only institution within the Kingdom with resources for the advanced biochemical analysis that can distinguish between different genetic metabolic disorders. Between June 1986 and December 1988, 13 patients, all less than 2 years old, were biochemically diagnosed as having GM₂ gangliosidosis, 12 of these were Sandhoff disease (10 typical and two with heat-labile beta chain mutations, cases 11 and 12) and one was Tay-Sachs disease with a heat-stable mutation in the alpha locus (case 13). The clinical, ophthalmologic, and biochemical findings and the genetic work-up will be detailed in separate reports; relevant clinical data are summarized in Table 1.

Known similar disorders in the family, consanguinity between the parents, and possible organomegaly were evaluated from the charts and are listed as Yes or No. The developmental disturbance was staged as mild-moderate (+), severe (++) , or very severe (+++). The presence or absence of blindness or a "cherry red spot" was evaluated by an experienced ophthalmologist. All 13 patients were examined with CT (GE 9800, Siemens Somatom or Picker 1200 SX) with 8- or 10-mm-thick contiguous sections. In two patients the examination was also performed after administration of IV contrast medium

(Ultravist, 300 mg/ml, 2 ml per kg body weight). The CT findings of atrophy, white matter disease, and increased attenuation within the thalamus were subjectively graded as 0 or + (mild), ++ (moderate), or +++ (marked).

For those nine cases in whom the CT pictures were stored on magnetic tape (cases 2, 4, 5, and 13 were not stored), attenuation values were obtained for a 1-cm-sized region of interest from each thalamus and putamen. The thalamic-putaminal attenuation difference was then calculated for each patient as the difference in Hounsfield units (H) between the mean thalamic and putaminal densities. One patient was also examined with MR imaging (Picker Vista, 1.5 T) with a T2-weighted dual echo sequence (2000/40,80) and 7-mm consecutive slices.

Results and Discussion

The results of the CT examinations are summarized in Table 1. In all 13 patients the thalamus showed increased attenuation (Figs. 1–4). In five cases the thalamic hyperdensity was classified as (+++) (Figs. 1C and 3B), in five patients as (++) (Figs. 1B, 1D, 2, and 4A), and in three infants as (+) (Fig. 1A).

The measured mean thalamic-putaminal attenuation difference ranged from 3.3 to 8.3 H. The measured values correlated well with the subjective thalamic hyperdensity grading—in cases graded as (+) the difference ranged from 3.4–3.8, in cases classified as (++) from 4.1–5.7, and in (+++) patients from 5.6–8.3.

The hyperdensity in all cases was homogeneous and symmetric and limited to the thalamus. Discrete calcifications were seen neither in the thalamus nor elsewhere in the brain. CT scans after IV contrast medium, obtained in two patients, showed no sign of abnormal enhancement (Fig. 2).

TABLE 1: Findings in 13 Patients with Verified GM₂ Gangliosidosis

Case No.	Clinical History					Clinical Examination				CT Findings		
	Age (mo.)	Sex	Age at Onset (mo.)	Family History	Consanguineous	"Cherry Red Spot"	Blind	Organomegaly	Develop. Disturb.	White Matter Disease	Atrophy	Thalamic Hyperdensity
1	14	M	3	Yes	?	Yes	Yes	–	++	++	0	+
2	13	M	5	Yes (cousins)	Yes	Yes	Yes	–	+++	++	0	++
3	19	M	7	No	Yes	Yes	Yes	Hepatomegaly	+++	++	0	+++
4	8	F	4	Yes	Yes	Yes	No	Hepatomegaly	+	0	+	+
5	16	M	4	Yes (cousins)	Yes	Yes	Yes	–	++	0	+	+++
6	18	F	12	Yes	Yes	Yes	Yes	–	+++	++	0	++
7	23	M	6	Yes (brothers)	Yes	Yes	Yes	–	+++	+++	+	++
8	9	M	^a	Yes (brothers)	Yes	Yes	No	–	+	0	++	+
9	18	F	Birth (6?)	Yes	No	Yes	Yes	–	++	+++	0	++
10	13	M	5	No	Yes	Yes	Yes	Hepatomegaly	++	+	+	+++
11 ^b	12	F	7	No	Yes	Yes	? Light perception	?	+++	0	0	+++
12 ^b	3	F	Birth	Yes	Yes	No ^c	Yes?	–	++	0	+++	++
13 ^d	23	M	9	No	Yes	Yes	Yes	–	++	++	0	+++

Note.—Developmental disturbance is graded as slight-moderate (+), severe (++) , and very severe (+++); CT findings of white matter disease, atrophy, and thalamic hyperdensity are graded as absent (0), slight (+), moderate (++) , or marked (+++).

^a Developmental disturbance not noticed by parents.

^b Heat-labile beta chain mutation.

^c Too early to assess.

^d Thermostable alpha chain mutation (Tay-Sachs disease).

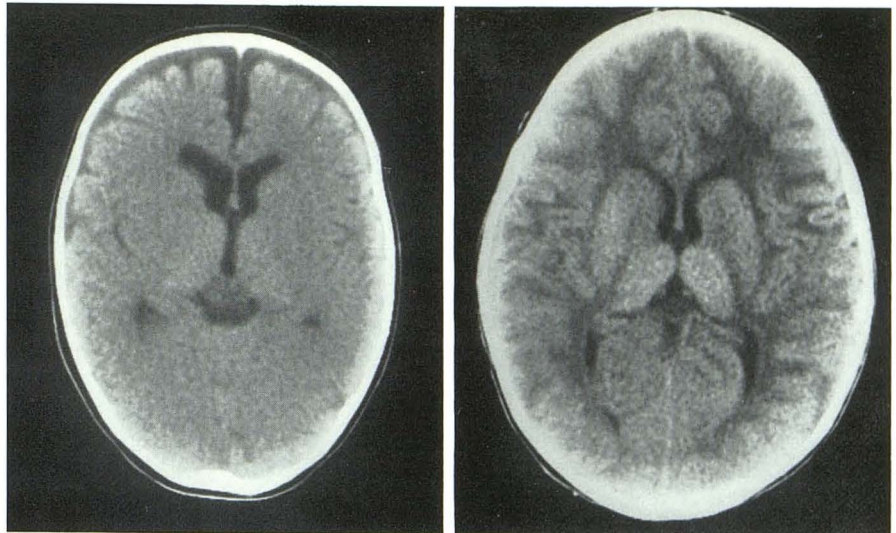
Fig. 1.—Four patients with Sandhoff disease and various combinations of white matter disease, atrophy, and thalamic hyperdensity.

A, Case 8. No white matter disease, atrophy (++) , and thalamic hyperdensity (+).

B, Case 9. White matter disease (+++) , no atrophy, and thalamic hyperdensity (++) .

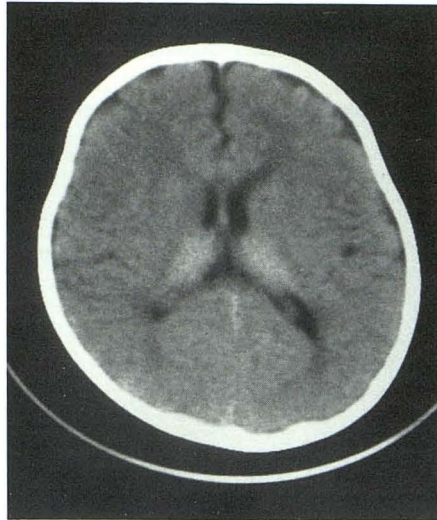
C, Case 10. White matter disease (+) , atrophy (+) , and thalamic hyperdensity (+++) .

D, Case 12. No white matter disease, atrophy (+++) , and thalamic hyperdensity (++) .

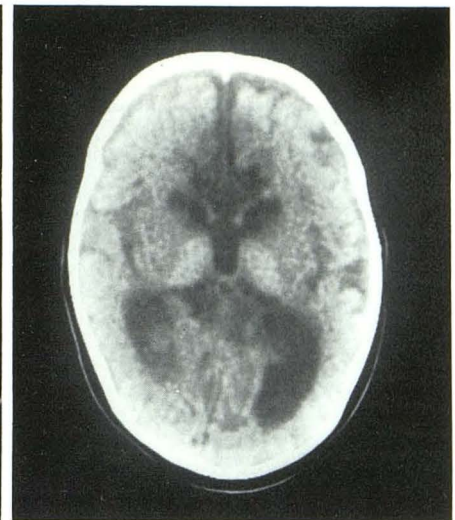


A

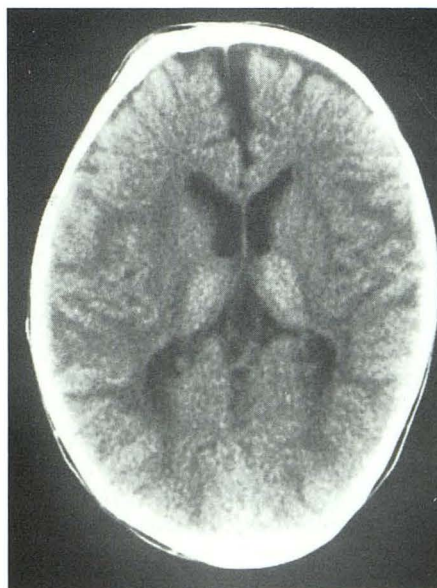B



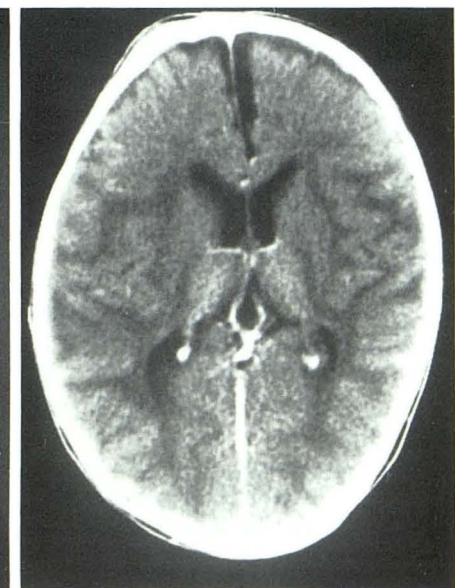C



D



A



B

Fig. 2.—23-month-old boy with Sandhoff disease (case 7).

A, Nonenhanced CT scan shows white matter disease (+++) , atrophy (+) , and thalamic hyperdensity (++) .

B, No change in appearance after contrast medium.

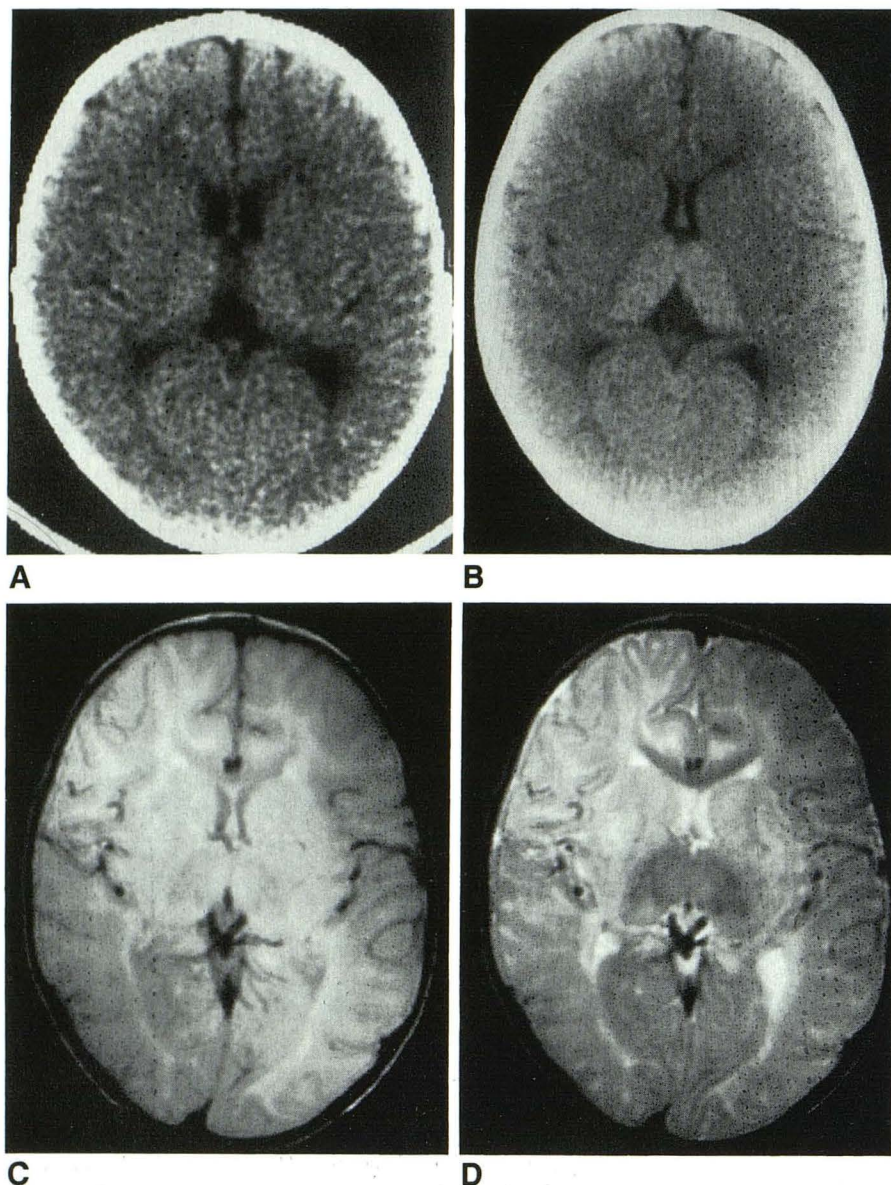


Fig. 3.—12-month-old girl with Sandhoff disease (case 11).

A, Outside CT scan at age 10 months shows thalamic hyperdensity only (+).

B, Repeat CT scan 2 months later shows thalamic hyperdensity increase to (+++), still no atrophy or white matter disease.

C and D, MR images at 1.5 T, 2000/40 (C) and 2000/80 (D), show hypointense thalami and also white matter disease along occipital horns, not obvious from CT scan. (Difference in intensity between frontal lobes is caused by head coil asymmetry.)

White matter disease and atrophy were found by CT in eight and six cases, respectively. No obvious correlation was found between the degree of thalamic hyperdensity and the presence or severity of white matter disease or atrophy (Fig. 1). The most pronounced atrophy was thus seen in two patients with only (+) and (++) thalamic hyperdensity (Fig. 1D) while four patients without any atrophy showed (+++) thalamic hyperdensity (Figs. 1B and 4A). The most severe white matter disease was also seen in patients with only moderate thalamic hyperdensity (Figs. 1B and 2). Our results suggest an inverse relation between atrophy and white matter disease; only two patients showed both signs, while in 10 patients only one of the findings was present. The white matter disease seemed to be related to the patient's age, and was seen on CT only after 12 months of age. In contrast, the most pronounced atrophy was seen in the youngest patient (Fig. 1D). This is in contrast to previous studies that found

atrophy as an end result when enough brain cells have been destroyed by cortical degeneration and by leukodystrophy. Perhaps swelling associated with the white matter changes masks the atrophic changes. One patient with (+++) thalamic hyperdensity showed neither white matter disease nor atrophy (Fig. 3B).

The thalamic hyperdensity seemed to be more severe in the older patients, and, in the only patient that was examined twice, there was progression between the two examinations (Figs. 3A and 3B). No correlation was found between the severity of the developmental disturbance and white matter disease, atrophy, or thalamic hyperdensity.

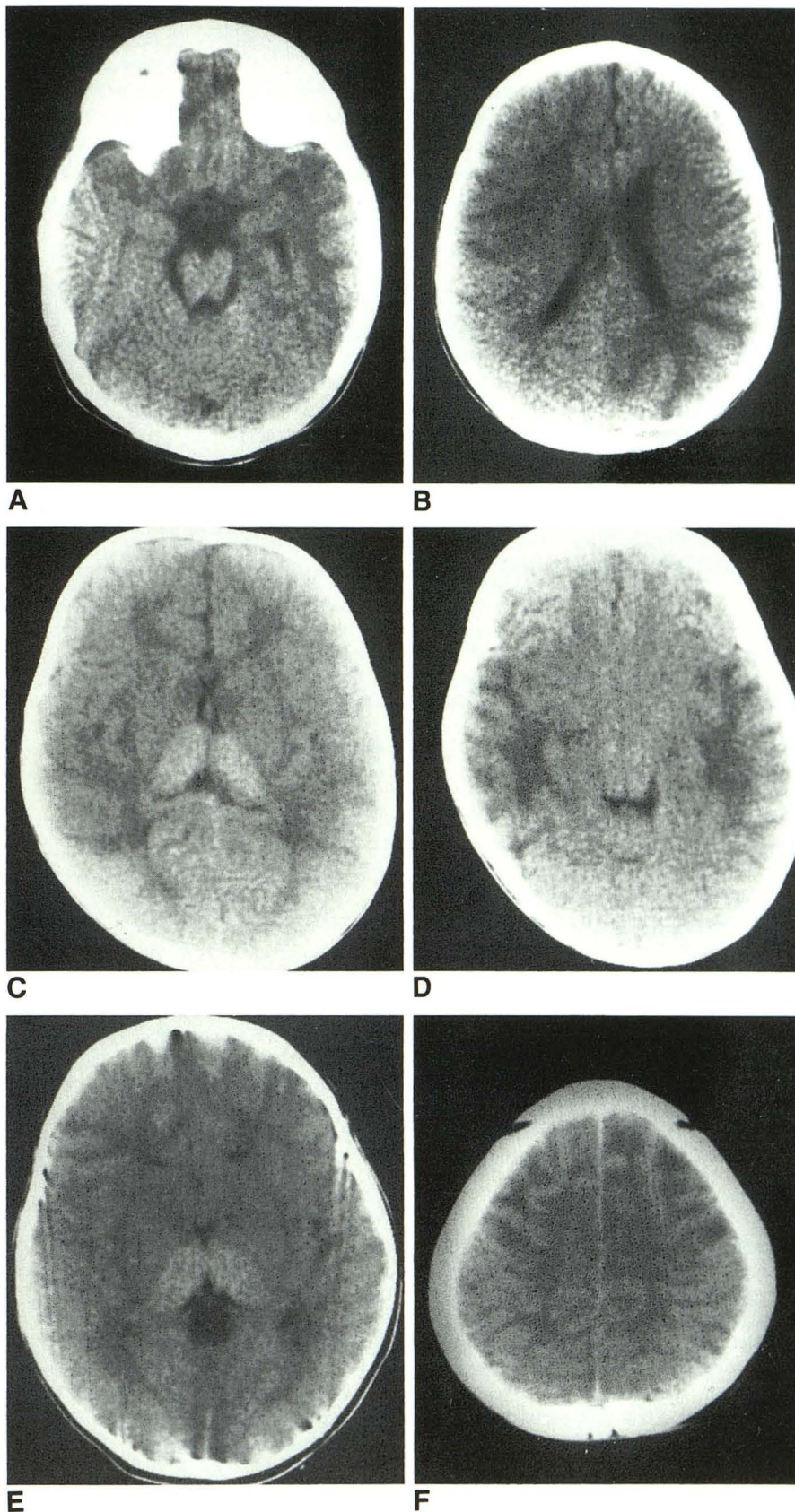
It is well known that MR imaging is more sensitive than CT in demonstrating white matter disease. The only patient who had an MR examination illustrates this. While CT showed no signs of white matter disease, mild changes of white matter disease were present on the MR examination (Figs. 3C and

Fig. 4.—Three patients with white matter disease (++) . In all three there is asymmetric and/or uneven distribution of white matter disease.

A and B, White matter disease is most pronounced in right frontal and left frontoparietal regions (case 6).

C and D, White matter disease is most marked within temporoparietal regions (case 3).

E and F, Mainly frontal white matter disease (case 13).



3D). MR imaging in this patient showed the thalami as hypointense structures in both proton-density- and T2-weighted sequences.

The thalamic hyperdensity has, to the best of our knowledge, not previously been reported either in association with GM₂ gangliosidosis or in other disorders. Furthermore, in our experience thalamic hyperdensity seems to be specific for the GM₂ gangliosidosis. We have had the opportunity to examine patients with disturbances in adjacent steps in the sphingolipid metabolism, all with "cherry red spots" in the macula: one patient with a GM₁ gangliosidosis (accumulation of GM₁ ganglioside, amaurotic idiocy), one with a combined GM₁ gangliosidosis and neuroaminidase deficiency, and two patients with Niemann-Pick disease type B with accumulation of sphingomyelin in the brain. All these patients had normal-appearing thalami on CT examination.

No explanation for the thalamic hyperdensity is available from reports on autopsy findings in GM₂ gangliosidosis. Both the CT and the MR findings are consistent with calcium deposition within the thalamus. The GM₂ ganglioside is associated with the calcium metabolism in the brain [6], which could explain the relation between thalamic hyperdensity and

GM₂ gangliosidosis. Autopsy studies of the brain in patients succumbing to GM₂ gangliosidosis, with special reference to histochemical analyses of the calcium content in different parts of the brain in relation to the ganglioside content, would probably throw further light on this tragic disease. However, because of moral tradition, autopsies are not performed in Saudi Arabia, and we will therefore not be able to perform such studies ourselves.

REFERENCES

1. Okada S, O'Brien JS. Tay-Sachs disease: generalized absence of β -D-N-acetylhexosaminidase component. *Science* **1969**;165:698-700
2. Sandhoff K, Harzer K, Wassel W, Jatzkewitz H. Enzyme alterations and lipid storage in three variants of Tay-Sachs disease. *J Neurochem* **1971**;18:2469-2489
3. Sandhoff K, Conzelmann E. The biochemical basis of gangliosidosis. *Neuropediatrics* **1984**;15[Suppl]:85-92
4. Goebel HH. Morphology of the gangliosidosis. *Neuropediatrics* **1984**;15[Suppl]:97-106
5. Schulte FJ. Clinical course of GM₂ gangliosidosis. A correlative attempt. *Neuropediatrics* **1984**;15[Suppl]:66-70
6. Quarles R, Folch-Pi J. Some effects of physiological cations on the behaviour of gangliosides in a chloroform-methanol-water biphasic system. *J Neurochem* **1965**;12:543-553