



## ASNR Career Center

The Go-To Job Site for Neuroradiology Employers and Job Seekers  
Start here: [careers.asnr.org](http://careers.asnr.org)

# AJNR

### **Lumbar disk degeneration in spinal dysraphism.**

H M de Bakker, R A Roos, J H Voormolen and G J Vielvoye

*AJNR Am J Neuroradiol* 1990, 11 (2) 415

<http://www.ajnr.org/content/11/2/415.citation>

This information is current as  
of September 30, 2023.

## Lumbar Disk Degeneration in Spinal Dysraphism

MR is a valuable method for imaging the spine and spinal cord in cases of spinal dysraphism. We reviewed MR images for evidence of disk degeneration in 22 patients younger than 20 years old who had spinal dysraphism.

### Results

Eight of the 22 patients had spina bifida aperta, and 14 had spina bifida occulta. These included eight cases with repaired myelomeningocele, seven with an intraspinal lipoma and tethering of cord, three with dermal sinuses, and one with diastematomyelia. Bulging and low signal intensity of the nucleus pulposus on T2-weighted images are the criteria for disk degeneration [1, 2]. In our study, 12 patients (54.5%), eight with spina bifida occulta and four with spina bifida aperta, had signs of disk degeneration in 17 disks. Twelve of these disks were present in the patients with spina bifida occulta, and five were present in those with spina bifida aperta. In nine disks, the most remarkable sign was the low signal on T2-weighted images. In seven of the 17 disks, however, bulging was the most striking phenomenon. The distribution of the 17 degenerated disks was as follows: three at the L3–L4 level, seven at the L4–L5 level, and seven at the L5–S1 level (Figs. 1 and 2).

### Discussion

The signal intensity in T2-weighted images is lower in the nucleus pulposus of a degenerated disk than in the normal nucleus pulposus, because of disk dehydration, and a degenerated segment of the disk can be seen bulging into the subarachnoid space [1, 2]. In five (25%) of 20 patients, up to 35 years old, Modic et al. [3] found asymptomatic degenerative disk disease in six disks, five at the L5–S1 level and one at the L4–L5 level. In our patients, all younger than 20 years old and all with spinal dysraphism, we found early disk degeneration in 17 disks in 12 of 22 patients. This is three times more than reported

by Modic et al. in a series of relatively younger patients. The reason for this remarkably high prevalence is not known. We found no relation between the level of the conus or neural deficit and the prevalence of disk degeneration. Several theoretical explanations can be posed. Most patients with spinal dysraphism have a disturbed gait because of neurologic and orthopedic disturbances in function. This can cause an abnormal load on the spinal column, leading to disk degeneration at an early age, especially when scoliosis is present also. Another possible explanation is an embryologic one. In spinal dysraphism, the embryonic notochord, which induces the development of the neural canal, should be abnormal [4, 5]. The nucleus pulposus is a remnant of the embryonic notochord, and the possible abnormal notochord in spinal dysraphism may result in an insufficient nucleus pulposus, a condition that predisposes to early disk degeneration. Of course, a combination of both theories is also possible.

H. M. de Bakker  
R. A. C. Roos  
J. H. C. Voormolen  
G. J. Vielvoye  
University Hospital Leiden  
2300 RC Leiden, The Netherlands

### REFERENCES

- Gibson MJ, Buckley J, Mawhinney R, Mulholland RC, Worthington BS. Magnetic resonance imaging and discography in the diagnosis of disc degeneration. *J Bone Joint Surg* 1986;68:369–373
- Schneiderman G, Flannigan B, Kingston S, Thoman J, Dillin WH, Watkins RG. Magnetic resonance imaging in the diagnosis of disc degeneration: correlation with discography. *Spine* 1987;12:276–281
- Modic MT, Pavlicek W, Weinstein MA, et al. Magnetic resonance imaging of intervertebral disc disease: clinical and pulse sequence considerations. *Radiology* 1984;152:103–111
- Giroud A, Lelièvre A. *Éléments d'embryologie*, 6th ed. Paris: Librairie E le Francis, 1962
- Hamersma K. Anencephalie en spina bifida [Dissertation]. Romijn. Apeldoorn: University of Leiden, 1966

Fig. 1.—A and B, Sagittal T1-weighted (A) and T2-weighted (B) MR images of a 14-year-old girl show tethering of cord and dermal sinus (arrow). Bulging annuli and low signal intensities at L3–L4 and L4–L5 levels are signs of disk degeneration.

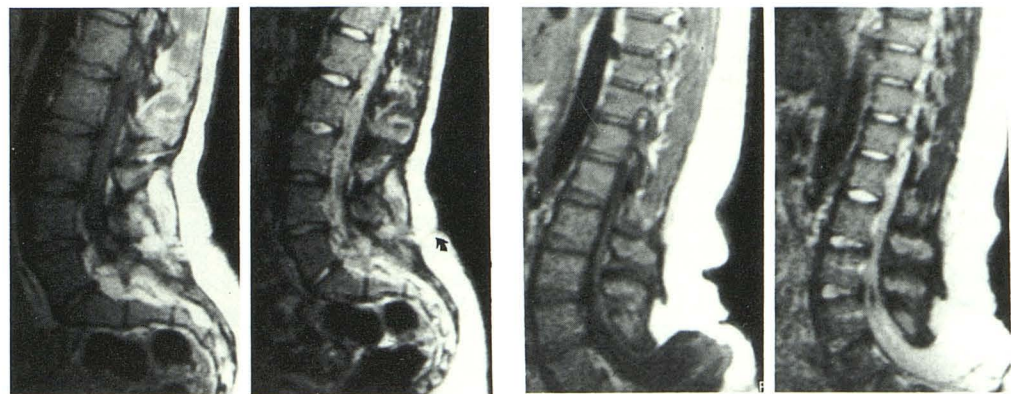


Fig. 2.—A and B, Sagittal T1-weighted (A) and T2-weighted (B) MR images of a 20-year-old man show a repaired lipomyelomeningocele in lumbosacral region. B shows low signal intensity of nucleus pulposus at L3–L4, L4–L5, and L5–S1 levels.

