

Are your **MRI contrast agents** cost-effective?

Learn more about generic **Gadolinium-Based Contrast Agents**.



FRESENIUS
KABI

caring for life

AJNR

Unilateral megalencephaly: correlation of MR imaging and pathologic characteristics.

A J Barkovich and S H Chuang

AJNR Am J Neuroradiol 1990, 11 (3) 523-531

<http://www.ajnr.org/content/11/3/523>

This information is current as
of April 19, 2024.

Unilateral Megalencephaly: Correlation of MR Imaging and Pathologic Characteristics

A. James Barkovich¹
Sylvester H. Chuang²

Unilateral megalencephaly is a rare and poorly understood malformation resulting in the enlargement of all or part of a cerebral hemisphere. The clinical and radiologic features of 12 patients with unilateral megalencephaly are presented; pathologic correlation was available in four. All patients had seizures and developmental delay. Two were in congestive heart failure as a result of arteriovenous shunting through the abnormal hemisphere. The affected hemispheres showed a wide spectrum of involvement. Anomalies of neuronal migration were present, and there was a roughly inverse correlation between the severity of hemispheric involvement and the magnitude of enlargement. This correlation is explained via a proposed mechanism of a mild hemispheric insult in the middle-to-late second trimester. One patient had an extremely anomalous hemisphere that did not have characteristics of a neuronal migration anomaly and may have been a hamartomatous malformation.

Our correlation of the clinical, radiologic, and pathologic features of unilateral megalencephaly, together with a theory of pathogenesis, should help elucidate this rare malformation.

AJNR 11:523-531, May/June 1990

Unilateral megalencephaly is a rare anomaly of the brain in which all or part of one hemisphere is enlarged in the absence of somatic hemihypertrophy [1-8]. We recently reviewed the imaging studies of 12 patients with this anomaly; histologic material was available in four of these. In this report, we describe the clinical, radiologic, and pathologic features of this anomaly and relate the pathologic anatomy to a proposed theory of pathogenesis.

Materials and Methods

The 12 patients included eight males and four females who were 3 days to 41 years of age at the time of imaging (mean, 8.9 years) (see Table 1). Four patients were initially studied as a result of large head size; the other eight were studied to find the cause of an intractable seizure disorder. All patients had intractable seizures, hemiparesis (contralateral to the affected hemisphere), and delayed development. Two patients were in congestive heart failure at the time of presentation. The two adult patients were moderately to severely mentally retarded. Two patients (cases 5 and 9) have been reported previously [9].

CT scans were obtained before and after the administration of iodinated contrast material in seven patients. Axial images were obtained using a 10-mm slice thickness.

MR examinations were performed in nine patients. Two were imaged at 0.35 T, two at 0.5 T, and five at 1.5 T. Imaging parameters included a 256 × 128, 192, or 256 imaging matrix; 20-cm field of view; and 5- to 7-mm section thickness (interslice gap, 1-3 mm). Sagittal spin-echo (SE) 500-800/20-40/2 (TR/TE/excitations) images were obtained in seven of the nine patients. Coronal SE 600/20 images were obtained in four patients and axial SE 600/20 images were obtained in one. Axial SE 2000-3000/30-40, 70-100 images were obtained in all nine patients.

Angiograms of both internal carotid and vertebral artery circulations were obtained in cases 2, 3, and 11 using standard techniques.

Received August 14, 1989; revision requested September 28, 1989; revision received November 1, 1989; accepted November 16, 1989.

The views expressed in this article are those of the authors and do not reflect the official policy or position of the Department of the Army, the Department of Defense, or the United States Government.

Presented in part at the annual meeting of the American Society of Neuroradiology, Orlando, FL, March 1989.

¹ Department of Radiology, Section of Neuroradiology, L-371, University of California School of Medicine, 505 Parnassus Ave., San Francisco, CA 94143; and Letterman Army Medical Center, Presidio of San Francisco, CA 94129-6700. Address reprint requests in care of Medical Editing HSHH-C1-ME, Department of Clinical Investigation, Letterman Army Medical Center, Presidio of San Francisco, CA 94129-6700.

² Department of Radiology, The Hospital for Sick Children, Toronto, Ontario M5G 1X8, Canada.

0195-6108/90/1103-0523

© American Society of Neuroradiology

TABLE 1: Clinical Characteristics of 12 Patients with Unilateral Megalencephaly

Case No.	Age	Degree of Enlargement; Area Enlarged	Ventricle	Gyrals Pattern	White Matter	Heterotopias	Comments	Studies
1	3 d	Marked; L hemisphere (frontal lobe spared)	All enlarged	Bizarre pachygyria	Diminished; no gliosis	None	Reverse myelin pattern	MR
2	9 d	Mild; R hemisphere (frontal + occipital spared)	Body/atrium enlarged; SFH	Agyria	Diminished; no gliosis	None	Calcified cortex; congestive heart failure	CT, MR
3	10 d	Marked; R hemisphere	Body/atrium enlarged; SFH	PMG	Increased; low attenuation	None	Congestive heart failure	CT, pathology
4	12 d	Marked; L hemisphere	Body/atrium/occipital horn enlarged; SFH	PMG	Increased; low attenuation	Periventricular	—	CT
5	2 y	Moderate; L hemisphere	Body/atrium enlarged; SFH	Agyria	Diminished; ↑T1, ↑T2	Bands in centrum semiovale	Marked gliosis	MR
6	3 y	Marked; L hemisphere	Body/atrium/occipital horn enlarged; SFH	PMG	Increased; low attenuation	Periventricular	—	CT
7	3 y	Moderate; R frontal/parietal	Body enlarged; SFH	PMG	Increased; low attenuation; ↑T2	Only seen on pathology	Localized	CT, MR, pathology
8	6 y	Marked; L hemisphere	Body/atrium enlarged; SFH	PMG	Increased; minimal gliosis	None	—	MR, pathology
9	8 y	Moderate; L hemisphere	Small; SFH	PMG	Increased; moderate gliosis	Scattered	—	CT, MR
10	10 y	Moderate; R temporal/occipital	Large atrium/occipital horn	PMG	Increased; gliosis	None	Localized	MR, pathology
11	33 y	Moderate; L hemisphere	Body/atrium enlarged; SFH	PMG	Increased; gliosis	Mid-centrum semiovale	—	MR
12	41 y	Moderate; R temporal/parietal/occipital	Atrium enlarged	PMG	Increased; gliosis	None	Localized	CT, MR

Note.—d = days; y = years; L = left; R = right; SFH = straight frontal horn; PMG = polymicrogyria; ↑ = prolonged.

Images were assessed for degree of hemispheric enlargement, ventricular shape and size, gyral pattern, state of myelination of the white matter, signal abnormalities (focal or diffuse) of white and gray matter, and (on CT) calcification. When abnormalities were present, they were judged as focal or diffuse, and, if focal, the affected region of the brain was recorded. Enlargement was considered mild if the width of the enlarged area of brain was between 1 and 1.25 times the size of the same region of the contralateral (normal) hemisphere, moderate if the enlargement was 1.25 to 1.5 times the size of the normal hemisphere, and severe if the affected brain was greater than 1.5 times the size of the corresponding normal hemisphere.

Pathologic examination was performed on the tissue after fixation in 10% or 20% formalin for varying periods of time. Representative tissue samples were embedded in paraffin and stained with H and E, cresyl violet, phosphotungstic acid-hematoxylin, or Holzer method for glia; Bodian method for neurofibrils; and Luxol fast blue or Weil methods for myelin.

Results

Imaging Studies

Enlargement of at least one lobe of a cerebral hemisphere was present in all patients in this study; the right hemisphere was involved in five patients and the left hemisphere in seven patients. The involved portion of the brain was mildly enlarged in one patient, moderately enlarged in six patients, and severely enlarged in five patients. The entire hemisphere was enlarged in seven patients, all but the inferior frontal lobe in one patient, and all but the frontal and occipital poles in one. Involvement was limited to the posterior temporal/parietal/occipital region in two, and enlargement was limited to the frontal lobe in one patient.

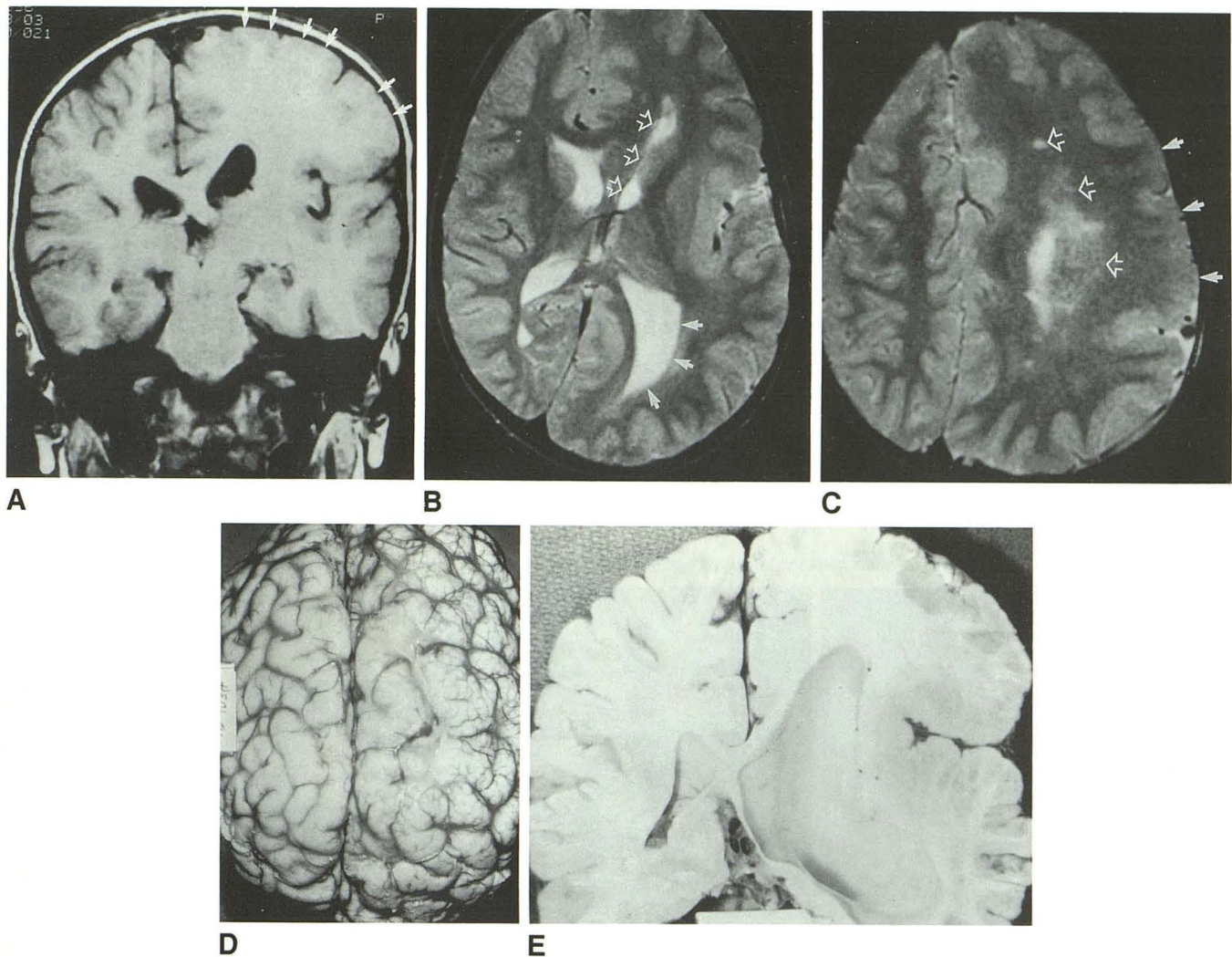


Fig. 1.—Case 8.

A, Coronal SE 800/20 MR image shows marked enlargement of left hemisphere at level of posterior bodies of lateral ventricles. There is a considerable increase in amount of white matter; cortex shows broad, flat gyri (arrows). Individual microgyri could not be resolved in this patient.

B, Axial SE 2800/80 MR image. Straightening of left frontal horn (open arrows) is characteristic of unilateral megalencephaly, as is enlargement of atrium of ventricle (solid arrows).

C, Axial SE 2800/80 MR image through centrum semiovale shows marked left hemispheric enlargement, abnormal gyral pattern (solid arrows), and small areas of prolonged T2 relaxation in periventricular region (open arrows). Mild white-matter abnormalities in conjunction with polymicrogyria were associated with marked hemispheric enlargement.

D, Gross anatomic specimen shows enlarged left hemisphere with diffuse polymicrogyria.

E, Cut section through trigones of lateral ventricle shows marked enlargement of left lateral ventricle and diffusely increased white matter. Note that individual microgyri are difficult to resolve in cut section.

In 11 of the 12 patients, the cortical gray matter in the affected brain showed an anomaly of neuronal migration. In nine of these patients the hemisphere was moderately to severely enlarged. The cortex was slightly thickened, the gyri were broad and flat, and the sulci were shallow (Fig. 1). The four patients with this radiologic pattern who were biopsied had a histologic diagnosis of polymicrogyria; the pattern will be hereafter referred to as a polymicrogyric pattern. Two of the 11 patients had an essentially agyric hemisphere; the hemisphere was mildly enlarged in case 2 (Fig. 2) and moderately enlarged in case 5.

The hemispheric white matter was abnormal on both CT and MR in all patients. In the two patients who had agyric hemispheres, hemispheric white-matter content was diminished or mildly increased (Fig. 2). In all others, there was a significant increase in the amount of hemispheric white matter (Figs. 1 and 3). Moreover, the white matter in the affected portion of the hemisphere was hypodense (compared with the normal hemisphere) on CT and had prolonged T2 relaxation time on MR (Fig. 4) in all but two patients. The area of hypoattenuation on CT was always equal to or larger than the abnormal area seen on MR in those patients who had

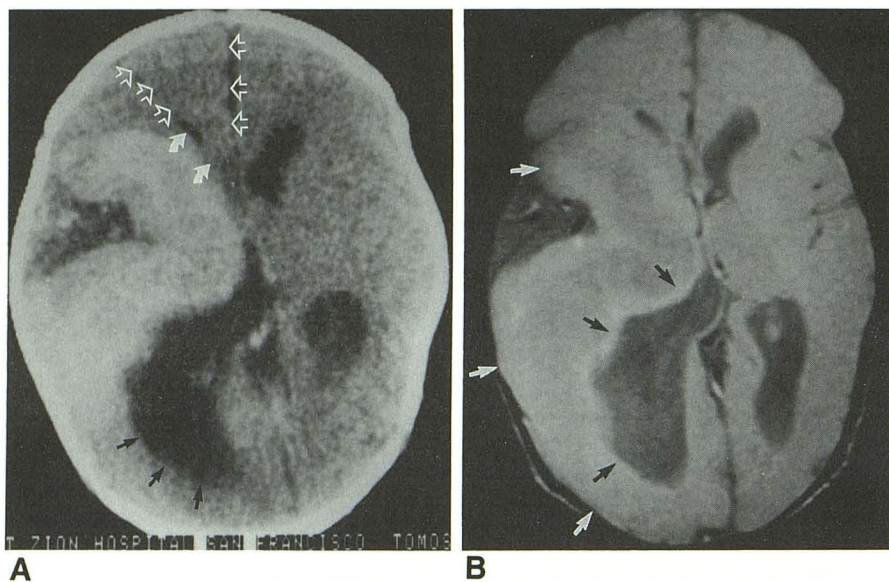


Fig. 2.—Case 2.

A, Unenhanced CT scan shows essentially agyric right cerebral hemisphere. Rostral aspect of right frontal lobe is not involved (*open arrows*). Trigone of ipsilateral ventricle is enlarged (*black arrows*) and ipsilateral frontal horn is straightened (*curved arrows*).

B, Axial SE 2800/30 MR image confirms agyric segment of right hemisphere with thickened cortex (*white arrows*) and small area of white matter (*black arrows*) surrounding ventricle.

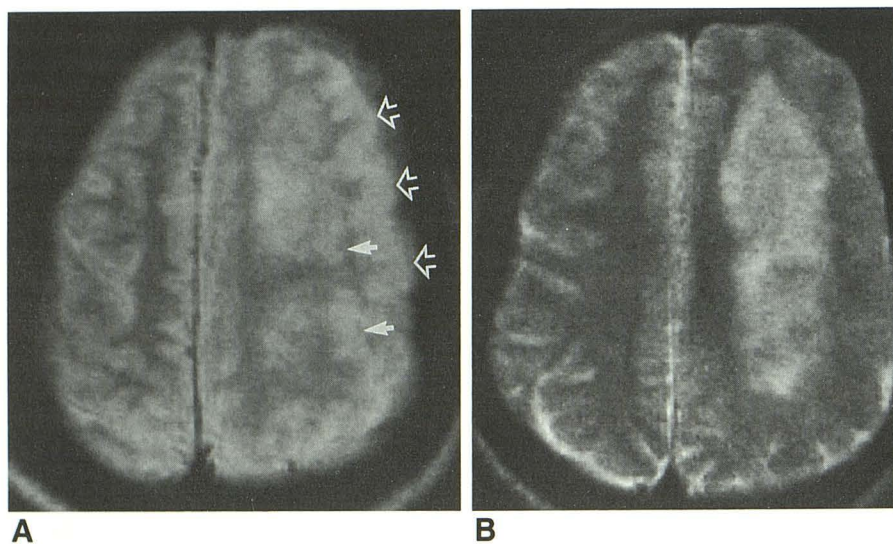


Fig. 3.—Case 11.

A, Axial SE 3000/35 MR image shows enlargement of left hemisphere with abnormal gyral pattern (*open arrows*) and heterotopias in underlying white matter (*solid arrows*).

B, Axial SE 3000/100 MR image 1 cm caudal to A shows that abnormal tissue in centrum semiovale has slightly longer T2 relaxation time than cortical gray matter. This indicates some degree of destructive process, with a glial reaction that has destroyed normal structures of centrum semiovale.

both studies (Fig. 4). There seemed to be an inverse correlation between the severity of the white-matter damage and the size of the hemisphere; those patients with minimal prolongation of white-matter T2 had markedly enlarged hemispheres (Figs. 1 and 5), whereas those with marked T2 prolongation had minimal or moderate hemispheric enlargement (Fig. 3).

Nodular regions isointense relative to cortical gray matter, most likely heterotopias, were present in the hemispheric white matter in six patients. In three patients who had both CT and MR, the nodules were detected by MR but not by CT (Fig. 5).

The ipsilateral lateral ventricle was enlarged in 10 of the 11 patients with anomalies of neuronal migration in the affected cortex. In the single patient in whom the ventricle was normal to diminished in size (case 9), the ventricle seemed to be compressed by a layer of soft tissue that was isointense relative to white matter on short TR/TE images (Fig. 5) and

hyperintense relative to gray matter on long TR/TE images. The nature of this tissue has not been identified. One patient (case 10) had a similar subependymal layer of tissue but had ventricular enlargement nonetheless.

Amorphous calcification was present in the agyric cortex in case 2 (Fig. 2). No calcification was present in the affected hemispheres in the other patients in this study.

The affected hemisphere in case 1 was tremendously enlarged and had a bizarre, multilobulated gyral pattern with a huge, lobulated lateral ventricle (Fig. 6). The affected hemisphere had a relative paucity of white matter as compared with gray matter, in contradistinction to most patients, in whom the amount of hemispheric white matter was greatly increased. Furthermore, the intensity pattern of gray and white matter in this neonate was reversed from the normal newborn intensity pattern [10] in that the white matter was hyperintense with respect to gray matter on short TR/TE images and hypointense on long TR/TE images. The affected

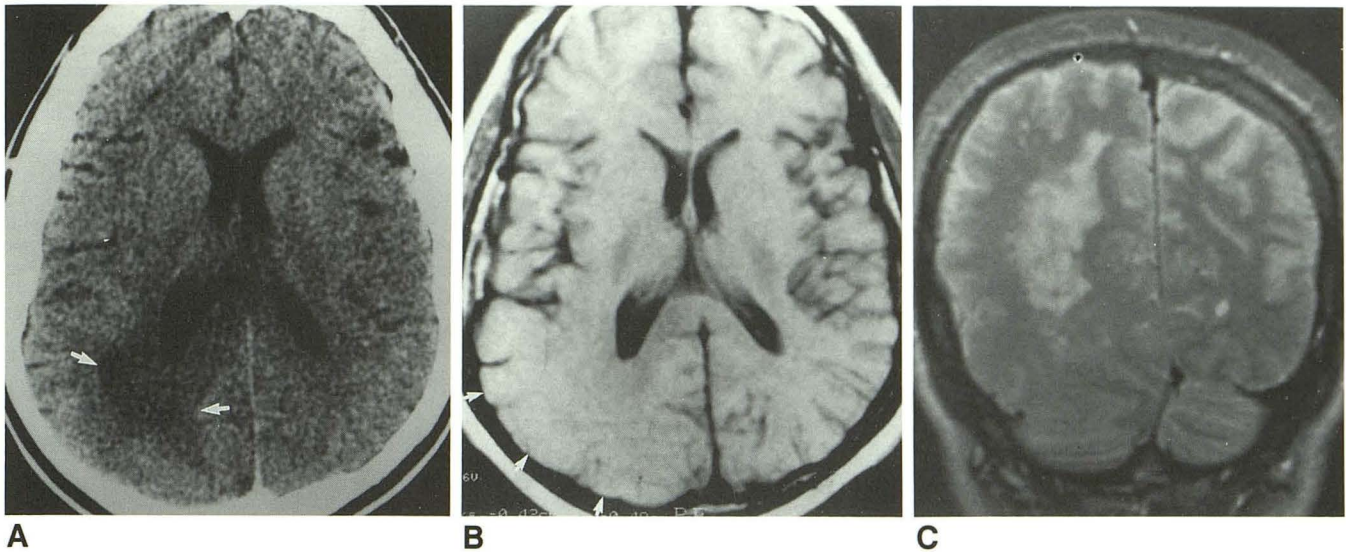


Fig. 4.—Case 12.

A, Axial unenhanced CT scan shows low attenuation in right occipital white matter (arrows). Increased white matter also occurs in this region, compared with contralateral side, along with enlargement of atrium of ipsilateral ventricle.

B, Axial SE 600/25 MR image shows enlargement and abnormal gyral pattern in right occipital lobe (arrows).

C, Coronal SE 2000/80 MR image shows that area of abnormal signal in centrum semiovale has markedly prolonged T2 relaxation time as compared with gray matter, indicating gliosis.

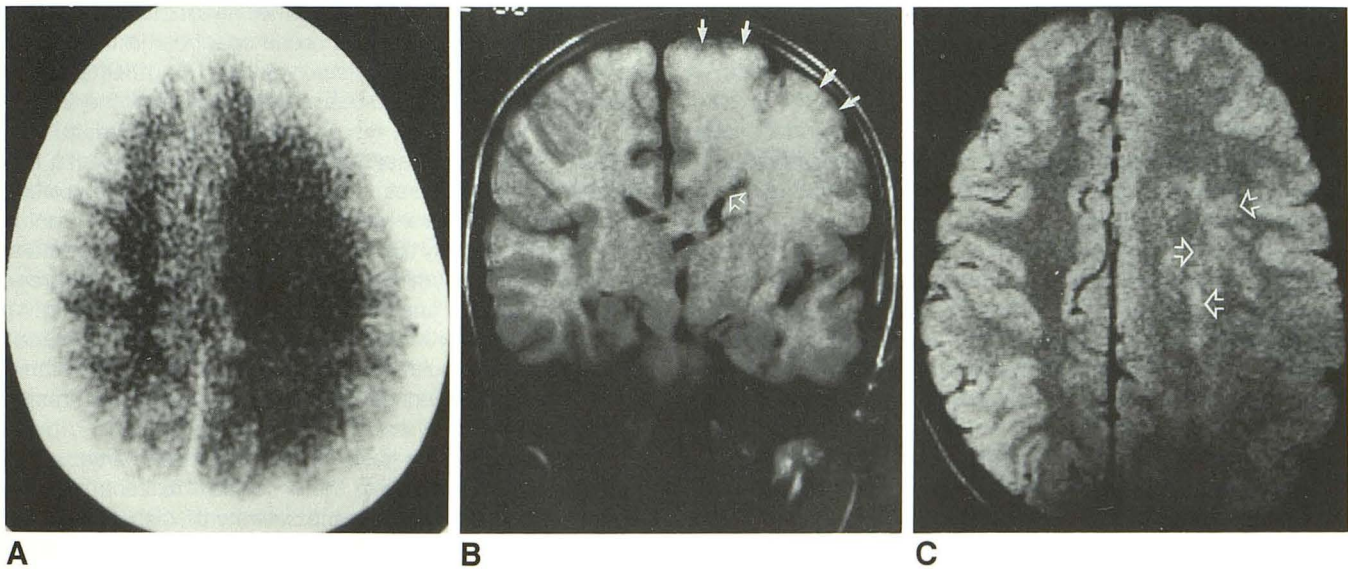


Fig. 5.—Case 9.

A, Axial unenhanced CT scan through centrum semiovale shows marked enlargement of left cerebral hemisphere with markedly increased quantity of hemispheric white matter.

B, Coronal SE 500/30 MR image shows enlargement of left hemisphere and cortical polymicrogyria (solid arrows). Left lateral ventricle is not enlarged; instead it seems compressed by layer of soft tissue adjacent to ventricle (open arrow).

C, Axial SE 2000/30 MR image at level of centrum semiovale shows multiple nodules isointense relative to gray matter within centrum semiovale (arrows). These nodules are not appreciated on CT (A).

hemisphere in case 1 seemed to result from a different process than in the other patients.

Angiography

The angiogram in case 11 was unremarkable. The angiograms in cases 2 and 3 both showed arteriovenous shunting

through the abnormal hemisphere with early filling of the deep venous system.

Pathology

Pathologic correlation was obtained in four patients. Hemispherectomy was performed in case 3, right frontal lobectomy in case 7, and occipital lobectomy in case 10. One

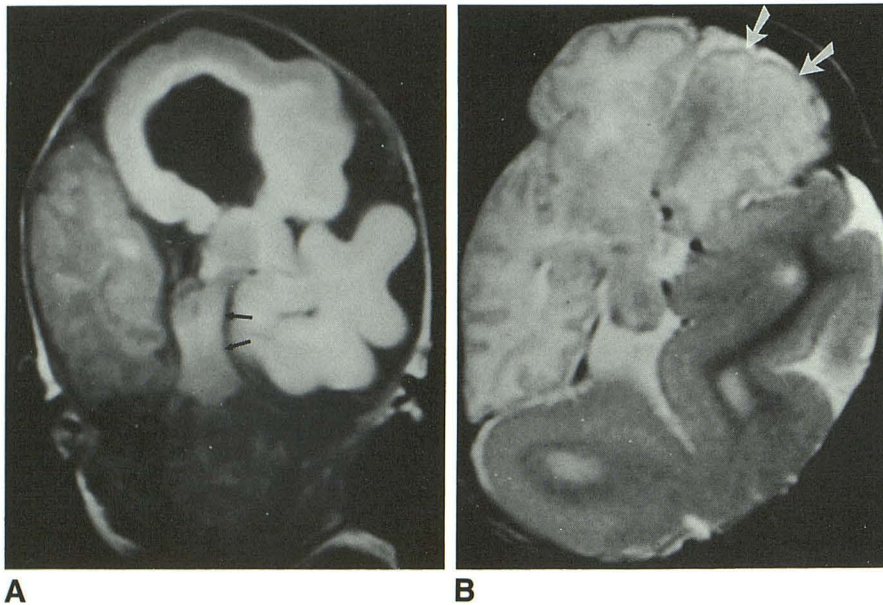


Fig. 6.—Case 1.

A, Coronal SE 600/20 MR image shows bizarre left cerebral hemisphere with very abnormal gyral pattern, diminished hemispheric white matter, and abnormal signal in white matter. Brainstem is compressed (*arrows*) by enlarged left temporal lobe. White matter has signal intensity of myelinated white matter, but white matter should not be myelinated in a 3-day-old neonate.

B, Axial SE 2800/100 MR image again shows markedly enlarged left cerebral hemisphere with bizarre gyral pattern and abnormal white-matter signal intensity. Note sparing of frontal lobe (*arrows*).

patient (case 8) died of unrelated causes and the brain was removed at autopsy (Fig. 1). All four patients had an irregularly thickened cortex that was diagnosed as polymicrogyria, with disorganized cortical neurons (in contradistinction to the normal layered pattern [Fig. 7]). Scattered heterotopic neurons were present in the white matter in all four patients. The gray-white junction was indistinct in cases 7 and 10. Gliosis was present in the centrum semiovale in all patients; in two patients (cases 3 and 7) axons were seen to course "chaotically" through the neuropil.

Discussion

Megalencephaly refers to enlargement of all or part of the cerebral hemispheres. It can be caused by a variety of disorders, including accumulation of abnormal metabolites (Tay-Sachs disease, mucopolysaccharidoses, Canavan disease, Alexander disease), tuberous sclerosis, and achondroplasia [11]. Megalencephaly limited to part or all of one hemisphere (unilateral megalencephaly) is considerably less common than the generalized form. It can be isolated [1–8], as in the series of patients described in this article, or associated with somatic hemihypertrophy [11–13].

Isolated unilateral megalencephaly (also known as hemimegalencephaly) is a poorly understood brain anomaly. Some authors [1, 5] report increased neuronal content of DNA and RNA in the affected hemisphere and suggest that the anomaly results from heteroploidy (an abnormal number of chromosomes) and a defect in cell metabolism during a critical period of development. Townsend et al. [2], in a study of three cases of unilateral megalencephaly, described a spectrum of involvement. One case showed mild hemispheric enlargement with scattered hypertrophied neurons and mild gliosis. A second, more severely affected, brain exhibited cortical polymicrogyria with pleomorphic neurons and moderate gliosis in the cortex

and white matter. In the most severe case, the markedly enlarged hemisphere was pachygyric with heterotopias and a nearly complete lack of white-matter myelination.

Our patients also showed a broad spectrum in the extent and severity of hemispheric involvement. The affected area of brain was localized in three patients, involving the frontal lobe in one (case 7) and the posterior temporal/parietal and occipital lobes in two (cases 10 and 12). In three patients, the affected hemisphere was largely, but not entirely, involved; the inferior frontal lobe was spared in two and both frontal and occipital poles in the third. The severity of involvement ranged from mild polymicrogyria with preservation of the gray-matter/white-matter junction and normal white matter (Fig. 1) to polymicrogyria with obliteration of the gray-matter/white-matter junction, multiple heterotopias, and white-matter gliosis (Fig. 3) to lissencephaly with no normal structures in the affected portion of the hemisphere (Fig. 2).

With the exception of case 1, with the bizarre hamartoma-like hemisphere, there seemed to be a roughly inverse relationship between the severity of the cortical and white-matter abnormalities and the size of the cerebral hemisphere. Those patients with agyria had only mild to moderate hemispheric enlargement (Fig. 2), whereas those with polymicrogyria, a distinct gray-matter/white-matter junction, and normal white matter had enormously enlarged hemispheres (Fig. 1). Patients with polymicrogyria, intermediate white-matter dysplasia, and macroscopic heterotopias had intermediate hemispheric enlargement (Fig. 3).

These relationships between the degree of hemispheric damage and enlargement may reflect the timing and severity of a hemispheric insult that causes both the cortical dysplasia and the overgrowth of the hemispheric white matter. Agyria is believed to result from an insult to the developing hemisphere at 13–14 gestational weeks, causing an arrest of the neuronal migration [14, 15]. Very few axons and dendrites have formed at the time of this insult, and agyric hemispheres

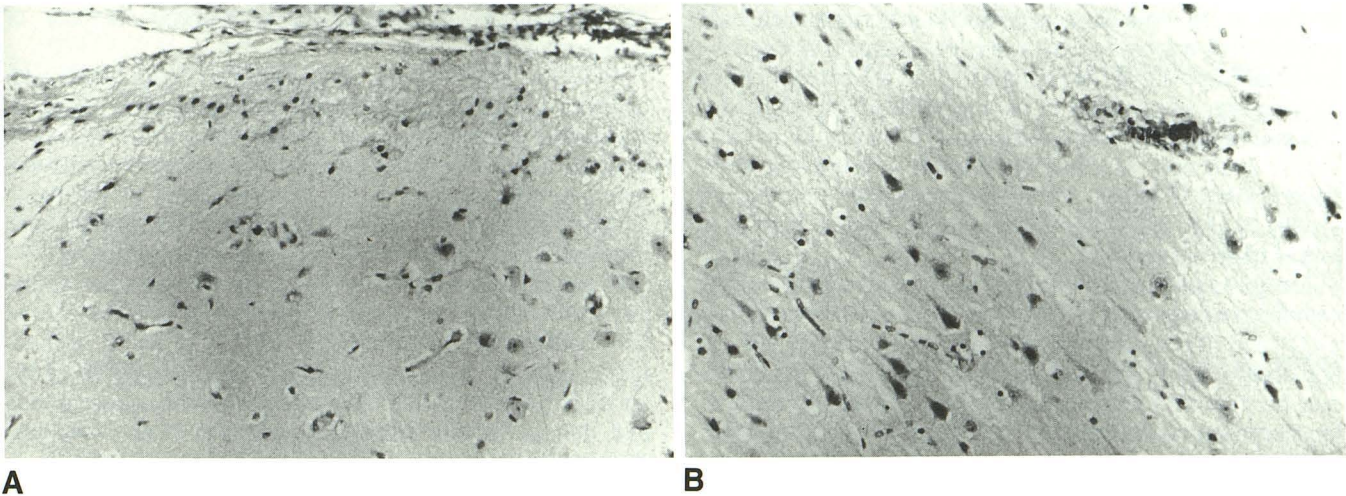


Fig. 7.—Case 7.

A, Histologic specimen from dysplastic area of resected cortex. Note random location of neurons and disorganized axonal pattern.
 B, Normal section of cortex for comparison. Cortical neurons and axons are arranged in regular, orderly pattern.

classically have a rather thin layer of hemispheric white matter between the thickened cortex and the lateral ventricles. In contradistinction, polymicrogyria is believed to result from an insult to the hemisphere during the middle-to-late second trimester [9, 16, 17], when axonal development and migration of young neurons through the developing hemisphere is high [18, 19].

A brief review of proposed mechanisms of establishment of the normal axonal connections of the brain may be helpful in deducing the cause of the excessive hemispheric white matter in unilateral megalencephaly. Evidence suggests that axonogenesis begins during the migration of the neurons from the germinal matrix to the cortex and continues throughout life [20–22]. The majority of axons develop during the middle-to-late second trimester. The axons are guided through the developing brain by interactions of the axonal growth cone, a motile sensory apparatus at the axonal tip, with surface markers on surrounding cells and chemotactic factors in the extracellular matrix [23]. These interactions are essential to guide the axon to its eventual destination within the hemisphere. On termination of its migration, the axon interacts with dendrites of neurons in its target region, establishing synaptic contacts. Many more axons are initially guided to a region of the brain than actually survive. By means of some mechanism involving the production and uptake of a neuronal growth factor, the “supernumerary” axons are eliminated [24–27].

Proposed causes for the hemispheric enlargement found in unilateral megalencephaly include heteroploidy of the cells [5] and a biochemical defect in control of cell metabolism [2, 5, 8]. Neither of these mechanisms, however, explains the accompanying neuronal migration abnormality that is invariably present in these patients. We speculate that an insult to the developing brain in the middle-to-late second trimester could account for both polymicrogyria and overgrowth of hemispheric white matter. Polymicrogyria can be caused by a

cortical insult during the last half of the second trimester [16, 17]. Such an insult, if not severe enough to frankly destroy the developing neuronal and glial cells, could nonetheless destroy or alter the cell membrane receptors and molecules in the extracellular matrix that guide the developing axons. The loss of this guidance would result in a more random, disorganized axonal migration. In fact, disorganized axons were a pathologic feature of the white matter in two of our patients. Insults of varying severity to the developing hemisphere would explain the different degrees of underlying gliosis in the hemispheric white matter and explain why more severe gliosis is associated with less hemispheric enlargement (a larger amount of frankly destroyed tissue results in fewer functional axons). Moreover, damage to the hemisphere may interfere with the very organized process of neuronal migration along radially oriented glial fibers [9, 28], resulting in neuronal heterotopias [2, 5–7].

The reason for the viability of the supernumerary axons after a mild insult should be addressed. In the normal situation, the surviving axons remain viable as a result of the uptake of various nerve growth factors on synaptogenesis. These factors are transmitted through the axon to the cell soma and nourish the cell [22, 23]. Theoretically, only the axons that reach the target area earliest obtain sufficient growth factor to remain viable; those arriving later receive an insufficient quantity of nerve growth factor or fail to synapse altogether and consequently regress [24–27]. The brain, however, has a great deal of plasticity, and new synapses form continually. In destructive brain lesions, new dendrites form and extend into the damaged region to form new synapses [29–32]. Furthermore, the amount of nerve growth factor and the number of nerve growth factor receptors of neurons increase locally after injury in laboratory animals [30–32]. Many other examples of both the development of new synapses [33, 34] and the persistence of supernumerary axons after damage to the developing brain [34, 35] have been reported. On the

basis of all this evidence, we postulate that megalencephalic hemispheres are caused by a mild insult during the second trimester, resulting in the formation of an excessive number of synapses (most often in abnormal locations) that allow supernumerary axons to persist into childhood and, in some cases, adulthood. Agyric hemispheres, in which the hemispheric insult is earlier, and hemispheres with more severe insults, marked gliosis, and macroscopic heterotopias have less marked enlargement.

The gross pathologic findings in our cases correlated well with the imaging findings. Polymicrogyria had an appearance on CT and MR of mildly thickened cortex with broad, flat gyri and shallow sulci. The inner and outer surfaces of the cortex may be smooth or irregular and the gray-matter/white-matter junction sharp or indistinct. Gliosis commonly occurs in the underlying white matter. The small individual microgyri are resolved only occasionally. The lack of resolution probably results from a combination of the inherently small size of the microgyri, a frequently paradoxically smooth surface resulting from a lack of involvement of the molecular layer of the cortex [16], and the presence of glial-mesodermal scar in the small sulci between the microgyri [36]. The correlation obtained from our imaging and pathologic findings seems to indicate that the imaging characteristics of polymicrogyria are specific and can be differentiated from pachygyria. In pachygyria the cortex is moderately to severely thickened with very broad gyri and shallow sulci. The inner and outer surfaces of the cortex are smooth (Fig. 2). There is a thin layer of underlying white matter that has normal signal intensity.

The bizarre hemisphere in case 1 is quite different from all of the other affected hemispheres in this series. In contradistinction to the other megalencephalic hemispheres, the gyral pattern does not resemble that of any neuronal migration anomaly. The marked diminution of hemispheric white matter also differs from the remaining cases in this series, which, with the exception of cases 2 and 5, all had an increase in hemispheric white matter. Finally, the intensity patterns of gray matter and white matter are reversed from those in the normal neonate (Fig. 6). The abnormal hemisphere in this patient had signal intensities more compatible with myelinated white matter. The abnormal infoldings and signal intensities and the spectacular enlargement of the affected hemisphere in case 1 suggest a hamartomatous process and seem to support the concept of Townsend et al. [2] that some of these patients have hamartomatous or even neoplastic overgrowth of the affected hemisphere.

The presenting signs and symptoms in our patients correlated well with those reported in previous studies. All our patients had a seizure disorder that started in the first 4 months of life. The seizures are almost always intractable, unilateral, and tonic-clonic in nature; occasionally they are initially manifest as infantile spasms. When the rolandic region is involved, contralateral hemiparesis is invariably present. When the visual cortex is primarily affected, as in cases 10 and 12, hemianopsia is present. Those patients who have some degree of normal development and intractable seizures, with a demonstrable seizure focus within the megalencephalic

hemisphere, are candidates for a hemispherectomy or lobectomy [7].

Although an association of congestive heart failure with unilateral megalencephaly has not been previously reported, congestive heart failure was present in two (17%) of 12 patients in our series. Angiography in these patients showed arteriovenous shunting in the involved areas of the hemisphere. Abnormal vascularity in regions of abnormal neuronal migration (particularly polymicrogyria) has been described [37] and is not surprising when the dynamic response of the developing cerebral cortical vasculature to changes in the surrounding brain is considered [38]. The same second-trimester insults that cause polymicrogyria and gliosis of the underlying white matter can destroy cortical capillary beds and normal venous pathways, resulting in arteriovenous shunting into abnormal veins.

In summary, we have presented the radiologic and clinical features of 12 patients with unilateral megalencephaly. Pathologic correlation was obtained in four patients. All patients had seizures and developmental delay; two had congestive heart failure secondary to arteriovenous shunting in the abnormal hemisphere. A wide spectrum of severity and extent of involvement was present in the affected hemisphere. There seems to be an inverse relationship between the severity of involvement and the degree of enlargement of the affected brain; a mechanism to explain this relationship is postulated. One patient had a severely anomalous hemisphere with abnormal white matter and a bizarre gyral pattern that was clearly different from the pattern in the other 11. We postulate a different mechanism, perhaps a hamartomatous or neoplastic malformation, as the cause of the anomaly in this patient.

REFERENCES

1. Bignami A, Palladini G, Zapella M. Unilateral megalencephaly with nerve cell hypertrophy. An anatomical and quantitative histochemical study. *Brain Res* 1968;9:103-114
2. Townsend JJ, Nielsen SL, Malamud N. Unilateral megalencephaly: hamartoma or neoplasm? *Neurology* 1975;25:448-453
3. Fitz CR, Harwood-Nash DC, Boldt DW. The radiographic features of unilateral megalencephaly. *Neuroradiology* 1978;15:145-148
4. Tjiam AT, Stefanko S, Schenk VWD, de Vlieger M. Infantile spasms associated with hemihypsarrhythmia and hemimegalencephaly. *Dev Med Child Neurol* 1978;20:779-798
5. Manz HJ, Phillips TM, Rowden G, McCullough DC. Unilateral megalencephaly, cerebral cortical dysplasia, neuronal hypertrophy, and heterotopia: cytomorphometric, fluorometric cytochemical, and biochemical analyses. *Acta Neuropathol (Berl)* 1979;45:97-103
6. Damska M, Wisniewski K, Sher JH. An autopsy case of hemimegalencephaly. *Brain Dev* 1984;6:60-64
7. King M, Stephenson JBP, Ziervogel M, Doyle D, Galbraith S. Hemimegalencephaly: a case for hemispherectomy? *Neuropediatrics* 1985;16:46-55
8. Kalifa GL, Chiron C, Sellier N, et al. Hemimegalencephaly: MR imaging in five children. *Radiology* 1987;165:29-33
9. Barkovich AJ, Chuang SH, Norman D. MR of neuronal migration anomalies. *AJNR* 1987;8:1009-1017
10. Barkovich AJ, Kjos BO, Jackson DE Jr, Norman D. Normal maturation of the neonatal and infant brain: MR imaging at 1.5T. *Radiology* 1988;166:173-180
11. Warkany J, Lemire RJ, Cohen MM Jr. *Mental retardation and congenital malformations of the central nervous system*. Chicago: Yearbook Medical, 1981:101-122
12. Hallervorden J. Microscopic findings in brain in case of congenital hemi-

- hypertrophy of left side of body including brain. *Dtsch Z Nervenheilkinder* **1926**;89:28-42
13. Rugel SJ. Congenital hemihypertrophy: report of a case with postmortem observations. *Am J Dis Child* **1946**;71:530-536
 14. Barkovich AJ, Norman D. Anomalies of the corpus callosum: correlation with further anomalies of the brain. *AJNR* **1988**;9:493-501
 15. Jellinger K, Rett A. Agyria-pachygyria (lissencephaly syndrome). *Neuropædiatrie* **1976**;7:66-91
 16. Richman DP, Stewart RM, Caviness VS Jr. Cerebral microgyria in a 27-week fetus: an architectonic and topographic analysis. *J Neuropathol Exp Neurol* **1974**;33:374-384
 17. Dvork K, Feit J. Migration of neuroblasts through partial necrosis of the cerebral cortex in newborn rats—contribution to the problems of morphological development and developmental period of cerebral microgyria. *Acta Neuropathol (Berl)* **1977**;38:203-212
 18. McConnell SK. Development and decision-making in the mammalian cerebral cortex. *Brain Res Rev* **1988**;13:1-23
 19. Schwartz ML, Goldman-Rakic PS. Some callosal neurons of the fetal monkey frontal cortex have axons in the contralateral hemisphere prior to the completion of migration. *Soc Neurosci Abstr* **1986**;12:1211
 20. Leonard CT, Goldberger ME. Consequences of damage to the sensorimotor cortex in neonatal and adult cats. I. Sparing and recovery of function. *Dev Brain Res* **1987**;32:1-14
 21. Petit TL, LeBoutillier JC, Gregorio A, Libstug H. The pattern of dendritic development in the cerebral cortex of the rat. *Dev Brain Res* **1988**;41:209-219
 22. Mattson MP. Neurotransmitters in the regulation of neuronal cytoarchitecture. *Brain Res Rev* **1988**;13:179-212
 23. Dodd J, Jessell TM. Axon guidance and the patterning of neuronal projections in vertebrates. *Science* **1988**;242:692-699
 24. Rakic P, Riley KP. Overproduction and elimination of retinal axons in the fetal rhesus monkey. *Science* **1983**;219:1441-1444
 25. van Huizen F, Romijn HJ, Corner MA. Indications for a critical period of synapse elimination in developing rat cerebral cortex cultures. *Dev Brain Res* **1987**;31:1-6
 26. Purves D, Lichtman JW. Elimination of synapses in the developing nervous system. *Science* **1980**;210:153-157
 27. Provis JM, van Driel D, Billson FA, Russell P. Human fetal optic nerve: overproduction and elimination of retinal axons during development. *J Comp Neurol* **1985**;238:92-100
 28. Rakic P. Neuronal migration and contact guidance in the primate telencephalon. *Postgrad Med J* **1978**;[Suppl 1]54:25-37
 29. Perry VH, Maffei L. Dendritic competition: competition for what? *Dev Brain Res* **1988**;41:195-208
 30. Collins F, Crutcher KA. Neurotrophic activity in the adult rat hippocampal formation: regional distribution and increase after septal lesion. *J Neurosci* **1985**;5:2809-2814
 31. Gage FH, Armstrong DM, Williams LR, Varon S. Morphological response of axotomized septal neurons to nerve growth factor. *J Comp Neurol* **1988**;269:147-155
 32. Gage FH, Batchelor P, Chen KS, et al. NGF receptor reexpression and NGF-mediated cholinergic neuronal hypertrophy in the damaged adult neostriatum. *Neuron* **1989**;2:1177-1184
 33. Easter SS Jr, Purves D, Rakic P, Spitzer NC. The changing view of neural specificity. *Science* **1985**;230:507-511
 34. Lenn NJ. Neuroplasticity and the developing brain: implications for therapy. *Pediatr Neurosci* **1987**;13:176-183
 35. Goldman-Rakic PS. Morphological consequences of prenatal injury to the primate brain. *Prog Brain Res* **1980**;53:1-19
 36. Ferrer I. A Golgi analysis of unlayered polymicrogyria. *Acta Neuropathol (Berl)* **1984**;65:69-76
 37. Barkovich AJ. Abnormal vascular drainage in neuronal migration anomalies. *AJNR* **1988**;9:939-942
 38. Marin-Padilla M. Early ontogenesis of the human cerebral vasculature. In: Peters A, Jones EG, eds. *Cerebral cortex*, vol. 7. *Development and maturation of the cerebral cortex*. New York: Plenum, **1988**:475-502