

Are your **MRI contrast agents** cost-effective?

Learn more about generic **Gadolinium-Based Contrast Agents**.



**FRESENIUS
KABI**
caring for life

AJNR

CT demonstration of pneumatization of the uncinata process.

W E Bolger, W Woodruff and D S Parsons

AJNR Am J Neuroradiol 1990, 11 (3) 552

<http://www.ajnr.org/content/11/3/552.citation>

This information is current as of May 7, 2024.

CT Demonstration of Pneumatization of the Uncinate Process

Pneumatization of the uncinat process is an anatomic variation rarely seen on CT of the paranasal sinuses. Although this entity has been noted before [1-3], it has not been illustrated clearly in the literature. We report on a series of patients in whom pneumatization of the uncinat process was noted on coronal CT scanning of the paranasal sinuses.

Materials and Methods

Consecutive coronal CT scans of the paranasal sinus and radiologic medical records of patients examined at Wilford Hall USAF Medical Center from July 1987 through December 1988 were reviewed for the presence of pneumatization of the uncinat process. Patients with previous alteration of the anatomy of the paranasal sinus due to facial trauma, carcinoma of the paranasal sinus, inverted papilloma, or extensive sinus surgery were not included in the study.

CT examinations were performed on either a GE 8800 (Milwaukee, WI) or a Philips Tomoscan 60/TX (Shelton, CT) unit. Data were acquired in the coronal plane without the use of IV contrast material. The images were collimated to 5 mm and obtained at 3-mm increments from the glabella to the dorsum sellae. A total of 263 coronal series CT scans were reviewed initially. Sixty-one patients failed to meet the study criteria. The final study group was composed of the remaining 202 patients.

Results

Eight patients (4%) had some pneumatization of the uncinat process. Extensive pneumatization, also called an uncinat process bulla (Figs. 1A and 1B), occurred unilaterally in four patients (2%). Bilateral uncinat bullae (Fig. 1C) occurred in one patient (0.5%). In three others (1.5%), mild pneumatization was evident; the uncinat process contained only a small air cell (Fig. 1D). Extensive pneumatization or bulla formation was absent in these three patients.

Discussion

With the advent of direct coronal CT scanning of the paranasal sinuses, detailed analysis of the anatomy of this area is now possible. As diagnostic use of the technique increased, awareness of bony anatomic variations in this region also increased. Subtle anatomic variations, such as turbinate pneumatization, Haller's cells, paradoxically bent middle turbinates, and medially or laterally bent uncinat processes are now recognized routinely on CT scans. Clinically, these anatomic variations are important, as they have been implicated as possible etiologic factors in selected cases of recurrent sinusitis and headaches, owing to their negative influence on sinus ventilation [3].

Pneumatization of the uncinat process also has been cited as an anatomic variation that can impair sinus ventilation, specifically in the anterior ethmoid, frontal recess, and infundibular regions [3]. It also has been implicated as a possible etiologic factor in selected cases of recurrent sinusitis and headaches [3]. Pneumatization of the uncinat process is, however, an uncommon variation. Early anatomists, during gross anatomic investigation of the paranasal sinuses, noted that the upper part of the uncinat process was undermined by an excavation of the agger nasi cell, yet they failed to describe formation of uncinat bullae or to provide data on the frequency of pneumatization of the uncinat process [4, 5]. Recently, Kennedy and Zinreich [2] noted one patient (0.4%) with an uncinat process bulla in a series of 230 patients with chronic sinus complaints who had coronal CT. In our series, an uncinat process bulla also occurred infrequently (2.5% of patients). One patient had this anatomic variation bilaterally. In three patients, limited pneumatization of the uncinat was evident, although an uncinat process bulla was not present. This suggests that various degrees of pneumatization of this structure can exist.

Analysis of uncinat pneumatization patterns in patients with uncinat bulla revealed that pneumatization occurred in the most anterior-superior region of the uncinat process, because of an excavation of the agger nasi cell. Pneumatization in this region potentially could impair frontal sinus ventilation. With more extensive pneumatization, bulla formation involved nearly the entire uncinat process. Impaired ventilation of the ethmoid infundibulum, and hence the maxillary and anterior ethmoid sinus regions, might be expected in such cases (Fig. 1C).

William E. Bolger
William Woodruff
David S. Parsons

Wilford Hall USAF Medical Center
Lackland AFB, TX 78236-5300

Note.—The opinions or assertions contained herein are the private views of the authors and are not to be construed as official or as reflecting the views of the Department of the Air Force or the Department of Defense.

REFERENCES

1. Zinreich SJ, Kennedy DW, Rosenbaum AE, Gayler BW, Kumar AJ, Stammberger H. Paranasal sinuses: CT imaging requirements for endoscopic surgery. *Radiology* 1987;163:769-775
2. Kennedy DW, Zinreich SJ. The functional endoscopic approach to inflammatory sinus disease: current perspectives and technique modification. *Am J Rhinol* 1988;2:89-96
3. Stammberger H, Wolf G. Headaches and sinus disease: the endoscopic approach. *Ann Otol Rhinol Laryngol* 1988;97(suppl 134)
4. Shambaugh GE. The construction of the ethmoid labyrinth. *Ann Otol Rhinol Laryngol* 1907;16:771-775
5. Van Aleya OE. Ethmoid labyrinth: anatomic study, with consideration of its structural characteristics. *Arch Otolaryngol* 1939;29:881-901

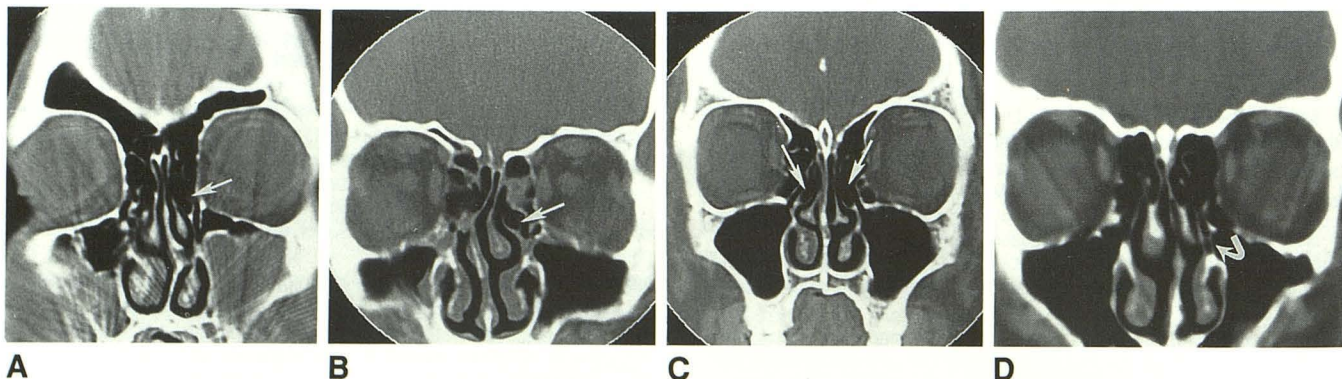


Fig. 1.—CT scans show four examples of pneumatization of uncinat process. A and B, Unilateral process bullae (arrows) caused by extensive pneumatization. C, Bilateral uncinat process bulla (arrows). D, Unilateral process bulla (arrow) caused by mild pneumatization.