

Generic Contrast Agents

Our portfolio is growing to serve you better. Now you have a *choice*.



FRESENIUS
KABI

[VIEW CATALOG](#)

AJNR

The arteries of the lingual thyroid: angiographic findings and anatomic variations.

M Banna and P Lasjaunias

AJNR Am J Neuroradiol 1990, 11 (4) 730-732

<http://www.ajnr.org/content/11/4/730.citation>

This information is current as
of May 9, 2025.

The Arteries of the Lingual Thyroid: Angiographic Findings and Anatomic Variations

Mohamed Banna¹ and Pierre Lasjaunias²

There are few reports of persistent lingual thyroid gland, and none that describe the vascular supply of this rare congenital anomaly [1, 2]. This article describes the angiographic findings in one case of lingual thyroid and illustrates the anatomic variations of the thyroid arteries in relation to gland development.

Case Report

A 22-year-old man presented with a 6-month history of dysphagia to solid food and intermittent spitting of blood for about 1 year. A lateral radiograph of the neck revealed a well-defined soft-tissue mass at the base of the tongue, compromising the oropharynx. After a series of tests, which included CT (Fig. 1) and radionuclide scintigraphy, the diagnosis of lingual thyroid was made. A thyroid profile showed normal levels of T3 and T4; thyroid binding globulin was normal [2].

A selective external carotid angiogram was performed with the view that embolization or partial surgical removal may be required if suppression of the thyroid function failed to shrink the gland to a degree that cured the dysphagia. At angiography, the superior thyroid arteries were absent and the superior laryngeals originated directly

from the external carotids (Fig. 2). The gland itself was supplied by separate branches from the lingual arteries (Fig. 3). After treatment with 10 mCi of iodine-131 the patient was relieved of dysphagia, but had to be maintained on lifelong intake of thyroxine.

Discussion

There are three topics pertaining to the description of the arterial supply of the lingual thyroid: anatomic variations of arteries that supply the normal gland, the arterial supply of the ectopic thyroid, and correlation of the vascular anomalies with the development of the thyroid gland.

Anatomic Variations of Arteries That Supply the Normal Thyroid Gland

The normal thyroid gland derives its blood supply from the superior and inferior thyroid arteries and from the arteria thyroidea ima [3].

1. The superior thyroid artery originates from the external carotid in 68% of patients, a carotid bifurcation in 20%, or

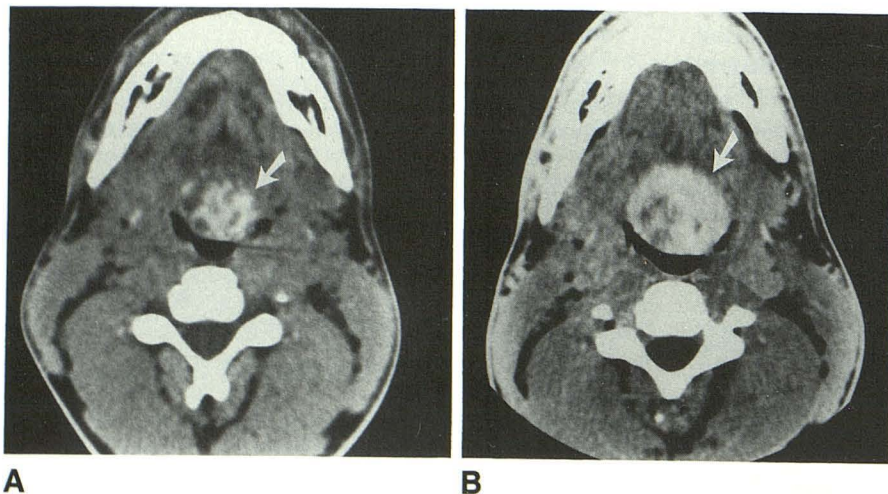


Fig. 1.—A and B, Axial unenhanced (A) and enhanced (B) CT scans of upper part of neck show high concentration of iodine in thyroid gland (arrows) at base of tongue, compromising the oropharynx.

Received August 14, 1989; revision requested October 23, 1989; revision received November 30, 1989; accepted December 4, 1989.

¹Department of Radiology, King Faisal Specialist Hospital, P. O. Box 3354, Riyadh 11211, Saudi Arabia. Address reprint requests to M. Banna.

²Department of Vascular Neuroradiology, Centre Hospitalier de Bicetre, Paris, France.

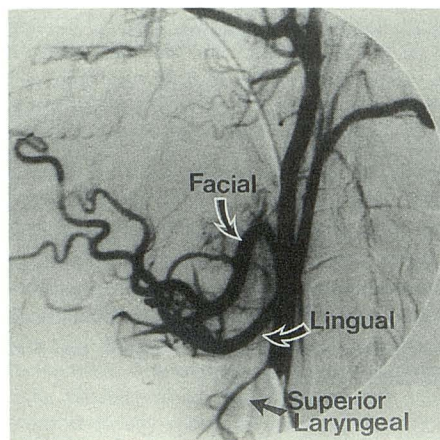
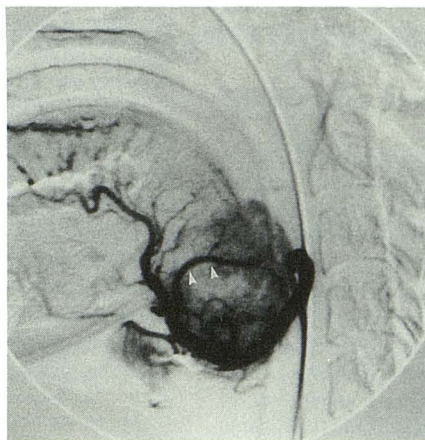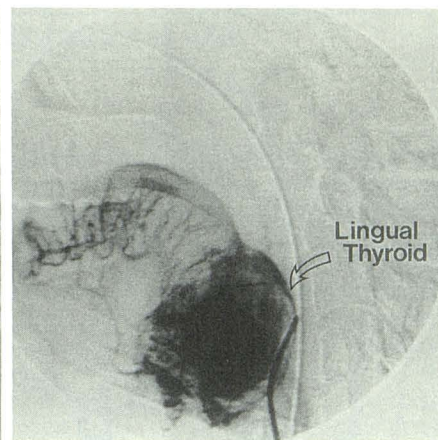


Fig. 2.—Selective external carotid angiogram shows origin of superior laryngeal artery from the external carotid. Superior thyroid artery is absent.



A



B

Fig. 3.—A and B, Selective catheterization of lingual artery demonstrates the embryonic thyroid branch (arrowheads in A) and the hypervascularity of the lingual thyroid gland (curved arrow in B).

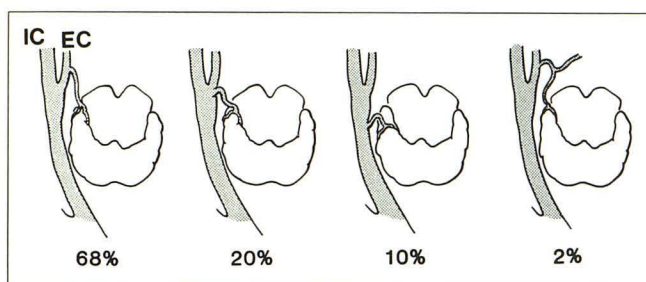


Fig. 4.—Variations in the origin of the superior thyroid artery. The artery arises from the external carotid (68%), carotid bifurcation (20%), common carotid (10%), and lingual artery (2%).

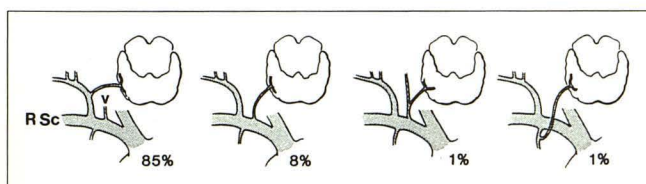


Fig. 5.—Variations in the origin of the inferior thyroid artery may arise from the thyrocervical trunk (85%), subclavian artery (8%), vertebral artery (1%), or internal mammary artery (1%).

common carotid in 10%. In the remaining 2%, the superior thyroid originates from the lingual artery (Fig. 4) [3].

2. The inferior thyroid artery originates from the thyrocervical trunk in 85%, or subclavian artery in 8%. In the remaining 7%, the inferior thyroid originates from the vertebral (1%), internal thoracic (1%), or common carotid artery (1%). The inferior thyroid may be absent in about 3% of individuals (Fig. 5) [3].

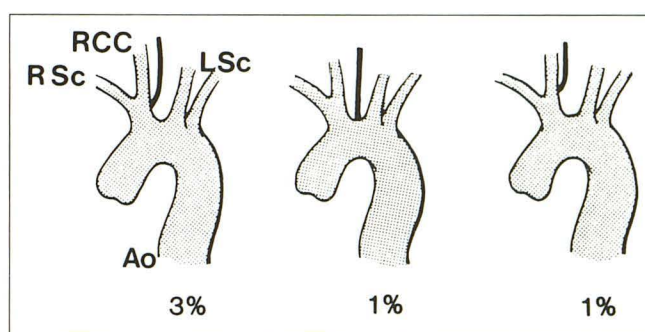


Fig. 6.—Variations in the origin of arteria thyroidea ima.

3. The arteria thyroidea ima, the lowest thyroid artery, is present in about 6% of individuals and may originate from the brachiocephalic (3%), aortic arch (1%), or common carotid (1%) (Fig. 6) [3].

The Arterial Supply of the Lingual Thyroid

As illustrated in the present patient, a thyroid gland that is arrested at the base of the tongue receives its blood supply from the lingual arteries. The superior thyroid arteries are absent and the superior laryngeal arteries, which are normally considered to be branches of the superior thyroids, originate directly from the external carotids.

Correlation of Vascular Anomalies with the Development of the Thyroid Gland

The thyroid gland develops as a median epithelial diverticulum that appears in about the fourth week of gestation in

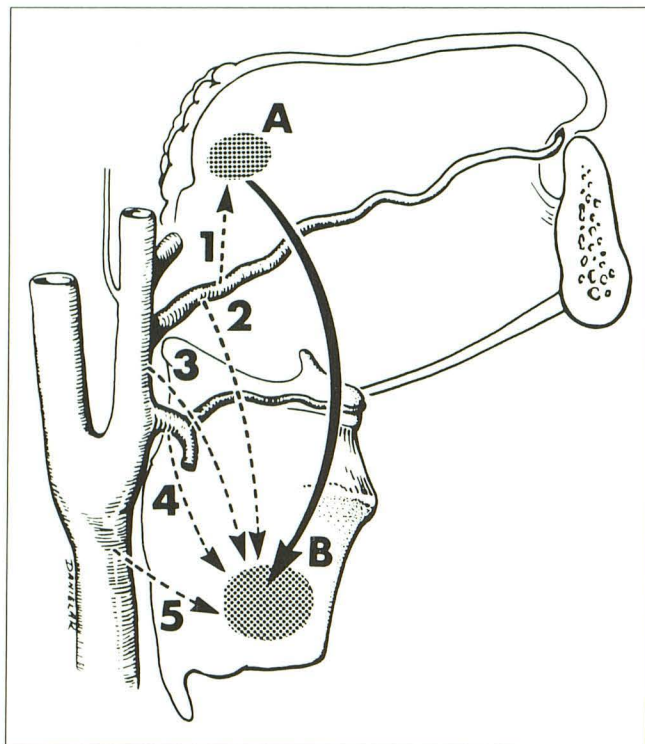


Fig. 7.—Diagram showing the possible sources of arterial supply of the thyroid gland during its descent from the base of the tongue to the lower part of the neck (A to B). 1 = arterial supply of the embryonic thyroid gland from the lingual artery; 2 = corresponding anatomic variant that may be encountered in approximately 2% of individuals with normally located thyroid; 3 = independent origin of superior thyroid from external carotid; 4 = common origin of superior thyroid with superior laryngeal from the external carotid; and 5 = origin of superior thyroid from the common carotid.

the floor of the pharynx opposite the first and second pharyngeal pouches close to the aortic sac. As the sac migrates caudally during neck development, the thyroid migrates with it. During migration its stalk is drawn out to form the thyroglossal duct. The gland reaches its normal site by the seventh week, when the embryo has a crown-rump length of about 7 mm [4]. The primordium of the gland receives its blood supply from the arteries that later give rise to the lingual and submental vessels. During its descent, the gland establishes new connections with the nearest vessels as older connections are attenuated and disappear. Persistence of these vessels at any stage in the migration of the gland explains the anatomic variations of its arterial supply (Fig. 7).

ACKNOWLEDGMENTS

We thank Mary Beth Danielak for her artwork and Catherine Devane for her secretarial assistance.

REFERENCES

1. Chanin LR, Greenberg LM. Pediatric upper airway obstruction due to ectopic thyroid: classification and case reports. *Laryngoscope* 1988;98:422-427
2. Kansal P, Sakati N, Rifai A, Woodhouse N. Lingual thyroid. *Arch Intern Med* 1987;147:2046-2048
3. Lippert H, Pabst R. *Arterial variations in man: classification and frequency*. Berlin: Springer-Verlag (Bergmann), 1985;6, 80, 83
4. Moore KL. *The developing human embryo*. Philadelphia: Saunders, 1982:193-195