

Are your MRI contrast agents cost-effective?

Learn more about generic Gadolinium-Based Contrast Agents.



**FRESENIUS
KABI**

caring for life

AJNR

Spontaneous lumbar subdural hematoma.

J M Levy

AJNR Am J Neuroradiol 1990, 11 (4) 780-781

<http://www.ajnr.org/content/11/4/780.citation>

This information is current as
of April 16, 2024.

Spontaneous Lumbar Subdural Hematoma

Two patients had similar complaints of low back pain. Both had bilateral lower-extremity radiculopathy and, at first, acute herniation of the lumbar disk was suspected. Further evaluation with CT and MR showed hemorrhage in the lumbar subdural space.

Case Reports

Case 1

A 43-year-old man had had severe low back pain and bifrontal headache for 10 days. He had no history of trauma. CT scans of the brain were normal. The results of laboratory tests, including prothrombin and partial thromboplastin times, were normal. Physical examination showed bilateral radicular pain in the lower extremities with positive bilateral straight leg raising of 5–10°. CT of the lumbar spine (Fig. 1A) showed increased attenuation in the posterior part of the thecal sac. Gradient-echo axial and T2-weighted sagittal MR images (Figs. 1B and 1C) showed abnormal signal intensity in the same area. Laminectomies were performed at the L4 and L5 levels. At surgery, the dura was "tense and bluish." Semiliquid blood was removed from the subdural space. The postoperative course was uneventful, and the patient recovered fully.

Case 2

An 81-year-old woman had had intractable low back pain for 2 weeks. The pain radiated down the posterior thighs and was greater on the right than on the left. Physical examination showed positive straight leg raising of 30° on the right and 45° on the left. The results of electromyography were consistent with bilateral L3, L4, and L5 radiculopathy. T1-weighted axial and T2-weighted sagittal MR images (Fig. 2) showed abnormally increased signal intensity in the distal, posterior part of the thecal sac. The patient had fluoroscopically guided lumbar puncture at the L5–S1 level. Blackish liquid blood (12–15 ml) was removed. The patient's symptoms resolved almost immediately.

Discussion

The prevalence of subdural hematoma in the lumbar region is low. Thirty-nine cases of spinal subdural hematoma were reported in the

literature between 1948 and 1988 [1–4]. Of these, 46% were due to bleeding diathesis or bleeding diathesis with lumbar puncture, and 39% were due to lumbar puncture alone. Both patients described here had neither bleeding diathesis nor lumbar puncture.

In case 1, CT and MR were performed 10 days after the onset of symptoms. Gradient-echo axial MR showed high-signal-intensity hemorrhage in the lumbar subdural space, and T2-weighted sagittal MR showed low-signal-intensity hemorrhage. High signal intensity would be expected on T2-weighted images after 10 days. This could be the effects of remaining intracellular methemoglobin or paramagnetic effects of iron from breakdown products of blood. Another explanation could be the presence of deoxyhemoglobin in the subdural space if hemorrhage recurred before the MR and CT studies were done. This possibility is most likely since the subdural hemorrhage also had high attenuation on the CT scan.

Prompt recognition of the presence of spinal subdural hematoma is aided greatly by MR imaging. Finding abnormal signal intensity within the subdural space confirms the diagnosis. Spontaneous spinal subdural hematoma has been reported to produce certain characteristic clinical features, including sudden backache with radicular pain followed by signs and symptoms of spinal cord dysfunction [5]. The

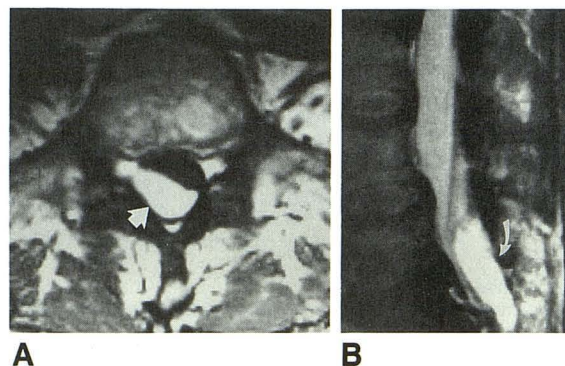


Fig. 2.—Spontaneous lumbar subdural hematoma in an 81-year-old woman.

A, Axial T1-weighted MR image, 800/19, at L5 level shows increased signal intensity (arrow) in posterior subdural space, greater on right than on left.

B, Sagittal T2-weighted MR image, 2000/90, shows increased signal intensity in posteroinferior subdural space (arrow) at lumbosacral junction.

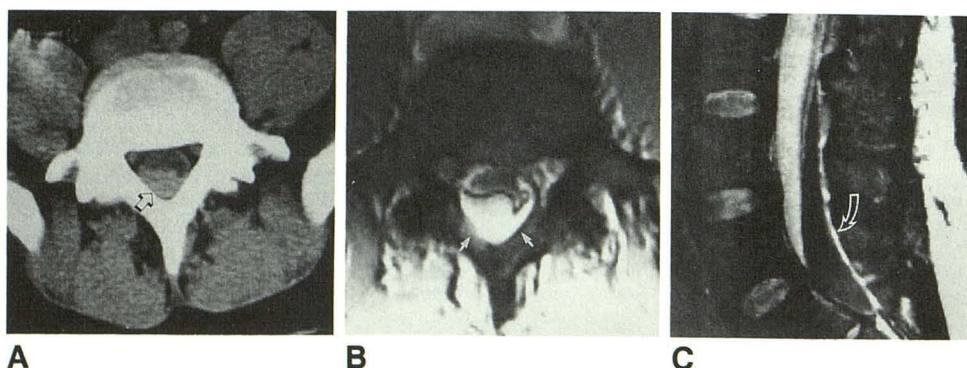


Fig. 1.—Spontaneous lumbar subdural hematoma in a 43-year-old man.

A, Axial CT scan at L5 level shows increased attenuation (arrow) in posterior part of spinal canal.

B, Axial gradient-echo MR image, 300/10/50°, at L5 level shows increased signal intensity in subdural space (arrows). Note anterior extension of hematoma and compression of thecal sac.

C, Sagittal T2-weighted MR image, 2000/90, of lumbosacral spine shows low-signal-intensity crescentic hemorrhage (arrow) spanning from L4 to S1.

mechanism of spontaneous lumbar subdural hematoma remains unknown. Minor trauma, perhaps not remembered by the patient, has been postulated as the cause [6, 7]. Most often, spinal subdural hematoma is associated with bleeding diathesis, previous lumbar puncture, a combination of bleeding diathesis and lumbar puncture, or trauma [1, 2]. Prompt surgical evacuation or percutaneous drainage may lead to resolution of symptoms and complete resolution of neurologic deficits.

Joseph M. Levy
Lutheran General Hospital
Park Ridge, IL 60068

ACKNOWLEDGMENTS

I gratefully acknowledge the assistance of Per Freitag, Jerry Bauer, Rajan K. Raj, and George Karkazis.

Note.—The preceding report was presented at the annual meeting of the American Society of Neuroradiology, Orlando, FL, March 1989.

REFERENCES

1. Gutterman P. Acute spinal subdural hematoma following lumbar puncture. *Surg Neurol* 1977;7:355-356
2. Tomarken JL. Spinal subdural hematoma: a case report and literature review. *Am J Emerg Med* 1987;5:123-125
3. Anagnostopoulos DI, Gortvai P. Spontaneous spinal subdural hematoma. *Br Med J* 1982;1:30
4. Tantana S, Pilla TS, Luisiri A. Computed tomography of acute spinal subdural hematoma. *J Comput Assist Tomogr* 1986;10:891
5. Guy MJ, Zahra M, Sengupta RP. Spontaneous subdural haematoma during general anaesthesia. *Surg Neurol* 1987;11:199-200
6. Ainslie JP. Paraplegia due to spontaneous extradural or subdural hemorrhage. *Br J Surg* 1958;45:565-567
7. Edelson RN. Spinal subdural hematoma. In: Vinken PJ, Bruyn GW, eds. *Handbook of clinical neurology*, vol. 26. Amsterdam: North Holland Publishing, 1976:31