This information is current as of October 12, 2024.

Duplex Doppler sonography of the carotid artery: false-positive results in an artery contralateral to an artery with marked stenosis.

W W Beckett, Jr, P C Davis and J C Hoffman, Jr

AJNR Am J Neuroradiol 1990, 11 (5) 1049-1053
http://www.ajnr.org/content/11/5/1049

Duplex Doppler Sonography of the Carotid Artery: False-Positive Results in an Artery Contralateral to an Artery with Marked Stenosis

William W. Beckett, Jr.[1]
Patricia C. Davis
James C. Hoffman, Jr.

Anecdotal reports have described a false-positive "jet effect" or velocity increase in the carotid artery contralateral to an artery with significant stenosis or occlusion when using duplex Doppler sonography. In this study, the frequency, significance, and possible reasons for this finding were evaluated by a retrospective comparison of duplex sonography and angiography. Twenty-three patients with unilateral 81–100% carotid artery stenosis who underwent both duplex sonography (16 Acuson, seven Quantum) and angiography were evaluated. In 14 patients, there was an accurate or slight underestimate (<20%) of stenosis present in the internal carotid artery contralateral to an artery with tight stenosis/occlusion. In nine, a velocity increase in the internal carotid artery resulted in overestimation (10–80%) of the actual degree of stenosis. In one of these nine patients, real-time images were sufficient to explain the velocity increase on the basis of vessel tortuosity. In one, falsely elevated velocity resulted from inaccurate assignment of the Doppler angle of incidence in a patient in whom real-time visualization of a distal internal carotid lesion was poor. In four of the nine patients, cross filling via the circle of Willis toward the side of greater stenosis occurred. However, seven of 14 patients in whom there was duplex sonography/angiography agreement or slight duplex sonography underestimation also had cross filling. Vertebral artery patency did not correlate well with the presence of a "jet effect."

These findings suggest that an increase in blood flow velocity with duplex Doppler sonography in the internal carotid artery on the side opposite an artery with a tight stenosis is a common source of error and is not readily explained by angiographic evidence of collateral flow.

***AJNR* 11: 1049–1053, September/October 1990; *AJR* 155: November 1990**

Duplex sonography (real-time imaging combined with Doppler) evaluation of the internal carotid artery contralateral to an artery with a significant (81–100%) stenosis/occlusion occasionally reveals a "jet effect" or an increase in velocity that is disproportionately high for the degree of stenosis actually present. Although this finding has been anecdotally reported as a pitfall of duplex sonography (Zweibel WJ, Dreisbach JN. Paper presented at annual meeting of RSNA, December 1986) and [1, 2], the frequency and cause of this false-positive velocity increase have not been studied in detail. For this reason, we undertook a retrospective study of duplex sonography findings in the common carotid/internal carotid arteries in a series of patients with a contralateral, angiographically proved, high-grade internal carotid artery stenosis/occlusion.

Materials and Methods

Between January 1987 and May 1988, 23 consecutive patients who had duplex sonography followed by carotid angiography and who had a proved unilateral 81–100% carotid stenosis by angiography were evaluated retrospectively. These patients ranged in age from 58 to 82 years (17 men, six women). Indications for duplex sonography included clinical suspicion of carotid artery disease (21) or preoperative screening for significant coronary or peripheral atherosclerosis (two).

Received June 27, 1989; revision requested October 2, 1989; revision received March 12, 1990; accepted March 12, 1990.

Presented at the annual meeting of the American Society of Neuroradiology, Orlando, March 1989.

[1] All authors: Department of Radiology, Section of Neuroradiology, Emory University School of Medicine, 1364 Clifton Rd., N.E., Atlanta, GA 30322. Address reprint requests to P. C. Davis.

0195–6108/90/1105–1049
© American Society of Neuroradiology

Duplex sonography was performed on an Accuson scanner with a 5.0-mHz real-time-pulsed Doppler transducer in 16 patients and a Quantum 7.5- and/or 5.0-mHz color real-time-pulsed Doppler transducer in seven patients. The sonographic study was always performed before the angiographic study, with a mean time interval between the two of 10 days (range, 0–42 days).

Standard duplex techniques included real-time imaging in the sagittal and transverse planes and multiple Doppler velocity measurements throughout each vessel. The Doppler angle of incidence was assigned parallel to the direction of blood flow in the portion of the vessel under evaluation, and was always less than 70°. Peak systolic and diastolic velocity data were recorded in the common carotid artery (CCA), internal carotid artery (ICA), and external carotid artery (ECA), and pre-, at, and poststenosis. Peak systolic velocity ratio was defined by Bluth et al. [3] as the peak velocity in systole at the ICA point of maximum stenosis divided by the peak velocity in the CCA 1 cm or more below the bifurcation. Percent stenosis by diameter was determined from real-time images by measuring plaque width relative to vessel diameter. Vessel tortuosity and shadowing plaque were noted.

Criteria for duplex sonography quantification of degree of stenosis are charted in Table 1 (Zweibel and Dreisbach, paper presented at RSNA, 1986) [3, 4].

Angiographic evaluation was performed by using selective intra-arterial digital subtraction arteriography in 20 patients and biplane magnification cut-film angiography in three patients. Angiographic interpretation included location of plaque, percent stenosis by diameter based on the ratio of the greatest diameter of the plaque to the normal diameter distal to the lesion, the presence and direction of vertebral artery flow, and the presence and direction of cross filling intracranially via the circle of Willis. Percent stenosis by diameter was estimated to the closest tenth percentile.

Images obtained by duplex sonography and angiography were interpreted separately and independently by an experienced observer. Studies were considered to agree if the diagnostic range demonstrated by duplex sonography included the percent stenosis by diameter determined by angiography.

Results

In 11 (48%) of 23 patients, the duplex sonographic and angiographic interpretation agreed. The degree of stenosis determined by duplex sonography was overestimated in nine (39%) and underestimated in three (13%) compared with angiographic findings. Data were calculated both by using the peak systolic velocity ratio with the peak end diastolic velocity (Table 1) and by the ratio between the peak systolic velocity at the lesion and the peak systolic velocity just proximal to the lesion within the ICA with the peak end diastolic velocity. The results obtained from both velocity ratio measurements were identical, as noted above.

TABLE 1: Quantification of Degree of Stenosis by Duplex Sonography*

SVR[a] < 1.5	<50% stenosis by diameter (rely on real-time measurements in orthogonal planes)
SVR ≥1.5 and SVR <1.8	50–60% stenosis by diameter
SVR ≥1.8 and PEDV[b] <100 cm/sec	61–80% stenosis by diameter
SVR ≥1.8 and PEDV ≥100 cm/sec	81–99% stenosis by diameter
No Doppler shift	"String" (99%) stenosis or occlusion

* Criteria adopted from Zweibel and Dreisbach (paper presented at RSNA, December 1986) and Bluth et al. [3].

[a] SVR (systolic velocity ratio) is defined as the peak systolic velocity within the ICA at the point of maximum stenosis divided by the peak systolic velocity within the CCA, 1 cm or more below the bifurcation.

[b] PEDV (peak end diastolic velocity) is defined as the maximum velocity at end diastole.

The presence or absence, and direction of cross filling angiographically via the circle of Willis are charted in Table 2.

The majority of patients in each category demonstrated bilateral vertebral artery patency, as reported in Table 2. Unilateral vertebral patency was noted in three of 11 patients in the duplex sonography/angiography agreement category, in one of three patients with duplex sonography underestimation, and in one of nine patients with duplex sonography overestimation. Subclavian steal was present in one patient in the duplex sonography overestimation category.

Recognizable causes for falsely elevated velocity ratios were found in two of nine patients. These included marked vessel tortuosity confirmed at angiography (one patient) and poorly visualized distal ICA stenosis, which resulted in inaccurate Doppler angle assignment (one patient). Of the remaining seven patients, no apparent explanation was found for the elevated velocity ratio measurements (Figs. 1 and 2). A case-by-case display of this data is found in Table 3.

The three patients in whom the degree of stenosis was underestimated by duplex sonography include: one patient with a 30% proximal ICA stenosis by sonography, and a 50% stenosis at angiography; one patient with the peak systolic velocity ratio of 2.91 and peak end diastolic velocity of 60 cm/sec, placing the patient in the 61–80% stenosis category (however, angiography demonstrated a 90% ICA lesion); and one patient with a 61–80% lesion by duplex sonography but a 90% lesion on angiography.

Discussion

Velocity ratio measurements are an essential component of duplex sonography in the assessment of the degree of stenosis of the carotid arteries. These depend on accurate Doppler angle selection and sample volume placement, as well as adequate signal-to-noise ratio. The angle between the axis of the ultrasound beam and the long axis of the vessel studied must be less than 70° to assure an accurate velocity measurement. Accurate angular correction is achieved by manually assigning the angle of incidence of the Doppler beam relative to the direction of blood flow in the vessel. Finally, the sample volume gate should be centered within the blood vessel in order to encompass the entire laminar distribution of velocities for flow data [5].

Known causes of falsely low velocity measurements resulting in quantitative errors in stenoses include: (1) an angle greater than 70° between the ultrasound beam axis and the vessel; (2) suboptimal visualization of the vessel in question (or marked attenuation of the Doppler signal) resulting from

TABLE 2: Correlation Between Findings on Duplex Sonography and Angiography

	Cross-Filling Toward the Side of Greater Stenosis	No Cross-Filling	Cross-Filling Away from the Side of Greater Stenosis	Bilateral Antegrade Vertebral Flow
Duplex sonography overestimate (9)	4	5	0	7
Duplex sonography/angiography agreement (11)*	6	3	1	8
Duplex sonography underestimate (3)	1	1	1	2

* One patient in this category did not undergo evaluation of the intracranial vessels.

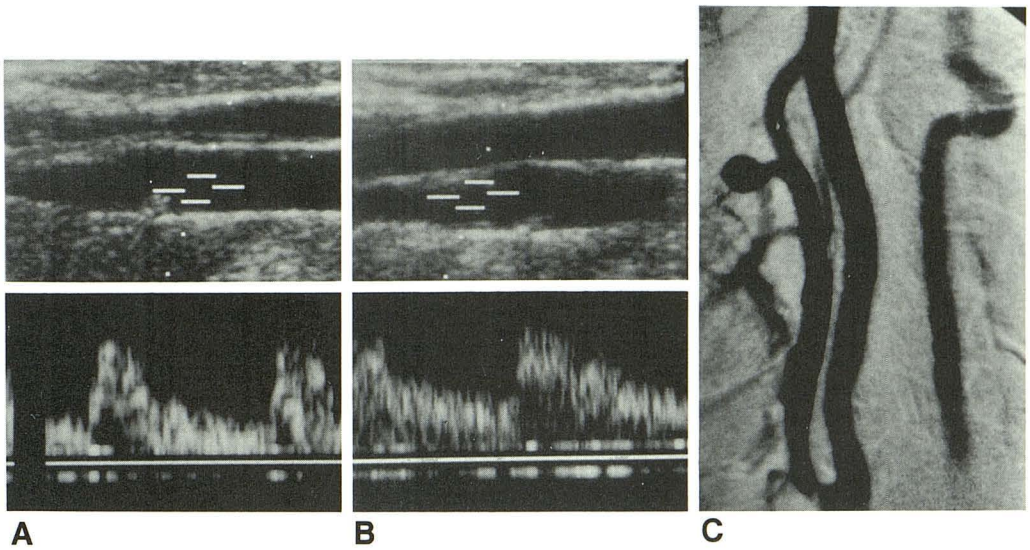

Fig. 1.—*A* and *B*, Distal CCA and proximal ICA duplex sonography images in a patient with an SVR of 2.2 (maximum systolic velocity in the ICA [*B*] divided by maximum systolic velocity in the CCA [*A*]), and a PEDV of less than 100 cm/sec, place the patient in the 61–80% stenosis category.

***C*, Carotid digital angiogram demonstrates 20% stenosis, indicating gross overestimation by duplex sonography. This patient did have collateral cross filling toward the side of greater stenosis, but no other explanation for the false "jet effect" with sonographic or angiographic evaluation could be found.**

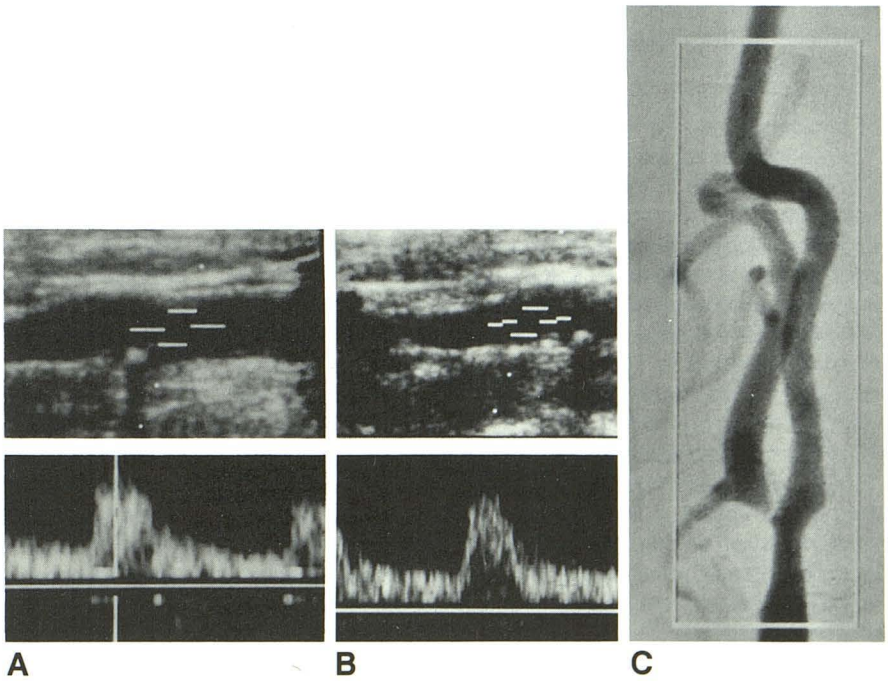

Fig. 2.—*A* and *B*, Representative duplex sonography images with an SVR of 2.0 and a PEDV equal to 36 cm/sec indicate a 61–80% lesion.

***C*, Angiogram shows a 50% CCA/ICA lesion and high-grade ECA stenosis. This is an example of mild duplex sonography overestimation.**

TABLE 3: Duplex Sonography Findings Correlated with Angiography Findings in the Duplex Sonography Overestimation Group

Case No.	Side	SVR	PEDV (Cm/Sec)	% Stenosis by Duplex Sonography	% Stenosis by Angiography	Vertebral Patency by Angiography	Cross-Filling via Circle of Willis	Comments
1	Right	3.10	42	61–80	50	Antegrade	None	
2	Right	2.31	30	61–80	20	Antegrade	Right to left, MCA, ACA	Tortuous vessels on both real-time and angiography images
6	Right	2.17	50	61–80	10	Antegrade	Right to left, ACA	
7	Left	2.08	30	61–80	30	Subclavian steal	Left to right, ACA, MCA	
13	Right	1.94	33	61–80	10	Antegrade	None	Real-time images high in ICA, difficult to image
16	Left	2.73	43	61–80	50	Antegrade	None	
18	Left	1.80	36	61–80	50	Antegrade	None	
22	Right	1.64	35	50–60	30	Antegrade	Right to left, ACA	
23	Left	1.50	33	50–60	20	Antegrade	None	

Note.—SVR = systolic velocity ratio, PEDV = peak end diastolic velocity, MCA = middle cerebral artery, ACA = anterior cerebral artery, ICA = internal carotid artery.

such factors as depth or inaccessibility; and (3) multiple or serial stenoses (Zweibel WJ, Stavros AT. Paper presented at annual meeting of RSNA, December 1988).

Causes of falsely high velocities include erroneous assignment of an angle of incidence that is wider than the actual angle of incidence. This is evident upon review of the equation used to calculate such velocities:

$$V = FC/(2F_0 \cos \theta)$$

where V represents the velocity of the flowing blood, F is the Doppler frequency shift, C is the speed of sound in tissue, F_o is the frequency of the transducer, and θ is the angle of incidence of the Doppler beam relative to the direction of blood flow [5]. If θ is assigned in error as too great an angle, the velocity is overestimated. Practically, this occurs in studies of tortuous vessels in which it is difficult to set the angular correction to reflect the true direction of blood flow throughout a sharp curvature in the vessel. Simultaneous real-time imaging is helpful in identifying tortuosity and, thus, in preventing spurious velocity values. Additional sources of error in evaluation of lesions in the distal ICA include interference from the mandible, shadowing plaques, and vessel depth.

Intracranial collateral flow via the circle of Willis toward the cerebral hemisphere supplied by a significantly stenosed/occluded ICA has been implicated as a cause of the false "jet effect" in the more widely patent ICA (Zweibel WJ, Stavros AT. Paper presented at annual meeting of RSNA, December 1988). Flow equals velocity multiplied by the cross-sectional area of the vessel. If flow increases with a constant cross-sectional area (i.e., due to contralateral occlusion), then velocity must increase, resulting in a falsely elevated systolic velocity ratio. Other authors have anecdotally described examples of accelerated velocity in the absence of angiographically identifiable stenosis contralateral to a tight lesion [1, 2]. In this study, angiographic evidence of intracranial cross filling via the circle of Willis was equally common in patients with and without accurate duplex sonography studies. Superficially, this suggests that this explanation for error is overly simplistic. It is reasonable to suspect, however, that angiographic demonstration of cross filling via the circle of Willis is a relatively insensitive index of collateral flow. Xenon CT or radionuclide studies (single proton emission CT [SPECT] or positron emission tomography [PET]) more accurately reflect cerebral perfusion; thus, these studies might provide additional insight as to the cause of falsely elevated velocity ratios in our patients. Unfortunately, these studies are not routinely performed in patients thought to have carotid stenosis. Vertebral artery patency and antegrade flow as potential sources of collateral intracranial flow similarly correlated poorly with our duplex sonography results, since most patients in all categories demonstrated bilateral antegrade flow.

In summary, quantitation by duplex sonography of the degree of stenosis in the carotid artery contralateral to a high-grade or occluded ICA is more prone to error than duplex sonography in general, with the error generally resulting in an overestimation of the degree of stenosis actually present. This potential source of error should be anticipated contralateral to a high-grade stenosis, and the performance of angiography considered to most accurately assess the extent of carotid vascular disease. A possible explanation for the error is increased flow caused by intracranial cross filling to the contralateral hemisphere; however, this could not be confirmed by angiographic data.

Conversely, observation of a velocity increase or "jet effect" out of proportion to real-time vessel characteristics should prompt a careful sonographic search for high-grade stenosis of the contralateral ICA.

ACKNOWLEDGMENTS

We gratefully acknowledge the expert assistance of Roz Vecchio (photography), Francine Hollowell (manuscript preparation), and our referring physicians.

REFERENCES

1. Satiani B, Porter R, Biggers K, Burns R. Evaluation of the color coded Doppler ultrasound in detecting carotid bifurcation disease. *J Cardiovasc Surg* **1988**;29:196–200
2. White DN, Curry GR. A comparison of 424 carotid bifurcations examined by angiography and the Doppler echoflow. In: White D, Lyons EA, eds. *Ultrasound in medicine*, vol 4. New York: Plenum Press, **1978**:363–376
3. Bluth EI, Stavros AT, Marich KW, Wetzner SM, Aufrichtig D, Baker JD. Carotid duplex sonography: a multicenter recommendation for standardized imaging and Doppler criteria. *RadioGraphics* **1988**;8:487–506
4. Dreisbach JN, Seibert CE, Smazal SF, Stavros AT, Daigle RJ. Duplex sonography in the evaluation of carotid disease. *AJNR* **1983**;4:678–680
5. Nelson TR, Pretorius DH. The Doppler signal: where does it come from and what does it mean? *AJR* **1988**;151:439–447