

Are your **MRI contrast agents** cost-effective?

Learn more about generic **Gadolinium-Based Contrast Agents**.



FRESENIUS
KABI

caring for life

AJNR

Treatment of arteriovenous malformations of the brain with combined embolization and stereotactic radiosurgery: results after 1 and 2 years.

R C Dawson, 3rd, R W Tarr, S T Hecht, C A Jungreis, L D Lunsford, R Coffey and J A Horton

This information is current as of May 13, 2024.

AJNR Am J Neuroradiol 1990, 11 (5) 857-864
<http://www.ajnr.org/content/11/5/857>

Treatment of Arteriovenous Malformations of the Brain with Combined Embolization and Stereotactic Radiosurgery: Results After 1 and 2 Years

Robert C. Dawson III^{1,2}
 Robert W. Tarr^{1,3}
 Stephen T. Hecht^{1,4}
 Charles A. Jungreis^{1,4}
 L. Dade Lunsford^{1,4}
 Robert Coffey^{1,4}
 Joseph A. Horton^{1,4}

Seven patients with large arteriovenous malformations (AVMs) of the brain were selected for combined therapy with particulate embolization, followed by radiosurgery of the residual nidus. The goal of embolization was to reduce the patient nidus to a size that facilitated successful stereotactic radiosurgery. Angiograms obtained 1 and 2 years after radiosurgery were evaluated for changes in nidus size, flow rate, and feeding and draining vessels. One year after stereotactic radiosurgery, one AVM was angiographically undetectable. Three other AVMs demonstrated a volume reduction of greater than 50%, in addition to decreased shunt speed and altered angioarchitecture at 1-year follow-up. At 2-year follow-ups, two of seven AVMs were cured, and an additional two of seven had a greater than 98% reduction in nidus volume. Although one patient experienced a transient deficit from embolotherapy, none of our patients suffered a new neurologic deficit or a hemorrhage during the follow-up period.

Our data support the efficacy of combined embolotherapy and radiosurgery for definitive therapy of selected large AVMs of the brain.

AJNR 11:857-864, September/October 1990

The efficacy of intersecting-gamma-beam radiosurgical treatment of arteriovenous malformations (AVMs) has been demonstrated. Although first described in 1951 by Leksell [1], modifications of the stereotactically focused method by Steiner et al. in 1970 [1-4] allowed treatment and extended follow-up of a large number of patients with intracranial AVMs. The physical characteristics of the original 179-source cobalt-60 (⁶⁰Co) gamma unit of Steiner limited the maximum diameter of the treated AVM nidus to 28 mm or less, but statistical evaluation of data, including larger lesions as well as those 28 mm or smaller, shows an overall 2-year cure rate of 84% [2].

In 1987, we installed a modified version of the original ⁶⁰Co gamma unit of Steiner. This unit uses 201 ⁶⁰Co sources and has improved computer-targeting capabilities. However, lesions larger than approximately 34-36 mm in maximum diameter still present formidable problems for safe and accurate isodose coverage [4]. Evaluation of subsets of these larger lesions is currently under way (Steiner L, personal communication).

By combining partial embolization of AVMs with radiosurgery of the remaining nidus, we postulated that we could obtain cures in patients who otherwise would not be candidates for radiosurgery alone. We present 1- and 2-year follow-up results of the initial seven patients treated with the combined approach.

Materials and Methods

Seven patients (four men and three women 25-57 years old) were referred for angiographic evaluation and staged embolization of AVMs before stereotactic radiosurgical therapy. The average greatest diameter of the nidus before embolization was 41.1 mm (range, 35-58 mm). Biplane magnification angiography of the supplying vessels was performed. Rapid filming

Received July 17, 1989; revision requested September 11, 1989; revision received February 23, 1990; accepted March 5, 1990.

¹ Department of Radiology, University of Pittsburgh, Presbyterian-University Hospital, Pittsburgh, PA 15213.

² Present address: Department of Radiology and Radiological Sciences, Vanderbilt University Medical Center, Nashville, TN 37232-2675. Address reprint requests to R. C. Dawson III.

³ Present address: Department of Radiology, University Hospitals of Cleveland, Case Western Reserve University, 2074 Abington Rd., Cleveland, OH 44106.

⁴ Department of Neurosurgery, Presbyterian-University Hospital, Pittsburgh, PA 15213.

0195-6108/90/1105-0857

© American Society of Neuroradiology

sequences (four or six per second for 3 sec) depicted the angioarchitectural details of supplying vessels. Planning of superselective embolization was based on the expected difficulty in catheterizing the respective feeding pedicles; the expected size reduction was based on the sacrifice of those pedicles.

During the embolization procedure, a 2.4-French Tracker-18 catheter (Target Therapeutics, Inc., Los Angeles, CA) was introduced coaxially through the diagnostic angiography catheter. The Tracker catheter was advanced superselectively into the feeding pedicles over a 0.016-in. (0.04-cm) steerable guidewire. The real-time digital fluoroscopic subtraction angiographic road-mapping technique was used for guidance. When a feeding pedicle was entered, digital subtraction angiography was performed to ensure that normal parenchyma was not also supplied by the pedicle. In addition, 20–75 mg of amobarbital sodium (depending on the size and flow rate of the pedicle) were administered through the in-dwelling Tracker catheter, and a tailored neurologic examination was performed. The development of a new neurologic deficit absolutely precluded embolization from that catheter position. Once a safe catheter position was confirmed by provocation with amobarbital sodium, particulate embolization was performed. Embolic materials included either polyvinyl alcohol (PVA) particles or silk suture material or both. Silk suture was used when large arteriovenous shunts within the nidus precluded occlusion with PVA. Embolic materials were suspended in iodinated contrast material to allow continuous real-time subtracted fluoroscopic control of the embolization [5]. We used periodic digital subtraction angiography to monitor shunt speed and detect normal vessels. If normal vessels were visualized during real-time digital subtraction angiography, amobarbital sodium provocation was repeated.

Embolization of a pedicle was terminated when flow to the AVM was reduced significantly or became stagnant. Staged pedicle embolization was performed with the goal of maximally reducing the nidus size while maintaining an adequate margin of safety. To guard against the development of normal perfusion pressure breakthrough secondary to major changes in the hemodynamics of the lesion, we used restraint in decreasing the volume of the lesion during any one embolization session. Most patients had several embolization sessions. At the completion of the embolization procedure, an angiogram was obtained with radiopaque sizing rings taped to the patient's scalp. Patients were maintained on corticosteroids for 48 hr after embolization and were monitored in a dedicated neurosurgical nursing unit.

Stereotactic radiosurgery was performed 1–3 months after completion of staged embolization. A stereotactic head frame was affixed to the patient's head for the radiosurgical procedure, and biplane angiography was performed to allow coordinate computation. Radiation was administered according to precalculated, individualized isodose curves.

One-year follow-up angiography was performed in each patient. In addition, 2-year follow-up angiograms were available for evaluation in four patients. Preembolization, postembolization, and postradiosurgery AVM volumes were estimated for each patient using the formula for a prolated ellipse, with correction for varying geometric magnification factors. The percentages of AVM volume reduction by embolization and stereotactic radiosurgery were also calculated for each patient.

Results

AVM characteristics, embolization details, AVM volume reduction data following embolization, and stereotactic radiosurgery follow-up data are presented in Table 1. The pre-

TABLE 1: Clinical, Embolization, and Radiosurgical Details of Patients Treated for Arteriovenous Malformations

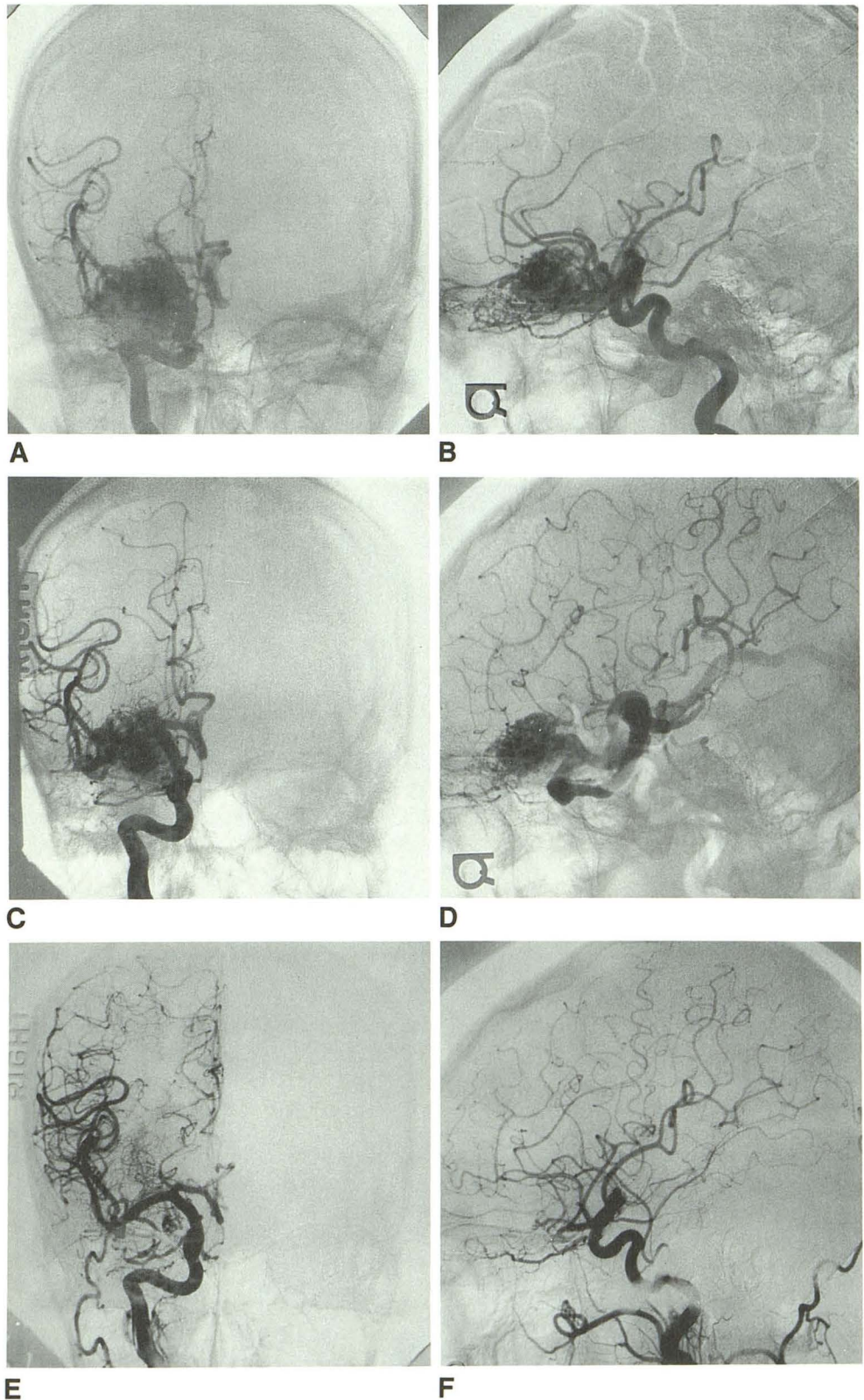
Case No.	Age (years)	Sex	AVM Location	Symptoms	Supply Embolized	Embolization Material	Greatest AVM Diameter (mm)		% Volume Change		
							Preembolization	Postembolization	Postembolization	1 Year Postembolization	2 Years Postembolization
1	42	M	R frontal	Seizures	R ACA branches	PVA	35	27	-22.0	-100.00	NA
2	38	F	R temporal	Headaches	R MCA branches	PVA/silk	35	31	-10.0	-88.4	-98.8
3	50	F	L frontoparietal	Hemorrhage	L pericallosal	PVA	48	36	-13.1	-7.2	NA
4	25	M	R parietal	Headaches/seizures	R MCA branches	Silk	37	32	-15.9	-57.4	-98.4
5	57	M	R temporal	Hemorrhage/seizures	R MCA branches	PVA	35	24	-39.2	-82.9	-100
6	36	F	L temporo-parietal	Hemorrhage/Aphasia/R hemiparesis	R MCA branches	Silk	40	34	-23.0	+11.9	NA
7	36	M	L occipital	Hemorrhage	L PCA branch	Silk	58	50	-42.2	-2.8	-9.8

Note.—R = right; L = left; ACA = anterior cerebral artery; MCA = middle cerebral artery; PCA = posterior cerebral artery; PVA = polyvinyl alcohol; NA = not available.

Fig. 1.—Case 1. *A* and *B*, Anteroposterior (*A*) and lateral (*B*) right internal carotid artery angiograms before embolization show right frontal arteriovenous malformation (maximum nidus diameter preembolization, 35 mm).

C and *D*, Anteroposterior (*C*) and lateral (*D*) right internal carotid artery angiograms after embolization of right orbitofrontal supply with polyvinyl alcohol show 22% volume reduction in nidus size (maximum nidus diameter postembolization, 27 mm).

E and *F*, Anteroposterior (*E*) and lateral (*F*) right internal carotid artery angiograms 1 year after stereotactic radiosurgery show complete obliteration of nidus.



senting symptoms included hemorrhage ($n = 4$), seizures ($n = 3$), hemiparesis ($n = 1$), headaches ($n = 2$), and aphasia ($n = 1$). Three patients had more than one symptom. Two AVMs were located in the temporal lobe. One AVM was

located in each of the following lobes: frontal, frontoparietal, temporoparietal, parietal, and occipital. The average greatest diameter of the nidus before embolization was 41.1 mm (range, 35–58 mm).

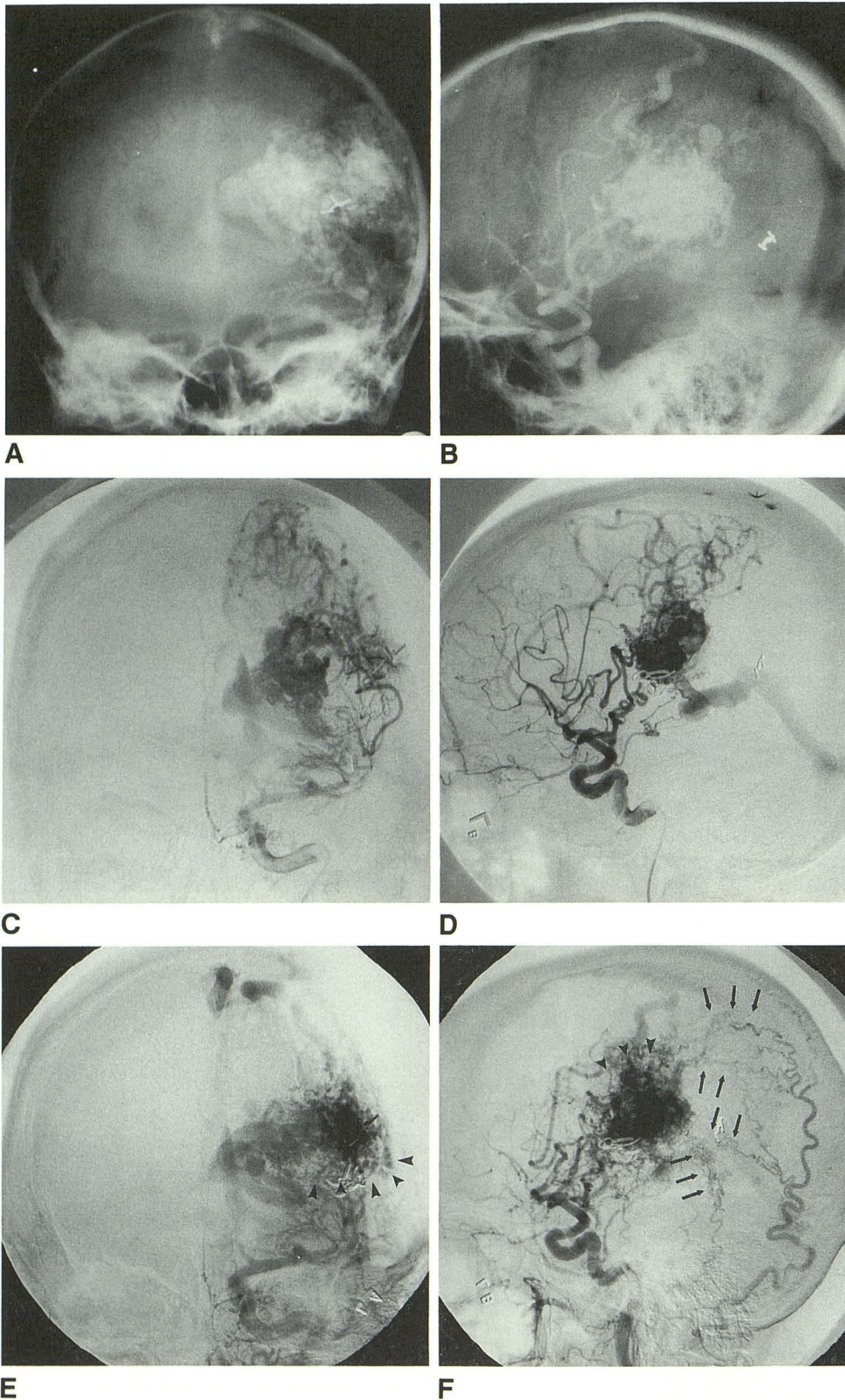


Fig. 2.—Case 6. *A* and *B*, Anteroposterior (*A*) and lateral (*B*) left internal carotid artery angiograms after left craniotomy from previous attempted resection of arteriovenous malformation (maximum nidus diameter preembolization, 40 mm).

C and *D*, Anteroposterior (*C*) and lateral (*D*) left internal carotid artery angiograms after embolization with silk alone show 23% reduction in nidus volume (maximum nidus diameter post-embolization, 34 mm).

E and *F*, Anteroposterior (*E*) and lateral (*F*) left common carotid angiograms 1 year after radiosurgery. Previously embolized portion of nidus has recanalized (arrowheads). Note recruitment of dural feeders (arrows).

Of the seven AVMs, three were embolized with PVA alone, three were embolized with lengths of silk suture, and one was embolized with a combination of PVA and silk. The average percent AVM volume reduction following emboliza-

tion was 23.6% (range, 10–42.2%). The average greatest diameter of the nidus after embolization was 33.4 mm (range, 24–50 mm). The rationale for attempting to radiosurgically treat the AVM whose diameter exceeded 36 mm following

embolization was based on symptom severity, surgical inaccessibility, and the inability to further embolize safely. One patient experienced a transient neurologic complication of embolization: A catheter perforation of an anterior choroidal artery resulted in a transient left hemiparesis. However, no permanent neurologic complications resulted from embolization.

One year after radiosurgery, an AVM volume reduction of greater than 50% was demonstrated in four patients. One of these AVMs, which had been embolized with PVA alone, was completely obliterated (Fig. 1). In three patients, minimal change in nidus volume was seen at 1-year follow-up. In one of these patients (case 6), whose AVM had been embolized with silk alone, a 12% increase in AVM volume was seen after 1 year (Fig. 2). Two-year follow-up angiograms were available for evaluation in four patients. Two years after radiosurgery, one additional AVM was cured (Fig. 3), two AVMs had greater than 98% volume reductions (Fig. 4), and one AVM showed little change when compared with preradiosurgical data.

Thus, the combined 1- and 2-year follow-up results were as follows: Two of seven AVMs were cured, two of seven AVMs showed greater than 98% volume reductions, and three of seven AVMs showed minimal changes in size. The average greatest diameter of the nidus (preradiosurgery) for those AVMs that had significant volume reduction was 29 mm (range, 24–32 mm). The average greatest diameter of the nidus (before radiosurgery) for those AVMs that showed minimal change was 40 mm (range, 34–50 mm).

One patient in whom medication compliance was questionable experienced an increased frequency of seizures after radiosurgery. No new neurologic deficits followed radiosurgery.

Angiograms of those patients whose lesions diminished demonstrated marked decrease in the diameter of the individual feeding vessel as well as the vessels within the nidus. Shunt speed was slowed markedly. These changes are thought to indicate progressive obliteration of the arteriovenous communications themselves and probably reflect proliferation of the vascular intima. Thus far, recanalization of the embolized nidus (Fig. 2) has been demonstrated in only one patient (case 6). This patient had a large AVM with a predominantly fistulous component that was embolized with silk alone. The portions of the remaining lesions that were embolized, but excluded from the irradiated field, have not recanalized.

Discussion

The therapy of cerebral AVMs has long been one of the more perplexing problems in medicine, compounded by the variability of their natural history [6, 7]. In selected cases, either surgical resection alone, or surgery combined with staged embolization, has generally been considered to be optimal therapy [8–16]. However, even with optimal case selection, the combined embolization/surgical therapeutic approach still has significant associated mortality and morbidity. In a series of 28 AVMs treated by combined embolization and surgical excision, the mortality rate was 3.6% and the mor-

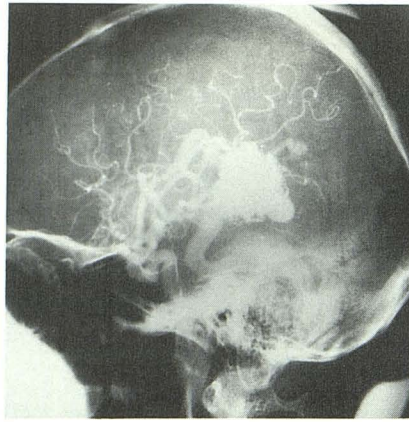
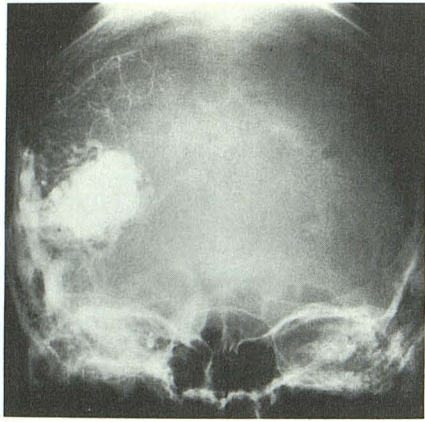
bidity rate was 17.9% [10]. In addition, some AVMs, such as those involving eloquent regions of the brain or those whose position prevents adequate surgical exposure, are not suitable for excision.

Stereotactic radiosurgical therapy of AVMs using either Bragg-Peak proton beams, helium ion beam, or convergent ⁶⁰Co gamma beams has met with a variety of success rates [17–21]. A 20% total obliteration rate during a 2- to 16-year follow-up period was reported by Kjellberg et al. [17] using Bragg-Peak proton-beam irradiation. At follow-up, 56% of the 75 patients in their series had greater than 50% reductions in AVM size at follow-up. Marks et al. [18] reported a 20% total obliteration rate at 1 year, a 50% total obliteration rate at 2 years, and a 55% obliteration rate at 3 years in their series of 20 high-flow AVMs treated with Bragg-Peak helium ion radiosurgery. However, new neurologic deficits developed in approximately 25% of their patients following radiosurgery [19]. More recently, Betti et al. [20] reported a total AVM obliteration rate of 66% after 2 years in a series of 41 patients treated with stereotactic radiosurgery using a linear accelerator. Success rates were much greater for lesions smaller than 25 mm in maximum diameter. After radiosurgery, new neurologic deficits developed in 3% of their patients. Data on 166 AVM patients treated with ⁶⁰Co stereotactic radiosurgery yielded a 34% total cure rate at 1-year follow-up and an 84% cure rate at 2-year follow-up [2]. In that series, a new neurologic deficit developed in 2% of patients following radiosurgery.

Defining the endpoint of embolization when treating AVMs can be difficult. In cases amenable to surgical excision, the goals of embolization are to reduce flow through the AVM nidus and through veins draining the nidus, to normalize pressures in pedicles feeding the AVM, and possibly to eliminate feeding pedicles that are surgically inaccessible. Rarely can AVMs be obliterated completely and permanently by embolization techniques alone [11]. In most cases, as the embolization proceeds, a critical point is reached, at which time the dynamics of flow shift away from the AVM and toward normal brain. At this point, the probability of injuring normal vessels and of inducing neurologic damage becomes significant.

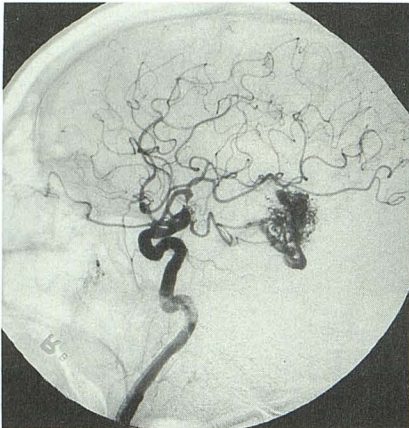
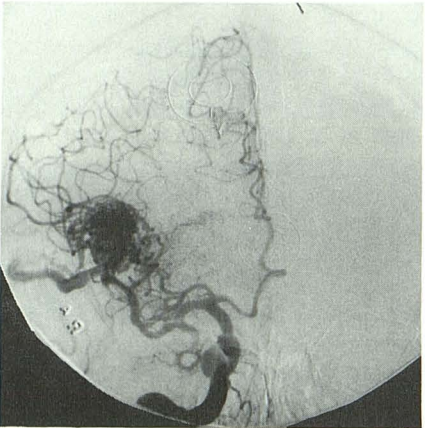
In our series, the endpoint of embolization was defined by the current limits of stereotactic radiosurgical technology, as well as by the safety margin of further attempted embolization. The goal of embolization was to reduce AVM size sufficiently to be amenable to radiosurgical therapy. Nonspherical lesions less than approximately 34–36 mm in maximum diameter were most amenable to stereotactic radiosurgery [4]. If greater reduction of AVM size could be achieved safely with embolization, that procedure was performed, since the success rate of stereotactic radiosurgery is greater with smaller AVMs [4]. The combination of superselective embolization and amobarbital sodium provocation imparts a desirable margin of relative safety, or at least a predictable risk of injury. A staged embolization approach guards against the development of the normal perfusion pressure breakthrough syndrome [22, 23].

Although the number of patients in our series is small, preliminary results of our combined embolization/stereotactic radiosurgery therapy are encouraging. Two of our seven



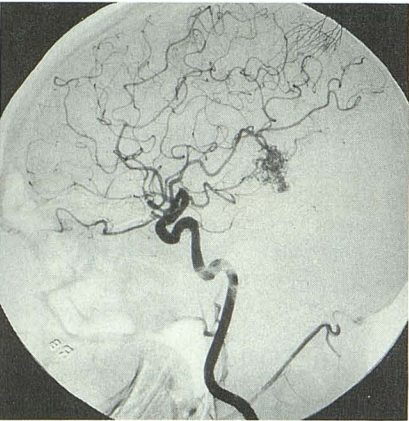
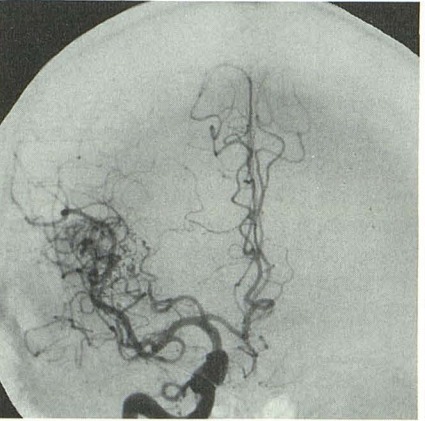
A

B



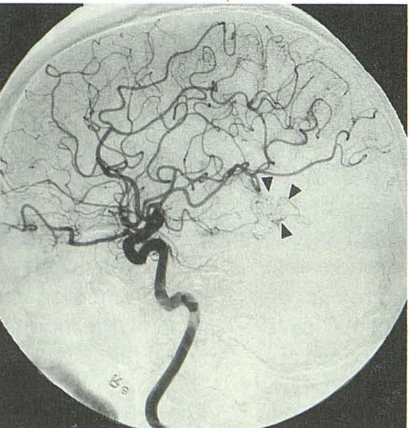
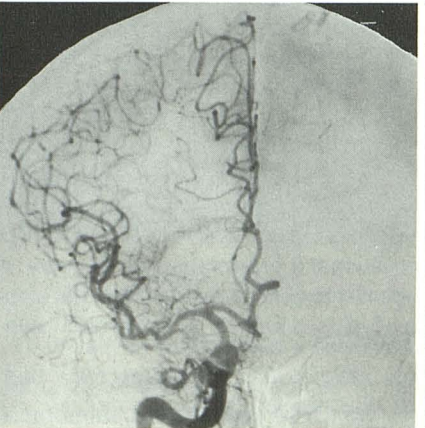
C

D



E

F



G

H

Fig. 3.—Case 5. A and B, Anteroposterior (A) and lateral (B) right common carotid angiograms before embolization (maximum nidus diameter preembolization, 35 mm).

C and D, Anteroposterior (C) and lateral (D) right internal carotid angiograms after embolization with polyvinyl alcohol show 39% reduction in nidus volume (maximum nidus diameter postembolization, 24 mm).

E and F, Anteroposterior (E) and lateral (F) right internal artery angiograms 1 year after stereotactic radiosurgery show 83% reduction in nidus volume. Note also decreased shunting through arteriovenous malformation.

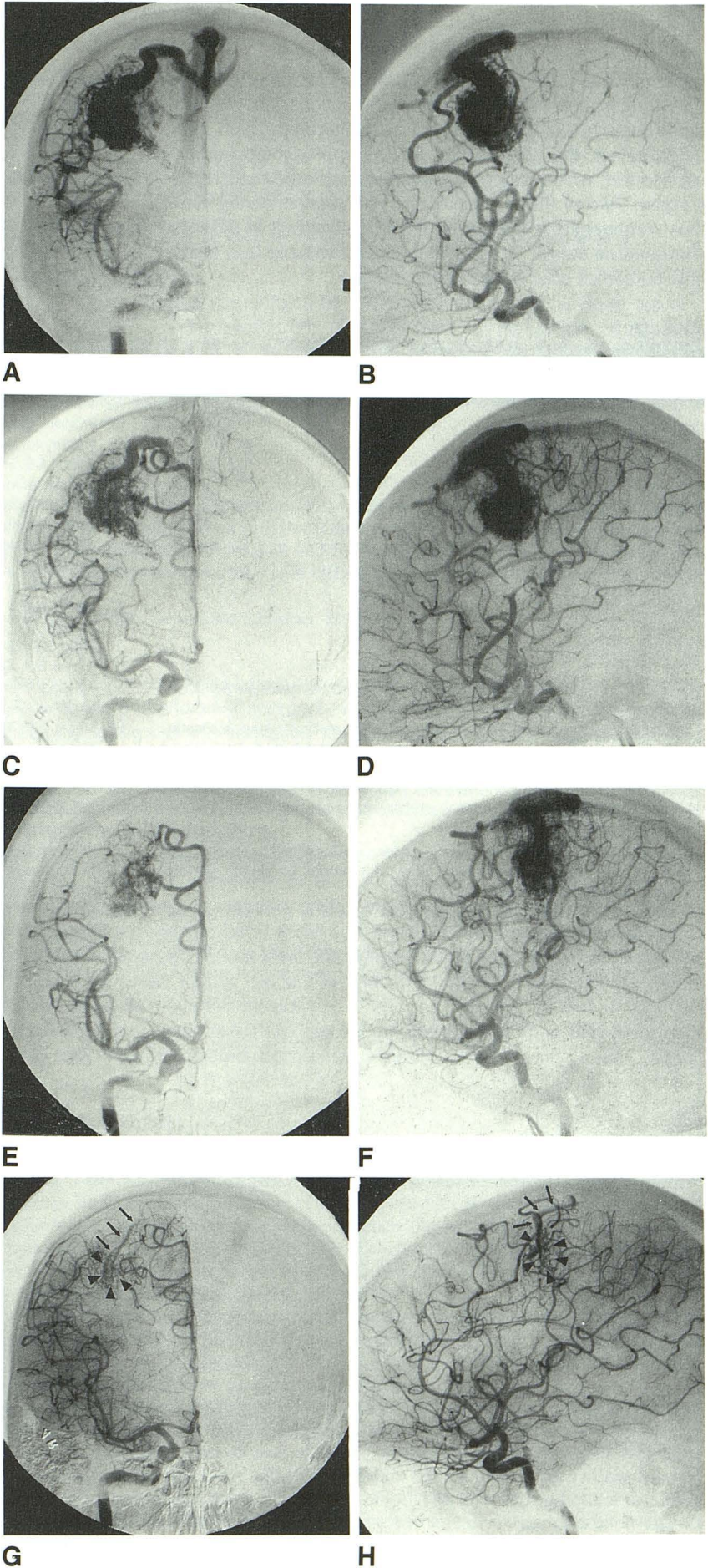
G and H, Anteroposterior (G) and lateral (H) right internal carotid angiograms 2 years after stereotactic radiosurgery show obliteration of nidus. Residual vascular irregularities in radiation port are best seen on lateral projection (arrowheads); however, there was no evidence of early venous drainage.

Fig. 4.—Case 4. *A* and *B*, Anteroposterior (*A*) and lateral (*B*) right internal carotid artery angiograms before embolization (maximum diameter preembolization, 37 mm).

C and *D*, Anteroposterior (*C*) and lateral (*D*) right internal carotid artery angiograms after embolization with silk show 16% reduction in nidus volume (maximum nidus diameter postembolization, 34 mm).

E and *F*, Anteroposterior (*E*) and lateral (*F*) right internal carotid artery angiograms 1 year after radiosurgery show 57% reduction in nidus volume.

G and *H*, 2 years after stereotactic radiosurgery there is greater than 98% reduction in nidus volume. Note residual nidus (*arrowheads*) and early draining vein (*arrows*).



patients were cured at 2-year follow-up. Two other patients had greater than 98% AVM volume reductions, and we presume their AVMs eventually will be obliterated. Even after embolization, the size of three AVMs approximated or exceeded that which is optimally treated by stereotactic radiosurgery. Two of these large AVMs with predominantly fistulous components were embolized with silk alone in order to eliminate the fistula. These AVMs tended to have less favorable outcomes after radiosurgical therapy.

In our experience, the combination of embolotherapy and stereotactic radiosurgery is relatively safe and shows great promise for the therapy of heretofore untreatable AVMs. As additional patients are examined and treated, and as improved embolization techniques are developed, we expect that cure rates can be improved.

ACKNOWLEDGMENTS

We thank Kelly Morris for secretarial assistance and Gwen Edwards for assistance with the radiosurgery patient files.

REFERENCES

1. Leksell L. The stereotaxic method and radiosurgery of the brain. *Acta Chir Scand* **1951**;102:316-319
2. Steiner L. Radiosurgery in cerebral arteriovenous malformations. In: Flamm E, Fein J, eds. *Textbook of cerebrovascular surgery*, vol. 4. New York: Springer-Verlag, **1986**:1161-1215
3. Steiner L. Treatment of arteriovenous malformations by radiosurgery. In: Wilson C, Stein B, eds. *Intracranial arteriovenous malformations*. Baltimore: Williams & Wilkins, **1984**:295-313
4. Lunsford DL, Fleckinger J, Lindner G, Maitz A. Stereotactic radiosurgery of the brain using the first United States 201 cobalt 60 source gamma knife. *Neurosurgery* **1989**;24:151-158
5. Kerber CW. Flow-controlled therapeutic embolization. A physiologic and safe technique. *AJR* **1980**;134:557-561
6. Leussenhop AJ. Natural history of the cerebral arteriovenous malformations. In: Wilson CB, Stein BM, eds. *Current neurosurgical practice. Intracranial arteriovenous malformations*. Baltimore: Williams & Wilkins, **1984**:295-313
7. Brown RD, Wiebers DO, Forbes G, et al. The natural history of unruptured intracranial arteriovenous malformations. *J Neurosurg* **1988**;68:352-357
8. Drake CG. Arteriovenous malformations of the brain: The options for management. *N Engl J Med* **1983**;309:308-310
9. Drake CG. Cerebral arteriovenous malformations. Considerations for an experience with surgical treatment in 166 cases. *Clin Neurosurg* **1979**;26:145-208
10. Stein BM, Wolpert SM. Surgical and embolic treatment of cerebral arteriovenous malformations. *Surg Neurol* **1977**;7:359-369
11. Viñuela F, Fox AJ, Pelz D, Debrun G. Angiographic follow-up of large cerebral AVMs incompletely embolized with isobutyl-2-cyanoacrylate. *AJNR* **1986**;7:919-925
12. Cromwell LD, Harris AB. Treatment of cerebral arteriovenous malformations: combined neurosurgical and neuroradiological approach. *AJNR* **1983**;4:366-368
13. Wolpert SM, Barnett FJ, Prager RJ. Benefits of embolization without surgery for cerebral arteriovenous malformations. *AJR* **1982**;138:99-102
14. Wilson CB, Hieshima GB. Preoperative balloon occlusion of arteriovenous malformations. *Neurosurgery* **1988**;22:301-308
15. Bank WO, Kerber KW, Cromwell LD. Treatment of intracerebral arteriovenous malformations with isobutyl 2-cyanoacrylate: initial clinical experience. *Radiology* **1981**;139:609-616
16. Andrews BT, Wilson CB. Staged treatment of arteriovenous malformations of the brain. *Neurosurgery* **1987**;21:314-323
17. Kjellberg RN, Hanamura T, Davis KR, et al. Bragg-Peak proton beam therapy for arteriovenous malformations of the brain. *N Engl J Med* **1983**;309:269-274
18. Marks MP, Delapaz RL, Fabrikant JI, et al. Intracranial vascular malformations: imaging of charged-particle radiosurgery. Part I. Results of therapy. *Radiology* **1988**;168:447-455
19. Marks MP, Delapaz RL, Fabrikant JI, et al. Intracranial vascular malformations: imaging of charged-particle radiosurgery. Part II. Complications. *Radiology* **1988**;168:457-462
20. Betti DO, Munari C, Rosler R. Stereotactic radiosurgery with the linear accelerator. Treatment of arteriovenous malformations. *Neurosurgery* **1989**;24:311-321
21. Kjellberg RN, Hanamura T, Davis KR, Lyons SL, Adams RD. Bragg-Peak proton-beam therapy for arteriovenous malformations of the brain. *N Engl J Med* **1983**;309:269-274
22. Spetzler RF, Wilson CB, Weinstein P, et al. Normal perfusion breakthrough theory. *Clin Neurosurg* **1978**;25:651-672
23. Barnett GH, Little JR, Ebrahim ZY, et al. Cerebral circulation during arteriovenous malformation operation. *Neurosurgery* **1987**;20:836-842