

Generic Contrast Agents

Our portfolio is growing to serve you better. Now you have a *choice*.



[VIEW CATALOG](#)

AJNR

Degenerative narrowing of the cervical spine neural foramina: evaluation with high-resolution 3DFT gradient-echo MR imaging.

D M Yousem, S W Atlas, H I Goldberg and R I Grossman

AJNR Am J Neuroradiol 1991, 12 (2) 229-236

<http://www.ajnr.org/content/12/2/229>

This information is current as
of May 5, 2025.

Degenerative Narrowing of the Cervical Spine Neural Foramina: Evaluation with High-Resolution 3DFT Gradient-Echo MR Imaging

David M. Yousem¹
 Scott W. Atlas
 Herbert I. Goldberg
 Robert I. Grossman

Conventional two-dimensional Fourier transform (2DFT) MR evaluation of osteophytic disease of the cervical neural foramina is limited by section thickness, signal-to-noise problems, and CSF flow artifacts. We evaluated the role of thin-section, high-resolution, gradient-refocused three-dimensional Fourier transform (3DFT) MR imaging in assessing degenerative foraminal narrowing in the cervical spine. Contiguous 1.5-mm axial 3DFT gradient-recalled acquisition in the steady state MR images of 120 neural foramina at 60 disk levels were evaluated blindly and independently by three neuroradiologists. High-resolution axial CT was used as the gold standard in all patients. 3DFT MR was found to agree with CT in the detection of neural foraminal narrowing and in the determination of the cause of the narrowing in approximately 76% of neural foramina. The accuracy for the assessment of neural foraminal narrowing on 3DFT MR ranged from 73% to 82% when a 5°-flip-angle, high-intensity CSF technique was used. When using the 30°-flip-angle, low-intensity CSF technique, the accuracy ranged from 66% to 86%. When the cause of narrowing was evaluated, the 5° and 30° studies agreed with CT in 70–92% and 48–88% of the levels, respectively. When lesions were missed on MR, it was usually because of osteophytic disease. The interobserver concordance of MR and CT interpretations was higher for detecting the presence of narrowing than its cause.

This MR technique is a useful method in the evaluation of foraminal stenosis since contrast between disk, cord, osteophyte, and CSF is high without the need for intrathecal injections. The wide range of interpreter accuracy and interobserver correlation is attributed to a steep learning curve for evaluating the MR images.

AJNR 12:229–236, March/April 1991; *AJR* 156: June 1991

While MR imaging has become a well-accepted method for evaluating spinal cord disease, its use in the cervical spine has been limited by its decreased effectiveness in evaluating bony degenerative disease. In patients with cervical radiculopathy, neural foraminal narrowing may be caused by degenerative osteophytes or laterally herniated disks. Bony osteophytic disease has not been depicted clearly by conventional two-dimensional Fourier transform (2DFT) MR techniques. The 2DFT images have been limited by section thickness, signal-to-noise (S/N) problems with thin sections, as well as artifacts emanating from CSF flow [1–4].

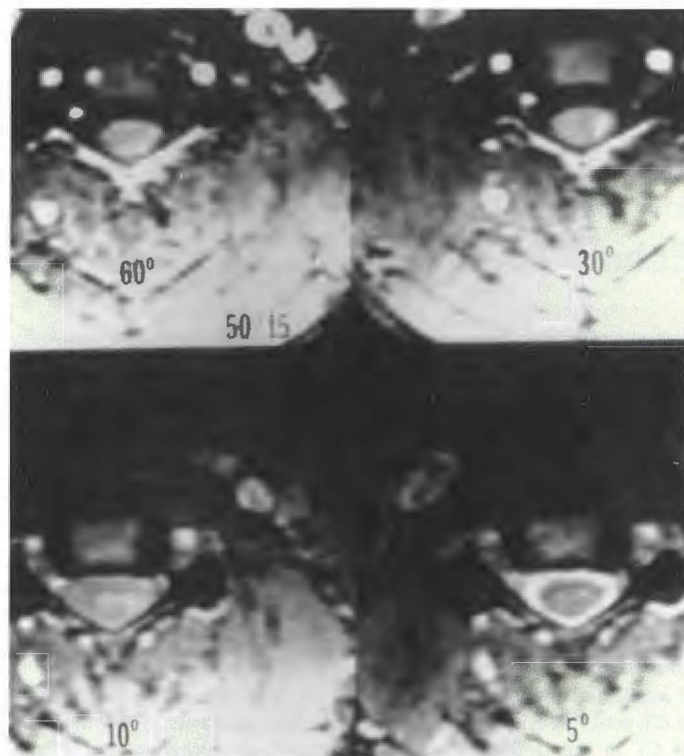
We evaluated the ability of thin (1.5 mm)-section, high-resolution three-dimensional Fourier transform (3DFT) MR imaging with gradient refocusing to assess foraminal disease of the cervical spine. Techniques resulting in high-intensity CSF (i.e., low flip angle) and low-intensity CSF (i.e., high flip angle) were compared by using high-resolution CT as the gold standard.

The object of this investigation was to evaluate the accuracy and interobserver reliability of 3DFT volumetric imaging of the neural foramina of the cervical spine relative to the imaging gold standard, high-resolution CT. We hoped to ascertain whether the perceived insensitivity of MR in bony disease persisted when a thin-section, high-resolution technique was used.

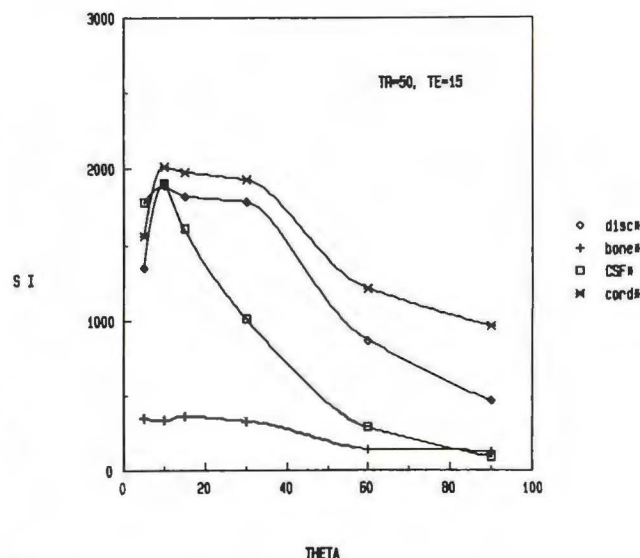
Received June 6, 1990; revision requested August 15, 1990; revision received September 6, 1990; accepted September 7, 1990.

¹ All authors: Department of Radiology, Neuro-radiology Section, Hospital of the University of Pennsylvania, 3400 Spruce St., Philadelphia, PA 19104. Address reprint requests to D. M. Yousem.

0195–6108/91/1202–0229
 © American Society of Neuroradiology



A



B

Fig. 1.—Evaluation of signal and contrast with a 3DFT volume gradient-echo series, 50/15, with varying flip angles at the same anatomic level. Window width and level are kept constant to demonstrate effect of variations in flip angle.

A, CSF-bone contrast is very high and CSF-cord contrast is high with 5° and 10° flip angles (bottom right and left, respectively); CSF is bright, but cord-CSF contrast at 10° is low. At 30° and 60° (top right and left, respectively), there is high CSF-cord contrast owing to dark-intensity CSF. Bone-CSF distinction decreases at 30° and 60°. Disk is high in intensity at all flip angles.

B, Graph of signal intensity (SI) vs 5°, 10°, 15°, 30°, 60°, and 90° flip angles shows maximum bone-CSF, bone-disk, and bone-cord contrast at 10°; however, disk, cord, and CSF are of similar intensity at this flip angle. The 5° sequence, which distinguishes between cord, CSF, and disk while maintaining high bone contrast, is preferable. The 30° sequence shows the highest CSF-cord and CSF-disk contrast, while maintaining high signal to noise, which drops off for all flip angles after 30° owing to saturation effects. CSF-bone contrast decreases with high flip angles.

Subjects and Methods

In order to determine the flip angle that would optimize contrast in the cervical spine, scans were obtained in a normal volunteer, varying the angle of nutation from 5° to 90° (Fig. 1A). The TR and TE were held constant at 50 and 15 msec, respectively (as were the receive and transmit attenuations), with gradient-moment nulling applied. Signal intensities of a region of interest in the CSF, spinal cord, disk, and vertebral body were determined for each flip angle (Fig. 1B). From this preliminary study, it was determined that a 5° flip angle produced high-intensity CSF, optimized CSF-bone contrast, and maintained CSF-cord differentiation. The 30° sequence generated low-intensity CSF and produced the greatest CSF-cord and CSF-disk contrast while maintaining high signal intensity in the cord and disk. These flip angles were selected for routine use on a 1.5-T General Electric Signa scanner. The minimum TE was selected, 11 msec for the 30° series and 15 msec for a flow-compensated 5° series; the TR was maintained at 50 msec. The TE of the 30° series was reduced to its minimum value to obtain the highest S/N and low-intensity CSF, and to minimize susceptibility artifacts. The TE of 15 msec for the 5° sequence was necessarily higher because gradient-moment nulling was added to obtain high-intensity CSF and to reduce CSF flow artifacts.

As part of the routine study of the cervical spine, we routinely obtain a sagittal 800/20–25/2 (TR/TE/excitations) scan with 3-mm contiguous slices. These images often, but not always, include the

neural foramina if the patient is not very scoliotic and localization is not a problem. For the purposes of this study, which was to evaluate the foramina on axial MR images comparable to axial CT scans, we did not use these images as part of the assessment. The sagittal 800/25 and the two axial 3DFT sequences described above make up the entire routine cervical spine protocol for degenerative disease at our institution.

Twenty-one patients referred to the neuroradiology section for evaluation of disk disease of the cervical spine underwent CT examination as well as 3DFT gradient-echo thin-section MR imaging using protocols determined from the normal volunteer study. One hundred twenty neural foramina were included in the cervical spine studies. The MR and CT scans were reviewed independently and blindly by three senior members of the American Society of Neuroradiology with extensive CT and MR experience. The evaluators were not provided with the patients' clinical symptoms. CT and MR scans were interpreted separately and randomly.

The evaluators were provided with high-resolution axial CT images of the neural foramina, which included 41 postmyelography 1.5-mm thin section levels, two postmyelography 3.0-mm section levels, and 17 unenhanced 3-mm section levels with two neural foramina at each level (120 neural foramina). The MR evaluations consisted of two separate series that used the 3DFT technique with gradient-recalled acquisition in the steady state, 1.5-mm contiguous sections, a 256 × 128 matrix, and one excitation. In one series the flip angle was 5° with a TR of 50 msec and TE of 15 msec (50/15/5°) and first-order

gradient moment nulling, which generated high-intensity CSF. The second series used parameters of 50/11/30° without gradient-moment nulling, which generated low-intensity CSF. Although 64 slices were obtained in the data set, only 60 1.5-mm contiguous sections were displayed because of aliasing artifacts.

All spinal levels that were evaluated by both CT and MR were included in this study. While MR scans routinely covered from C2–C3 to C7–T1 in a 60-slice series, the CT scans were selected on the basis of findings at myelography or by the request of the referring clinician. Thus, the CT levels determined which MR images were obtained for comparison. In this study, the reviewers evaluated four levels at C2–C3, seven levels at C3–C4, 12 levels at C4–C5, 16 levels at C5–C6, 17 levels at C6–C7, and four levels at C7–T1 (and two neural foramina at each level).

The evaluation of each neural foramen consisted of a numeric score of 0 (within normal limits or minimally narrowed) or 1 (moderately to severely narrowed). When the images were uninterpretable, they were called indeterminate. The indeterminate label was used when scans were technically suboptimal for foraminal visualization (either owing to aliasing, motion degradation, or metallic artifact) or when the evaluators believed there was insufficient contrast between CSF and bone and disk to determine confidently whether the neural foramen was narrowed or not. MR and CT standards were provided for the two grades (0 and 1) in order to obtain a uniform grading scale and to avoid individual biases (Fig. 2). Each individual interpreter's CT scans were evaluated in the same fashion. The CT interpretations were used as the gold standard with which to compare that evaluator's MR interpretations. Despite the fact that 1.5- and 3.0-

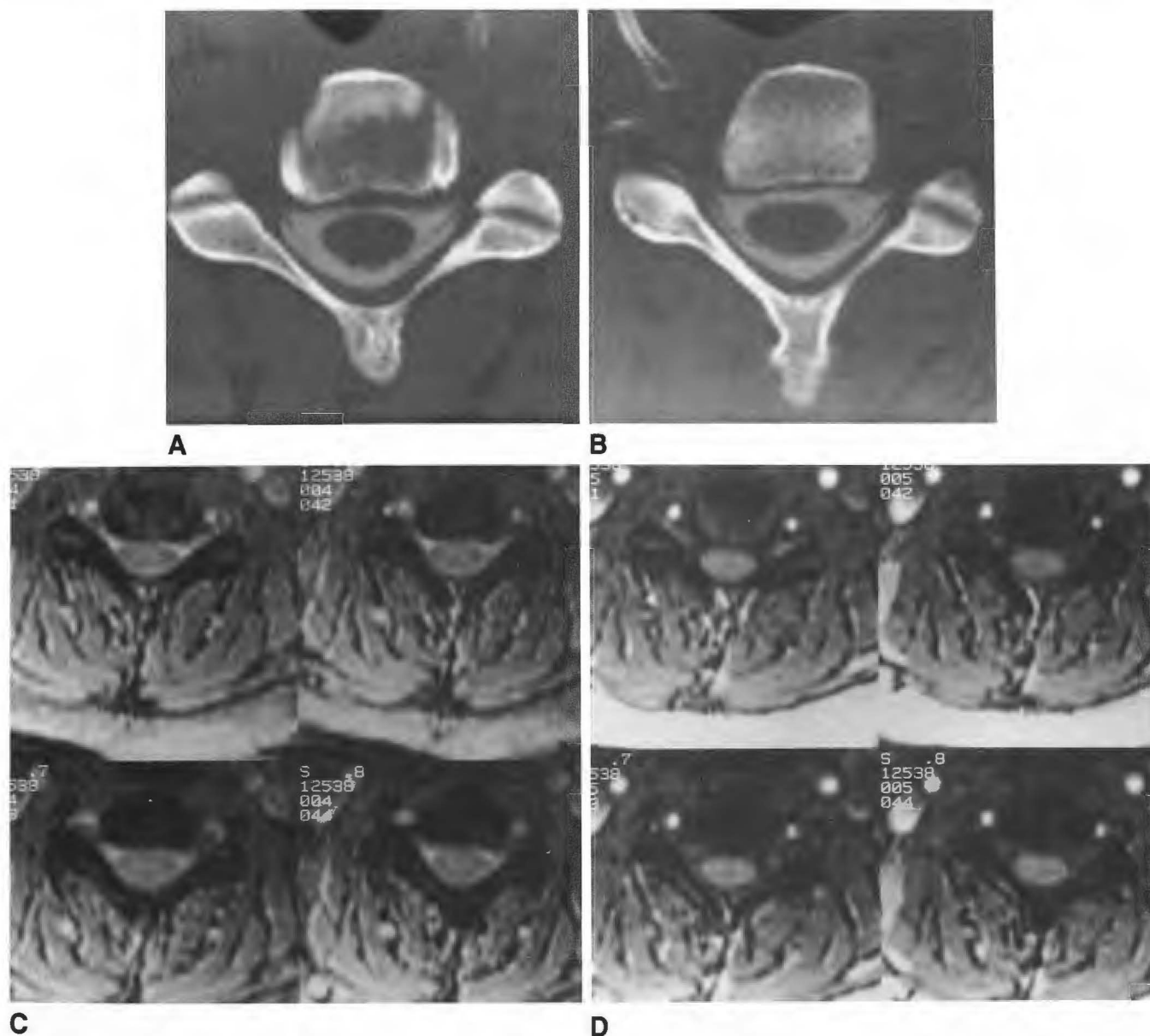


Fig. 2.—Example of grade 0 neural foramina in a 36-year-old woman.
A and B, Postmyelography CT images through the C4–C5 disk and foraminal level show normal neural foramina bilaterally.
C, Bright CSF 50/15/5° MR technique shows intermediate-intensity disk and nerve root sleeves, with lower-intensity cord and exiting nerve roots at the same level. Neural foramina are not narrowed.
D, At same level. Dark CSF 50/11/30° MR series shows intermediate-intensity disk and cord with lower-intensity CSF nerve root sleeves. Note lower degree of contrast in foramina between bone and CSF.

mm-thick sections and postmyelography and unenhanced CT studies were used as the gold standard, the results of the MR correlation did not vary for each subtype of CT technique (see Results), so using this "nonuniform" gold standard was justifiable.

Thin-section CT was used as the gold standard for several reasons: (1) patients without significant foraminal narrowing do not undergo surgery; (2) patients often are treated conservatively for radiculopathy; (3) from an anterior approach (the preferred operative technique at this institution for disk disease), the neural foramen cannot be

visualized directly, and histopathology cannot assess for the size of the neural foramen; (4) a surgical selection bias exists in favor of surgery in patients with disk herniation; and (5) determination of neural foraminal narrowing should be done preoperatively.

Each neural foramen, when scored as moderately or severely narrowed, was also assessed as to the cause of the narrowing on both CT and MR. The options for this part of the evaluation included bony narrowing, diskogenic narrowing, both bony and disk narrowing, or indeterminate or uninterpretable. The CT interpretations for the

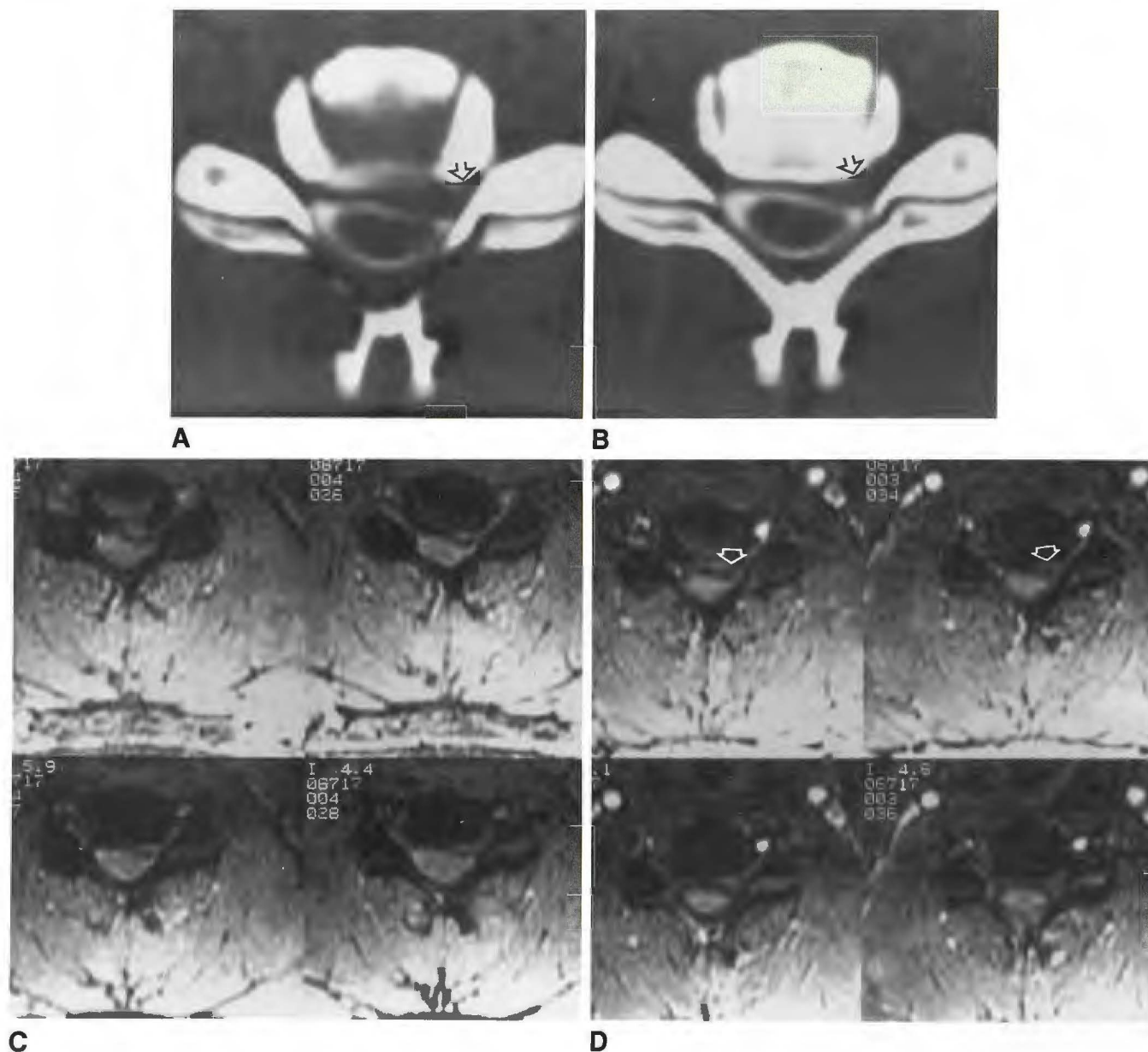


Fig. 3.—27-year-old man with left C5–C6 radiculopathy.

A and B, Postmyelogram CT scans through disk level (A) and at foramina (B) show left-sided, focally herniated disk (arrows) entering foramen. Two of three evaluators diagnosed herniated disk only and one diagnosed herniated disk and bony osteophyte as the cause of foraminal narrowing (on the basis of "hypertrophied" left Luschka joint seen better on a higher section). All examiners believed the foramen was narrowed.

C, High-intensity CSF MR technique shows intermediate-intensity disk material with low-intensity rim extending to left neural foramen. Bony neural canal in lower left image is narrowed laterally. Interpretation by two evaluators was bony osteophyte and herniated disk causing foraminal narrowing, while one evaluator diagnosed herniated disk alone.

D, Low-intensity CSF images show disk herniation (arrows) to left side. Hypointensity posterior to disk was believed to represent CSF and therefore was considered herniated disk by one examiner (not the same who considered it herniated disk on the high-intensity CSF series), but was considered bony osteophyte and herniated disk by the other two.

cause of the neural foramina narrowing were used as the proof of diagnosis for each independent observer's MR interpretation.

In order to evaluate interobserver concordance, the CT and MR grades of the neural foramina were compared for each level. If any one evaluator graded the narrowing as indeterminate on either CT or MR, the level was not included in the concordance figures for that observer. A similar analysis for interobserver concordance regarding the cause of narrowing was made. Again, levels labeled indeterminate were removed from the analysis of the evaluator who labeled the neural foramen as indeterminate.

One evaluator graded the CT scans twice (in two separate sessions) to determine intraobserver variation with a "proved" method.

Results

On the basis of each evaluator's own interpretation of the CT scans, the accuracy for the assessment of neural foramina narrowing in 3DFT MR ranged from 73% to 82% with the low-flip-angle, high-intensity CSF technique. When using the 30°-flip-angle, low-intensity CSF technique, the accuracy ranged from 66% to 86% (Table 1). No significant differences were noted in the CT-MR correlation values when 1.5- or 3-mm-thick CT images were interpreted. The average accuracy rate of the three evaluators when grading the MR images (combining 5° and 30° data) vs the 3-mm-thick CT sections was 74.2% and vs the 1.5-mm-thick CT slices was 77%.

The 5° MR series did not detect narrowing that was evident on CT in 27 studies, while the 30° series did not detect CT-documented narrowing in 41 neural foramina. Of 17 cases in which narrowing was seen on CT to be caused by disk herniation, MR was interpreted as normal in one instance (5.9%) on both the 5° and 30° series. In the 141 levels of CT-documented bony narrowing, the 5° MR series was interpreted as normal in 26 (18.4%) instances, while the 30° MR series was interpreted as normal in 40 (28.4%) instances (Table 2). No case of CT-documented bone and disk narrowing (15 instances) was interpreted as normal on MR.

When the interpretations on 5° MR and CT disagreed, the evaluators were twice as likely to consider foraminal narrowing on the 5° series when there was none by CT than they were to interpret the 5° MR as normal when CT showed foraminal narrowing. Thus, the average false-positive (i.e., CT negative, MR positive) rate for the three interpreters was 16.1% (15.3%, 11.7%, and 20.8% for evaluators 1, 2, and 3, respectively) for the 5° series. The average false-negative (i.e., CT positive, MR negative) rate was 8.0% (11.1%, 6.3%, and 6.7% for evaluators 1, 2, and 3, respectively) for the 5°

TABLE 1: Identification on MR of the Presence and Cause of CT-Verified Narrowing of Neural Foramina

Evaluator No.	Presence of Narrowing (%)		Cause of Narrowing (%)	
	5° Series	30° Series	5° Series	30° Series
1	74	66	70	48
2	82	86	73	76
3	73	78	92	88
Average	76	77	78	75

Note.—Although the variation in the evaluators' accuracy in interpreting the 30° series was wider than that of the 5° series, the two series had similar average accuracies with CT as the proof of diagnosis.

TABLE 2: Analysis of Discrepancies Between MR and CT Interpretations of the Cause of Neural Foraminal Narrowing

MR Series/Interpretation	CT Diagnosis		
	Bony Osteophyte (n = 141)	Disk Herniation (n = 17)	Combination (n = 15)
5°			
Bony osteophyte	0	2	4
Disk herniation	5	0	1
Combination	14	6	0
Normal	26	1	0
30°			
Bony osteophyte	0	3	10
Disk herniation	2	0	2
Combination	11	0	0
Normal	40	1	0

Note.—Interpretations of all three evaluators were combined; indeterminate interpretations were excluded. The "combination" diagnosis was used when both bony osteophytes and disk herniations were found.

TABLE 3: Number of Neural Foraminal Levels Uninterpretable on MR

Evaluator No.	MR Series	
	5°	30°
1	3	11
2	7	29
3	0	5
Total	10	45

Note.—All levels were interpretable on CT. The high number of indeterminate levels seen with the 30° technique was due to the lower contrast between CSF and bone, which caused decreased confidence in determining if bony protrusion existed in the neural foramen. Technical artifacts accounted for far fewer uninterpretable levels.

series. When the individual interpretations of the 30° series and CT disagreed, the evaluators overcalled foraminal narrowing with an average false-positive rate of 10.2% (9.1%, 7.5%, and 13.3% for evaluators 1, 2, and 3, respectively). The false-negative rate for the 30° series was 13.3% (24.5%, 6.5%, and 8.3% for evaluators 1, 2, and 3, respectively).

A marked difference was noted in the number of total indeterminate/uninterpretable examinations. For the three evaluators, no levels were deemed indeterminate on CT, 10 on the 5° series, and 45 on the 30° series (Table 3). This led to false elevation of the accuracy of the 30° values since the denominator for the ratios was lower with the 30° series (i.e., accuracy figures were calculated after omitting any case where an indeterminate score was given).

When the cause of the narrowing was evaluated, the 5° and 30° studies agreed with CT in 70–92% and 48–88% of the levels, respectively (Table 1 and Figs. 3 and 4). The most frequent disagreement occurred when narrowing on CT was reported to be due to osteophyte, but MR was reported as showing both bony and disk disease (Table 2). Of 141 instances when an evaluator interpreted the CT scan as showing osteophytic narrowing, the MR image was interpreted as showing both bony and diskogenic narrowing in 14 instances (9.9%) on the 5° series and in 11 instances (7.8%) with the 30° technique. The next most frequent error was when the CT scan was interpreted as showing bone and disk narrowing, but the MR image was interpreted as showing just bony encroachment.

Interobserver concordance in evaluating the foramina on the 5° series ranged from 77% to 90% for the presence of narrowing and 49% to 69% for its cause (Table 4). With the 30° series, interobserver concordance ranged from 66% to 81% for the presence of narrowing and from 70% to 78% for its cause. The range of interobserver concordance on CT was 81–87% for the presence of foraminal narrowing and 80–94% for the cause of narrowing.

In order to assess the highest expected level of accuracy obtainable with any neuroimaging study for cervical foraminal narrowing, we tested intraobserver concordance on CT, a method widely regarded as a proven tool for this entity. The

intraobserver concordance for evaluating the CT scans was 85.5% for the presence of and 94% for the cause of narrowing (interpreter 2).

Discussion

Initial MR studies evaluating the neural foramina were hindered by section thickness (≥ 4 mm) and interslice gap limitations [1–4]. This led to unfavorable comparisons with postmyelography CT in studies with surgical confirmation, particularly with regard to the evaluation of osteophytic neural foraminal stenosis [2–4]. MR interpretations with thick sec-

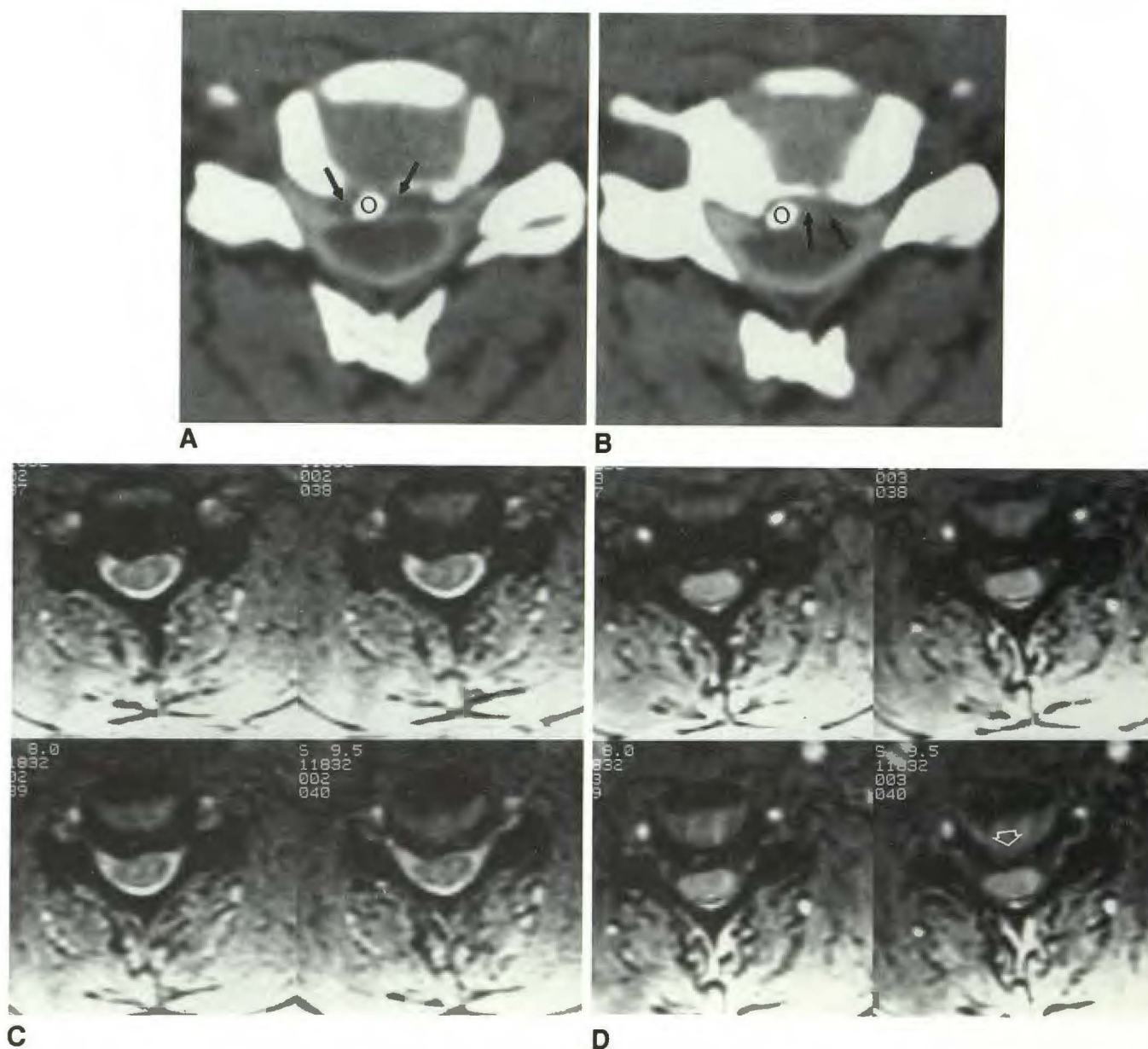


Fig. 4.—Postmyelogram CT and 3DFT MR in a patient with herniated disk and bony degenerative change. A and B, Postmyelogram CT images show minimal disk material (arrows) and dense osteophyte (o) projecting posteriorly and approaching cord surface. Neural foramen is not narrowed. C, 3DFT low-flip-angle images suggest mild right foraminal narrowing, predominantly due to osteophytic disease. D, Disk contribution to foraminal narrowing (arrow) is seen somewhat better on dark CSF higher-flip-angle series.

TABLE 4: Interobserver Concordance as to the Presence and Cause of Neural Foraminal Narrowing on MR and CT Images

Finding/ Evaluator Nos.	MR (%)		CT (%)
	5° Series	30° Series	
Presence of narrowing			
1 and 2	77	71	87
1 and 3	82	66	81
2 and 3	90	81	84
Average	83	73	84
Cause of narrowing			
1 and 2	49	70	82
1 and 3	63	74	80
2 and 3	69	78	94
Average	61	75	86

Note—Interobserver concordance was better on CT interpretations than on MR interpretations. This difference was most striking in examinations of the cause of neural foraminal narrowing.

tions typically underreported foraminal stenosis. Accuracy as to the cause of foraminal narrowing also has been reported to be less with MR than CT. The explanations for the relative inaccuracy of MR imaging included the variable presence of bone marrow within the osteophyte resulting in obscuration of spurs (being similar in intensity to disk material), osteophytes masking disk herniations, and volume averaging [2–4]. Because of these findings it is widely held that conventional spin-echo MR lacks specificity and sensitivity in evaluating bony foraminal disease. We sought to further explore this belief with the 3DFT pulse sequence.

With 3DFT gradient-echo imaging, an entire volume of tissue is excited and data are collected from the entire slab. Scan times are reduced by limiting TR, thus limiting patient motion artifacts, yet high S/N is maintained by obtaining data from an entire imaging slab [5–7]. In order to spatially encode the information, a phase-encoding gradient is applied both along slice-selection (z) axis as well as the in-plane phase-encoding (y) axis [5, 6]. By using a relatively short TR, many thin section slices can be obtained contiguously while maintaining a reasonable scan time. The benefits of 3DFT imaging derive from the ability to obtain thin, contiguous sections (which do not suffer significantly from cross-talk and partial-volume effects). Thinner sections reduce problems with volume averaging and reduce magnetic susceptibility artifacts. A distinguishing feature when compared with the two-dimensional sequential mode relates to the improvement in S/N when exciting a slab of tissue. Whereas in the 2DFT mode, the S/N is independent of the number of locations scanned, S/N in 3DFT increases as the square root of the number of slice encodings. Thus, the S/N is proportional to both the square root of the number of slices and the square root of the number of excitations. Therefore, for instance, by halving the number of excitations and doubling the number of slice encodings, the S/N remains unchanged. This permits increased coverage of pertinent anatomy without the penalty of lengthened acquisition times. Unlike in two-dimensional imaging, where slice thickness is essentially limited by the available gradient power, slab partitioning into slices in three-dimensional imaging is achieved by phase encoding. Current imaging techniques allow slice thicknesses as thin as 0.7 mm,

but, in general, section thickness is limited solely by S/N in 3DFT scanning. Section thickness on conventional 2DFT MR is limited by gradient strength. As with 2DFT imaging, S/N in three-dimensional imaging scales proportional to voxel size, so one sacrifices S/N to achieve very thin sections.

The advantage of reducing the TE to as short as possible derives from the resulting reduction in susceptibility artifacts. This is particularly important at bony interfaces in the cervical spine. To a lesser degree, shorter TEs will contribute to maintaining high S/N as relaxation occurs in this interval.

Applied to the cervical spine, 3DFT gradient-echo techniques allow acquisition of 60 1.5-mm contiguous sections from C2–C3 to C7–T1 in 6.5 min. The high bone–CSF–nerve-root sleeve contrast when low-flip-angle (<10°) techniques are used allows excellent visualization of foraminal anatomy and disease (Fig. 1) [6, 7]. Typically, four to five 1.5-mm-thick slices through the foramina are obtained to evaluate narrowing or lateral disk herniations. Although surgical intervention for bony neural foraminal disease often is not indicated, its detection is important to explain the patient's symptoms since other more peripheral lesions can mimic nerve root compression. Additionally, when significant neural foraminal narrowing is coupled with disk herniations, the surgical management may be altered.

Because of the infrequency of surgical intervention for bony narrowing of cervical neural foramina, this study relied on CT as the gold standard for evaluating the foramina. When there is no significant narrowing, it is impossible to get surgical proof, a point we acknowledged when determining the methodology for this study. Conservative, nonsurgical management, possibly even with the use of steroids, is an alternative to surgery in many cases. Even when surgery is performed, an anterior approach may be preferred for disk disease, which limits the surgeon's ability to detect how narrowed the foramen is and occasionally by what process. For these reasons, we used thin-section CT as our gold standard. In doing so, however, we realized that no true comparison could be made of the accuracy of MR and CT. We thus set CT's accuracy at 100%, so MR could never be proved to be better than CT in this study. Our intention was to see how well the two techniques correlated with each other. We intentionally studied the neural foramina because evaluation of bony disease is one of MR's weakest areas.

Our study demonstrates that interpretation of 3DFT gradient-echo MR agrees with CT in the determination of neural foraminal narrowing in over 75% of the cases with both the 5° and 30° flip angle series, when adequate studies are available. Of the cases in which the evaluators failed to detect abnormalities on MR that were seen by CT, 66 (97%) of 68 were because of bony encroachments. Therefore, the relative insensitivity of MR to bony disease found with spin-echo and 2DFT sequences appears to persist even with thin-section 3DFT gradient-echo imaging. Part of the difficulty in detecting bony encroachments on foramina is the fact that the dura and anulus, both of low signal intensity on gradient-echo images, may be mistaken for bone. Nonetheless, the overall accuracy (84%) of the 3DFT MR technique for the best evaluator approached that of intraobserver concordance in interpreting postmyelography CT images (85.5%). Also in this study, 3DFT

MR was more likely to be interpreted as showing foraminal stenosis when none was present on CT than not to demonstrate stenosis when CT was interpreted as having shown it.

MR image interpretation concurred with that of CT as to the cause of the narrowing in 78% (5°) and 71% (30°) of the levels when both studies agreed they were narrowed. Most of the cases in which the interpretations of the causes of the narrowing differed between CT and MR consisted of instances where bone and disk were confused with bone alone (65%). In fact, one might wonder whether MR, with its superior soft-tissue resolution, may be more accurate than CT in these cases. It is likely that remnants of hard disk herniations seen on MR may be present in some of the cases reported as bony osteophytes only on CT.

The interobserver concordance with MR was greater with the bright CSF technique (overall 83.0%) than the dark CSF series (73%) for the grading of narrowing. We believe that this is because of the lower contrast between the bony margins of the foramen and the CSF with the dark CSF 30° technique. The uncertainties of our interpreters regarding the foraminal margins in the presence of dark CSF is reflected in the very large number of indeterminate images with this technique (45 instances). One interpreter had a particularly difficult time distinguishing between bone and CSF in the lateral foramina and believed he could not confidently determine if the foramen was narrowed or not. The mean CT interobserver concordance (84% for grading) was in the same range of values as the 5° bright CSF results (83%) and compares favorably with the intraobserver concordance of the CT reading (85.5%). Because the evaluator's accuracy for grading the narrowing on MR scans (84%) was nearly the same as his accuracy in interpreting the CT scans on different days (85.5%), the study suggests that the maximum accuracy that one could expect to obtain in grading narrowing is approximately 85%, regardless of the technique.

The average CT inter- and intraobserver concordance were 85% and 94%, respectively, for the cause of narrowing. The comparative MR values of 75% for the 30° technique and 61% for the 5° technique suggest that CT is more reproducible in identifying the cause of narrowing. A steep learning curve may still exist in the MR technique, however, as evidenced by the wide range of values among evaluators.

Hedberg et al. [8] studied the efficacy of gradient-echo MR in the evaluation of cervical radiculopathy in 1988. They used low flip angles and 5-mm contiguous sections. In 29 of 30 locations, surgery confirmed the MR findings: in only one case of a ventrolateral osteophyte did the patient's clinical symptoms and surgical findings disagree with the MR impression. The MR-CT myelography correlation was 100% in 25 patients. These results led the authors to conclude that "MR imaging is the initial procedure of choice for the evaluation of suspected cervical radiculopathy" [8]. The use of thin-section 1.5-mm contiguous 3DFT imaging should only enhance the enthusiasm for MR in this area. Our results suggest that the enthusiasm should be tempered by the understanding that MR interpretation will disagree with CT in up to 25% of cases, even in the hands of experienced neuroradiologists.

A recent nonblinded, nonrandomized study compared 3DFT thin-section MR with 2DFT techniques in the evaluation of neural foramina [9]. Because this study used contiguous 1.5- to 2.0-mm 3DFT slices and compared them with 4-mm 2DFT scans with 1-mm interslice gaps, the results were not

surprising. The thinner slice technique provided greater detail of narrowing, and the apparent image contrast subjectively was greater with the high-intensity CSF 3DFT technique than with low-intensity CSF technique [9].

Many artifacts can degrade the 3DFT images. Motion in this 6.5-min series, including swallowing and respiratory motion, may prevent adequate evaluation of the foramina [5, 6]. Aliasing, in which the upper and lower slices are "wrapped around" each other, degrades slices at the extremes of the slab, typically the upper and lower first four slices. Therefore, one may have to sacrifice visualization of the C2-C3 level if clinical suspicion of disease is at the C7-T1 level in order to ensure high-quality images at the lower level. Ferromagnetic artifact in the postoperative cervical spine also will degrade gradient-echo images.

In our routine evaluation of the cervical spine, we use a contiguous 3-mm-thick sagittal 800/20/2 spin-echo sequence, followed by the 5° 50/15/1 3DFT sequence with gradient-moment nulling, a 256 × 128 matrix, and 60 1.5-mm contiguous sections. We also include the 30° 50/11/1 sequence without gradient-moment nulling. Our results suggest that 3DFT gradient-echo, thin, contiguous-section MR imaging is useful in assessing the neural foramina, since its accuracy in the best of interpreters approaches that of the intraobserver concordance when double reading CT scans, approximately 85%. The wide range of variability in our evaluators' grading of foramina suggests that the learning curve for MR interpretation probably has not peaked as it has with CT, and therefore its accuracy is strongly interpreter dependent.

Presumably, as neuroradiologists gain more experience with the technique, the reliability and reproducibility of MR interpretation will increase. It is still more difficult for MR to depict small bony encroachments on the foramina than to detect herniated disk material. The large number of indeterminate or uninterpretable images on the 30° technique, coupled with the superior bone-CSF contrast on the 5° technique, suggests that the latter is the more useful examination in the evaluation of the foramina.

REFERENCES

1. Czervionke LF, Daniels DL, Ho PSP, et al. Cervical neural foramina: correlative anatomic and MR imaging study. *Radiology* 1988;169:753-759
2. Modic MT, Masaryk TJ, Mulopulos GP, Bundschuh CV, Han JS, Bohlman H. Cervical radiculopathy: prospective evaluation with surface coil MR imaging, CT with metrizamide, and metrizamide myelography. *Radiology* 1986;161:753-759
3. Brown BM, Schwartz RH, Frank E, Blank NK. Preoperative evaluation of cervical radiculopathy and myelopathy by surface-coil MR imaging. *AJNR* 1988;9:859-866
4. Modic MT, Masaryk TJ, Ross JS, Mulopulos GP, Bundschuh CV, Bohlman H. Cervical radiculopathy: value of oblique MR imaging. *Radiology* 1987;163:227-231
5. Wehrli FW, Atlas SW. Fast imaging: principles, techniques, and clinical applications. In: Atlas SW, ed. *Magnetic resonance imaging of the brain and spine*. New York: Raven Press, 1990:1013-1078
6. Carlson J, Crooks L, Ortendahl D, Kramer DM, Kaufman L. Signal-to-noise ratio and section thickness in two-dimensional versus three-dimensional Fourier transform imaging. *Radiology* 1988;166:266-270
7. Enzmann DR, Rubin JB, Wright A. Cervical spine MR imaging: generating high signal CSF in sagittal and axial images. *Radiology* 1987;163:233-238
8. Hedberg MC, Drayer BP, Flom RA, Hodak JA, Bird CR. Gradient echo (GRASS) MR imaging in cervical radiculopathy. *AJNR* 1988;9:145-151
9. Tsuruda JS, Norman D, Dillon W, Newton TH, Mills DG. Three-dimensional gradient-recalled MR imaging as a screening tool for the diagnosis of cervical radiculopathy. *AJNR* 1989;10:1263-1271