

# Generic Contrast Agents

Our portfolio is growing to serve you better. Now you have a *choice*.



FRESENIUS  
KABI

[VIEW CATALOG](#)

# AJNR

## Orbital granulocytic sarcoma.

M Banna, R Aur and S Akkad

*AJNR Am J Neuroradiol* 1991, 12 (2) 255-258

<http://www.ajnr.org/content/12/2/255.citation>

This information is current as  
of May 4, 2025.

# Orbital Granulocytic Sarcoma

Mohamed Banna,<sup>1</sup> Rhomes Aur,<sup>2</sup> and Salah Akkad<sup>3</sup>

Granulocytic sarcoma is a rare solid tumor of immature granulocytes. It represents tumorous manifestation of granulocytic leukemia that may occur in the brain, paranasal sinuses, skeleton, chest, or abdomen [1, 2]. The term granulocytic sarcoma is used in preference to chloroma, because it refers to the cell origin of the tumor and not to its color, which fades away as the pigment myeloperoxidase is oxidized [2]. We describe the CT and MR findings in four children with orbital granulocytic sarcoma.

## Case Reports

Between June 1981 and December 1989, 60 children with acute myeloid leukemia were admitted to our institution for treatment. Of these, 37 were boys and 23 were girls, representing a sex ratio of 3:2 in favor of boys. The mean age was 5 years, with a range of 1 to 13 years. Four boys between the ages of 2 and 4 years developed proptosis and underwent CT and MR examinations before and after treatment. CT was performed on a GE 9800 scanner. The brain and orbits were examined in the axial projection without and with contrast enhancement. The slice thickness was 3 mm for the orbits and 10 mm for the brain. MR was performed on a 2055 HP Vista 1.5-T Picker system. Axial images were obtained with a slice thickness of 3 mm for the orbits and 7 mm for the brain. The pulse sequence was 600/20/2 (TR/TE/excitations) for T1 images and 2000/80/2 for T2 images.

### Case 1

A 2-year-old boy was brought by his parents to the local hospital because he was growing pale and had lost weight, which they attributed to diarrhea and for which he was treated. About 3 months later the child developed severe bilateral proptosis with limitation of eye movement. On examination, he also had hepatosplenomegaly and enlargement of the cervical lymph nodes. Chest, cardiovascular, and neurologic examinations were normal.

At our hospital, the diagnosis of leukemia was confirmed by bone marrow examination. CT and MR showed bilateral orbital masses. After systemic and intrathecal chemotherapy, orbital irradiation was given through an anterior field using 12-MeV electrons to a dose of 3000 cGy in 3 weeks. The orbital masses resolved within 8 weeks.

The child has been in complete remission for approximately 14 months since the onset of the disease (Fig. 1).

### Case 2

A 4-year-old boy was brought by his parents to the local hospital because of swelling of both eyes that had been progressive over a period of approximately 5 weeks. The proptosis was so severe that the child could not close his eyes, and eye movements were restricted. Physical examination revealed mild hepatomegaly, but no other abnormality. Peripheral blood smear showed multiple "blast" cells consistent with leukemia.

At our hospital, a CT scan showed extensive leukemic infiltrate within the orbits, paranasal sinuses, and nasopharynx. The child received systemic chemotherapy with poor initial response. Local irradiation was given to the orbits, which resulted in considerable resolution of the orbital masses. A dose of 1600 cGy in 2 weeks was given via two lateral fields using 8-MeV X-rays (Fig. 2). After a short period of remission, his disease became refractory to various drug combinations and the child died 1 year after initial presentation.

### Case 3

A 3-year-old boy presented to another hospital with proptosis of the left eye of 2 weeks duration. CT and MR scans revealed left orbital tumor, which was biopsied and diagnosed as rhabdomyosarcoma. He was referred to our hospital for treatment. On arrival, the child had already developed bilateral proptosis, and CT demonstrated soft-tissue masses within the orbits and paranasal sinuses. Examination of bone marrow confirmed the diagnosis of leukemia. There was no apparent involvement of other organs or enlargement of lymph nodes. After chemotherapy the orbital masses disappeared within 3 weeks and bone regeneration was evident. At present the child is alive and well approximately 1 year from the onset of proptosis (Fig. 3).

### Case 4

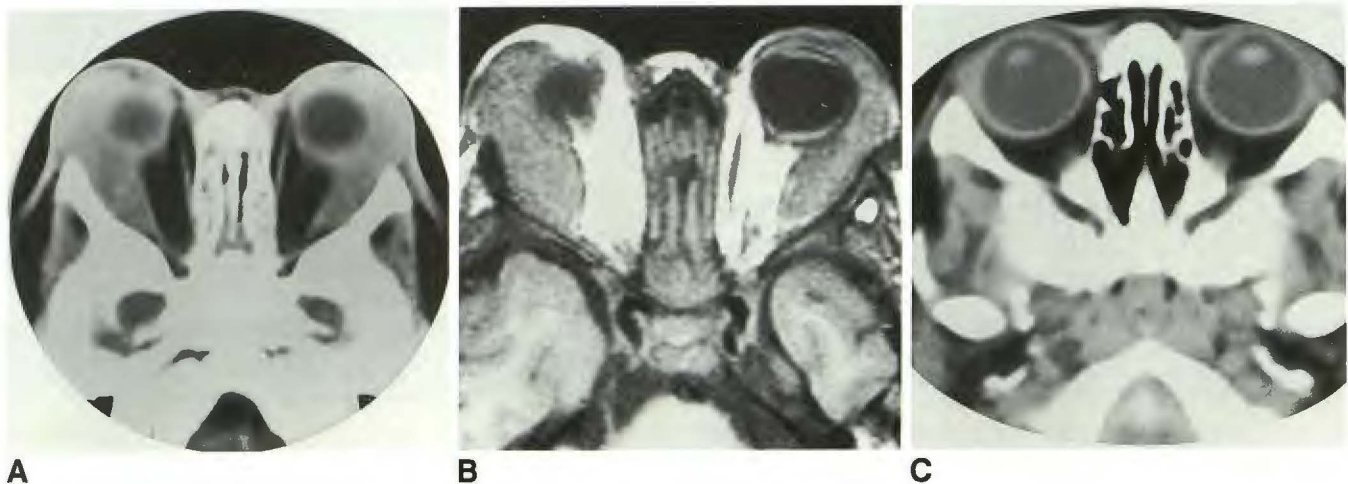
A 4-year-old boy was transferred to our hospital from another institution, where clinical, radiologic, and histologic examinations of a right periorbital mass were performed and a diagnosis of rhabdo-

Received March 13, 1990; revision requested June 23, 1990; revision received July 24, 1990; accepted August 9, 1990.

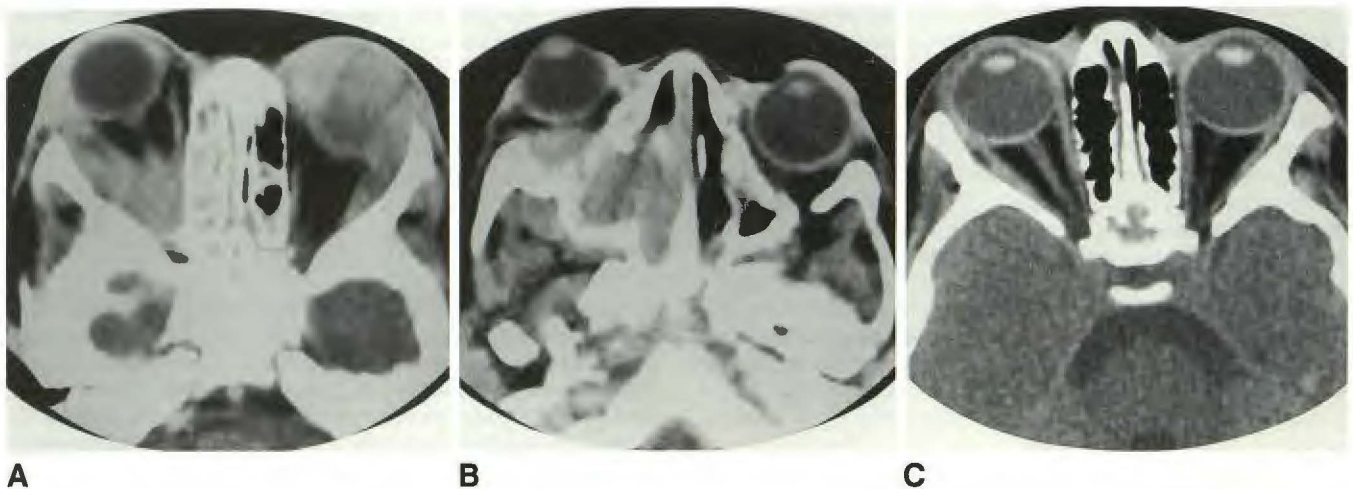
<sup>1</sup> Department of Radiology, King Faisal Specialist Hospital and Research Centre, P.O. Box 3354, Riyadh 11211, Saudi Arabia. Address reprint requests to M. Banna.

<sup>2</sup> Department of Oncology, King Faisal Specialist Hospital and Research Centre, Riyadh 11211, Saudi Arabia.

<sup>3</sup> Department of Radiotherapy, King Faisal Specialist Hospital and Research Centre, Riyadh 11211, Saudi Arabia.



**Fig. 1.**—Case 1: Bilateral orbital granulocytic sarcoma.  
**A,** Axial contrast-enhanced CT scan shows bilateral extraconal masses along lateral orbital walls and globes with further extension into eyelids. Note difference in tissue density between sclera and neoplasm.  
**B,** Axial T1-weighted MR image obtained immediately after CT scan in A. Bilateral soft-tissue masses are evident with signal intensity similar to gray matter but less than sclera. Neoplastic tissue is separated from orbital fat by the periorbital fat, and its signal intensity is distinctly different from adjacent sclera.  
**C,** Contrast-enhanced axial CT scan of the orbits shows resolution of neoplastic masses after 8 weeks of treatment.



**Fig. 2.**—Case 2: Granulocytic sarcoma of the orbits with involvement of paranasal sinuses.  
**A,** Axial contrast-enhanced CT scan shows neoplastic masses along lateral wall and apex of right orbit, also on nasal and temporal surface of left globe and along lateral wall of left orbit. Note opacification of right ethmoids.  
**B,** CT scan at slightly lower level than A shows neoplastic masses within right nasal cavity and maxillary sinus associated with destruction of medial wall of antrum.  
**C,** CT scan after 6 weeks of treatment shows complete resolution of neoplastic masses and aerated ethmoids.

myosarcoma was made. At our hospital, the pathologic slides were reviewed and on examining the bone marrow, the diagnosis of orbital granulocytic sarcoma was made. No evidence of leukemia elsewhere was found. He was treated with systemic chemotherapy and local irradiation of the right orbit. A dose of 800 cGy in 1 week from an anterior 6-MeV X-ray field was delivered. A follow-up CT scan showed resolution of the orbital mass within 4 weeks. This was followed by consolidation radiotherapy to 2500 cGy in 2 weeks via one lateral 8-MeV X-ray field. At present, the child is in complete remission 14 months from his initial presentation (Fig. 4).

## Discussion

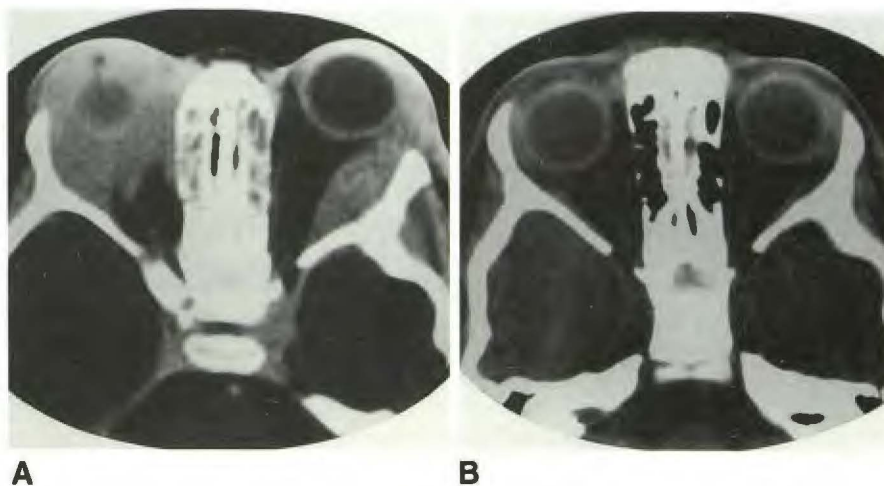
Leukemia accounts for less than 2% of all orbital tumors in children [3]. The rate of occurrence is higher in Africa, the Middle East, and Asia, where it accounts for as much as 27% of orbital tumors in some localities. The peak period of occurrence is between 4 and 5 years of age, but two of our patients were 2 and 3 years old, respectively, and a case has been reported in a 16-month-old boy [4].



**Fig. 3.—Case 3: Bilateral orbital granulocytic sarcoma.**

**A,** Axial contrast-enhanced CT scan shows neoplastic tissue along lateral orbital walls and encasing right globe.

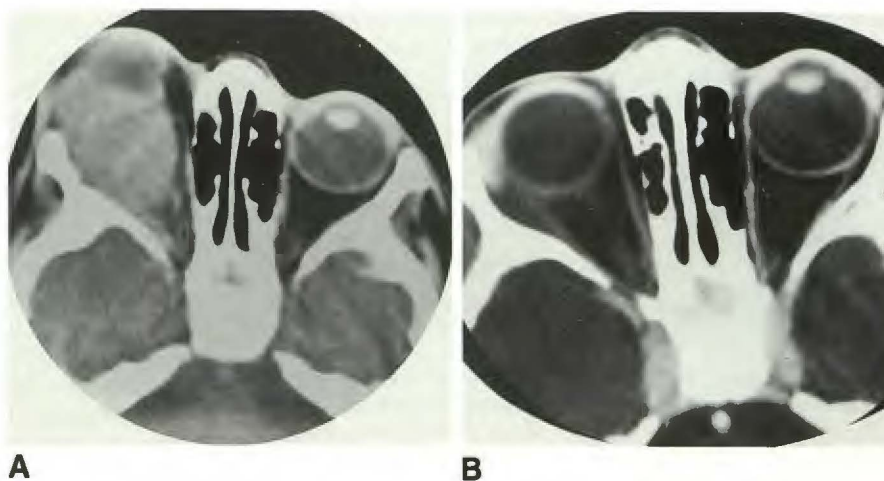
**B,** CT scan shows almost complete resolution of neoplastic masses after 8 weeks of treatment.



**Fig. 4.—Case 4: Unilateral granulocytic sarcoma.**

**A,** Axial unenhanced CT scan shows a huge neoplastic mass behind right globe and along lateral wall of right orbit.

**B,** Axial contrast-enhanced CT scan shows total resolution of lesion after 6 weeks of therapy.



Orbital involvement may occur concomitantly with or following the onset of leukemia by up to 2 years [2]. In a child with acute myelogenous leukemia, orbital involvement may occur after a long period of remission and may be unilateral or bilateral. The lesions may arise primarily within the orbit, or they may extend into the orbit from neighboring structures of which the paranasal sinuses are the most frequent source. Leukemic involvement of the optic nerve, uveal tract, and retina is rare. However, optic nerve invasion is considered indicative of CNS involvement and may be the first manifestation of the disease [5].

In the present cases, CT revealed homogeneous soft-tissue masses, which appeared in many of the affected orbits to originate outside the muscle cone and in relation to the lateral wall of the orbit more often than the medial wall. Invasion of orbital fat was seen. The sclera, even when encased by tumor, could be differentiated from neoplastic tissue by its higher density on the unenhanced and the enhanced scans, and was resistant to tumor invasion. There was no case in which tumor extension transgressed the sclera into the vitreous, but invasion of the eyelids was common. After IV contrast injection,

there was some increase in the density of the lesions, but this did not contribute to the diagnosis. Calcification was absent. Bone destruction was present in one case in which orbital invasion originated from lesions within the nasal cavity and paranasal sinuses.

On MR, the T1-weighted images were the most helpful. On these, neoplastic tissue was almost isointense with cerebral gray matter, but it could be differentiated by its higher signal intensity than that of the periorbital and sclera. The presence of tumor tissue beneath the temporal lobe in one case and of tumor extension into the infratemporal fossa in another was more clearly seen on MR. In all four cases there was dramatic response to chemotherapy and external radiation. Reduction of proptosis was evident within days after the start of treatment.

#### ACKNOWLEDGMENTS

We thank G. Pammer and his staff for the photographic work, and C. Devane and C. Healy for manuscript preparation.

## REFERENCES

1. Pomeranz SJ, Hawkins HH, Towbin RB, Lisberg WN, Clark RA. Granulocytic sarcoma (chloroma): CT Manifestations. *Radiology* **1985**;155:167-170
2. Kao SCS, Yuh WTC, Sato Y, Barloon TJ. Intracranial granulocytic sarcoma (chloroma): MR findings. *J Comput Assist Tomogr* **1987**;11:938-941
3. Cavdar AO, Babacan E, Gözdasoglu S, et al. High risk subgroup of acute myelomonocytic leukemia (AMML) with orbito-ocular granulocytic sarcoma (OOGS) in Turkish children. Retrospective analysis of clinical, hematological, ultrastructural and therapeutic findings of thirty-three OOGS. *Acta Haematol* **1989**;81:80-85
4. Cohen R, Segall HD, Nelson MD, Zee CS, Ahmadi J. Bilateral retroorbital chloromas in a 16-month-old child: CT features. *J Comput Assist Tomogr* **1988**;12:895-896
5. Nikaido H, Mishima H, Ono H, Choshi K, Dohy H. Leukemic involvement of the optic nerve. *Am J Ophthalmol* **1988**;105:294-298

The reader's attention is directed to the commentary on this article, which appears on pages 263-264.