Are your MRI contrast agents cost-effective?
Learn more about generic Gadolinium-Based Contrast Agents.
FRESENIUS KABI
caring for life

AJNR

Diagnosis of cerebral metastases: double-dose delayed CT vs contrast-enhanced MR imaging.

P C Davis, P A Hudgins, S B Peterman and J C Hoffman, Jr

AJNR Am J Neuroradiol 1991, 12 (2) 293-300
http://www.ajnr.org/content/12/2/293

This information is current as of May 12, 2024.

Diagnosis of Cerebral Metastases:
Double-Dose Delayed CT vs Contrast-Enhanced MR Imaging

Patricia C. Davis[1]
Patricia A. Hudgins
Susan B. Peterman
James C. Hoffman, Jr.

For patients suspected of having cerebral metastases, double-dose delayed CT (DDD-CT) has proved significantly more sensitive than CT scans obtained immediately after administration of a lesser dose of iodinated contrast material. Previous reports confirm the advantages of postcontrast MR imaging over contrast-enhanced CT, but data comparing DDD-CT and contrast-enhanced MR have not been reported. This study describes comparative imaging results in 23 patients who had contrast-enhanced MR imaging to clarify equivocal findings on DDD-CT studies. Contrast-enhanced MR demonstrated more than 67 definite or typical parenchymal metastases, T2-weighted MR revealed more than 40, while DDD-CT revealed only 37 typical metastatic lesions. Three patients had five or fewer lesions on DDD-CT and lesions "too numerous to count" on MR. The frequency of equivocal or unconvincing lesions was similar on DDD-CT (11) and contrast-enhanced MR (10). On T2-weighted images, we noted a substantially higher number of equivocal lesions (19), fewer definite metastases, and a number of definite metastases that had no corresponding lesion on the enhanced studies, confirming the inability of T2-weighted imaging to specifically identify cerebral metastases. In one case, multiple tiny lesions on T2-weighted images were not apparent on DDD-CT scans and were recognized only in retrospect on contrast-enhanced MR images.

In this series, MR with enhancement proved superior to DDD-CT for lesion detection, anatomic localization of lesions, and differentiation of solitary vs multiple lesions. Cost-benefit considerations precluded a comparison between the two techniques in all patients suspected of having cerebral metastases. Given the complexities of the cost of imaging procedures and the benefits of therapy, it is not possible to state that all patients suspected of having cerebral metastases should undergo contrast-enhanced MR imaging. At this time, given our protocol for evaluating metastatic disease, contrast-enhanced MR should be performed in patients with equivocal or solitary lesions on DDD-CT, particularly when surgical resection of a metastatic focus is considered.

***AJNR* 12: 293–300, March/April 1991; *AJR* 156: May 1991**

Cerebral metastases account for up to 40% of brain neoplasms in adults [1] and are identified in up to 5% of patients with fatal malignancies. Detection of these metastases has received much attention in recent years, particularly with the development of paramagnetic contrast agents, such as gadopentetate dimeglumine, for use with MR imaging. Many studies attest to the improved sensitivity and specificity of contrast-enhanced MR relative to routine contrast-enhanced CT and to unenhanced MR for a variety of CNS lesions, including both primary and metastatic neoplasms [2–10].

CT performed with a high dose of iodinated contrast (74–84.6 g I) and delayed scanning (double-dose delayed CT [DDD-CT]) significantly improves the sensitivity and specificity of cerebral metastatic disease detection [11–13]. In a study by Shalen et al. [11], delayed images afforded more information in 67% of cases; moreover, false-negative studies would have occurred in 11.5% of the patients if just a routine scan immediately after contrast administration had been obtained.

Earlier studies [2–10] comparing MR with contrast-enhanced CT for accuracy in

Received August 9, 1990; revision requested September 7, 1990; revision received October 15, 1990; accepted October 16, 1990.

[1] All authors: Department of Radiology, Division of Neuroradiology, Emory University School of Medicine, 1364 Clifton Rd., N.E., Atlanta, GA 30322. Address reprint requests to P. C. Davis.

0195-6108/91/1202-0293
© American Society of Neuroradiology

detecting cerebral metastases suggest a significant advantage of the MR technique; however, these studies generally compared immediate postcontrast CT scans with unenhanced or contrast-enhanced MR. As pointed out by Sze et al. [10], little is known of comparative sensitivity and specificity of DDD-CT vs contrast-enhanced MR. Since mid 1988, we have recommended confirmatory contrast-enhanced MR for all patients suspected of having cerebral metastasis who have had equivocal or solitary lesions on DDD-CT. Comparative findings from 23 patients who underwent both examinations within a short period of time form the basis of this report.

Materials and Methods

From September 1988 until December 1989, 22 patients underwent contrast-enhanced MR imaging for follow-up of DDD-CT studies considered equivocal for presence, number, and/or anatomic definition of cerebral metastasis. One additional study was performed earlier during the phase 3 FDA trials for gadopentetate dimeglumine. The group included 11 men and 12 women ranging in age from 34 to 72 years (mean, 55.9 years). Primary malignancies included lung (nine), breast (five), unknown (four), renal (two), melanoma (two), and plasma cell myeloma (one).

After obtaining informed consent, cerebral CT was performed in all patients suspected of having cerebral metastatic disease by using a bolus of 200 ml of iodinated contrast (diatrizoate dimeglumine and diatrizoate sodium; Angiovist-370 [Berlex, Wayne, NJ] or Hypaque 76 [Winthrop, Des Plaines, IL]; 74 g organically bound iodine) followed by a 1-hr delay before scanning. No patient had significant adverse sequelae after contrast administration, although patients who failed to receive a full contrast dose or who did not complete the DDD-CT protocol because of motion, instability, renal compromise, history of allergic reaction, or allergic reaction were excluded from this study. Twenty-one CT scans were acquired in the axial plane with 5-mm collimation in the posterior fossa and 10-mm collimation to the vertex (Philips LX or TX-60 [Shelton, CT], GE 9800 HiLite [Milwaukee, WI], or Picker Synerview 1200SX [Highland Heights, OH]). Two scans were obtained with sequential 7-mm collimation (Technicare 2010, Solon, OH). Scan angles varied from 0–15° relative to Reid's base line. All studies were photographed on soft-tissue and bone windows.

A follow-up postcontrast MR examination was recommended for any patient with equivocal or atypical lesions on DDD-CT scans, for patients with a solitary lesion who might be candidates for neurosurgical resection, and for patients with lesions that were equivocal or inadequately defined for confident therapeutic planning in the opinion of our referring physicians. Contrast-enhanced MR examinations were performed at a mean time of 9.3 days after the DDD-CT study (range, 0–43 days). Scans were obtained with a variety of magnets and field strengths (0.5 T, 12 cases, Philips [Shelton, CT]; 1.0 T, two cases, Siemens [Erlangen, Germany]; or 1.5 T, nine cases, Philips [Shelton, CT]), beginning with a multislice noncontrast T1-weighted scout sagittal sequence (TR </= 600, TE </ = 30). After obtaining informed consent, gadopentetate dimeglumine was administered intravenously in a dose of 0.1 mmol/kg over 1–2 min. T2-weighted axial scans with 6–10-mm slice thickness were obtained first after contrast administration (1699–3700, 25–50, and 90–100/1–2) (TR/TE/excitations) followed by one or more T1-weighted postcontrast sequences (433–800, 15–30/1–2) using 4–10-mm slice thickness. Postcontrast sequences were delayed 14 min or more after contrast administration in 20 of the 23 patients. The mean delay between contrast administration and the last T1-weighted sequence was 22 min (range, 4–60 min). The MR imaging protocol used in this study is given in Table 1. In one patient, no T2 sequence was acquired owing to limited scanning time available; one MR study was suboptimal because of patient motion; one patient had additional sequences based on the phase 3 FDA investigation protocol for Magnevist; and one patient's first postcontrast T1-weighted scan was erroneously obtained with a TE of 50.

To reduce the possibility of bias in interpreting the scans, a retrospective blinded evaluation of the studies was made by at least two experienced neuroradiologists. These physicians were aware that the patients were thought to have cerebral metastases, but they were otherwise blinded to clinical findings and follow-up studies. Three groups of studies (DDD-CT, T2-weighted MR, and T1-weighted pre- and postcontrast MR) were presented to the observers in random order as independent examinations over several months and remote from the time of actual scan acquisition and interpretation. Two or three evaluators recorded by consensus the presence, number, and location of typical or convincing (definite) intraparenchymal metastatic lesions (supra- vs infratentorial); dural or meningeal metastases; bone metastases; equivocal lesions; and other abnormalities present (infarct, surgical sites). More than seven lesions in a given distribution were rated as too numerous to count. Patient follow-up included review of radiologic studies for evidence of disease progression and clinical status on last examination.

Results

A comparison of metastatic lesions detected on DDD-CT, T2-weighted MR, and pre- and postcontrast MR examinations is charted in Table 2. Two patients had one or more hemorrhagic or melanotic lesions, diagnosed on the basis of high signal intensity on T1-weighted MR images or marked hypointensity typical of hemoglobin breakdown products on T2-weighted images.

Contrast-enhanced MR revealed additional intraparenchymal lesions as compared with DDD-CT in nine of 23 patients (Fig. 1). In only one patient were metastases seen best on T2-weighted images, and they were recognized only in retrospect on contrast MR studies (Fig. 2). These multiple tiny foci were recognizable but subtly hypointense on noncontrast T1-weighted images at 0.5 T, and paramagnetic contrast enhancement rendered them nearly isointense with normal parenchyma on enhanced T1-weighted images. Of 11 patients with only one definite or one suspicious lesion on DDD-CT, one had dural disease only on MR, four had two or more

TABLE 1: MR Protocol for Suspected Cerebral Metastases

1. Obtain informed consent for paramagnetic contrast administration.
2. Start intravenous line with long tubing.
3. Position patient in magnet.
4. Obtain scout multislice T1-weighted sagittal image.
5. Obtain precontrast axial T1-weighted sequence *only* if hemorrhage is suspected.
6. Administer contrast and flush intravenous tubing.
7. Obtain axial T2-weighted sequence, 6 mm or less slice thickness, minimum interslice gap.
8. Obtain postcontrast axial T1-weighted sequence, minimum TE </= 30, TR < 800, slice thickness </= 6 mm.
9. If #8 reveals two or more typical metastases, stop scanning. Continue T1 scans to 20–30 min after contrast injection if one or no lesions are detected on first T1 contrast-MR sequence. If needed, use other imaging planes and T1 sequences to better demonstrate lesions anatomically.

TABLE 2: Comparative No. of Lesions Detected in 23 Patients: Double-Dose Delayed CT, Contrast-Enhanced MR, and T2-Weighted MR[a]

	Double-Dose Delayed CT	Contrast-Enhanced MR	T2-Weighted MR
Supratentorial intraaxial metastases	27	35[b]	17
Infratentorial intraaxial metastases	10	26[b]	14[c]
Total intraaxial metastases	37	61[b]	31[c]
Equivocal intraaxial metastases	11	10	19
Meningeal/dural metastases	0	3	2
Bone lesions (no. of patients)	3	3	3

[a] One MR study was significantly degraded by motion, and in one patient no T2 sequence was performed.

[b] Three patients had numerous (more than seven) lesions on contrast-enhanced MR that were not apparent on double-dose delayed CT and that were underestimated on T2-weighted MR. Of these, one had numerous lesions both supra- and infratentorially. One patient had multiple contiguous lesions on MR and only one lesion on double-dose delayed CT.

[c] One patient had numerous infratentorial lesions on T2-weighted MR that were recognizable only in retrospect on contrast-enhanced MR; only one infratentorial lesion was detected on double-dose delayed CT.

typical metastases on contrast MR, and two had equivocal findings on both DDD-CT and contrast MR. One solitary lesion was mislocalized as intraparenchymal on DDD-CT, but was clearly an extraaxial dural and bone-based lesion on MR. One patient had two typical metastases on DDD-CT and only one lesion on contrast MR. In this patient, enhanced T1-weighted images were erroneously obtained with a prolonged echo time (500/50; 0.5 T). Repeat T1-weighted images, acquired after the error was recognized (60 min after contrast administration) failed to reveal additional lesions. In no other patient were more metastases found by DDD-CT than by enhanced T1- and T2-weighted MR.

Three patients with five or fewer lesions on DDD-CT had lesions too numerous to count on contrast MR. Two patients had lesions in the basal ganglia, which on DDD-CT mimicked calcification rather than metastasis (Fig. 1). Although the possibility of an enhancing lacunar infarction could not be entirely excluded, patient age, coexisting metastases, and absence of clinical findings to support infarction suggested that these were metastases.

Lesions in the posterior fossa were generally much better localized and characterized on MR than on CT (Fig. 3), and MR was particularly advantageous in differentiating intraparenchymal from dural/meningeal lesions. One patient with melanoma had a solitary expansile clival mass that was surgically proved to be chordoma rather than metastasis. In one case, metastasis could not be confidently diagnosed on MR or on CT, and follow-up studies with clinical correlation suggested that the lesions represented subacute infarction rather than metastasis.

T2-weighted images were more sensitive than DDD-CT for detecting infratentorial lesions, but less sensitive than DDD-CT for detecting supratentorial metastases. In part, this stemmed from the difficulty in accurately characterizing lesions on T2-weighted images, since raters noted many more equivocal lesions on T2-weighted images (19 lesions) than on either contrast MR (10 lesions) or DDD-CT studies (11 lesions). Slightly more definite metastases were noted on T2-weighted images than on DDD-CT (40 vs 37), and only the one patient with multiple tiny posterior fossa metastases had definite metastases on T2-weighted images that were not initially recognized as metastases on contrast-enhanced MR and/or DDD-CT.

Because tissue confirmation was not available for all lesions, a gold standard for comparing sensitivity and specificity of DDD-CT with MR on a lesion by lesion basis was not possible. Follow-up studies demonstrating disease progression in a majority of our patients in spite of radiation and/or chemotherapy, however, suggest that the additional lesions detected on MR probably represented metastases. Follow-up evaluations as of July 1990 indicated persistent or progressive brain metastases in one, systemic metastases in four, clinical and/or radiologic evidence of multisystem metastases in four, and death attributed to progressive metastatic disease in 10. One patient was lost to follow-up after surgical resection of a solitary metastasis. One patient with definite metastases on MR and DDD-CT and CT-guided biopsy suggestive of multiple sclerosis, and one patient with lung carcinoma and equivocal lesions on both DDD-CT and MR examinations was presumed to have infarction rather than metastasis. One patient with definite metastasis from melanoma on all studies had a secondary primary tumor (chordoma) rather than metastasis.

Discussion

Primary malignancies implicated in cerebral metastases in descending order of frequency are lung, breast, melanoma, renal, stomach, prostate, and thyroid [1], with sarcoma, lymphoma, and leukemia found increasingly in patients with immune disorders. Leptomeningeal metastases tend to occur in primary hematologic malignancies, such as lymphoma or leukemia; in children with a variety of CNS primary tumors; or in common adult malignancies, such as breast or lung carcinoma. Multiplicity of lesions is helpful for suggesting metastatic disease, although other diseases must be considered, particularly in patients with immune compromise. Multiple cerebral metastases generally are treated with radiation therapy, perhaps with chemotherapy, while solitary lesions diagnosed on the basis of contrast-enhanced CT studies may be surgically resected [14]. A recent study by Patchell et al. [15] found an increased time of survival and an improved quality of life in patients with surgically resected solitary metastasis as compared with those receiving radiation therapy after biopsy alone. Eleven percent of patients presumed preoperatively to have a solitary metastasis on the basis of CT and clinical findings had other neoplastic or inflammatory/infectious disease at surgery [15].

The ideal imaging study for suspected metastases requires sensitivity to lesion detection; anatomic resolution for surgical planning; ability to differentiate metastasis from other diseases; sensitivity to coexisting diseases; minimal invasiveness; and acceptable safety/toxicity, availability, examination time, and cost. Prior to the development of MR contrast agents, contrast-enhanced CT or DDD-CT were the proce-

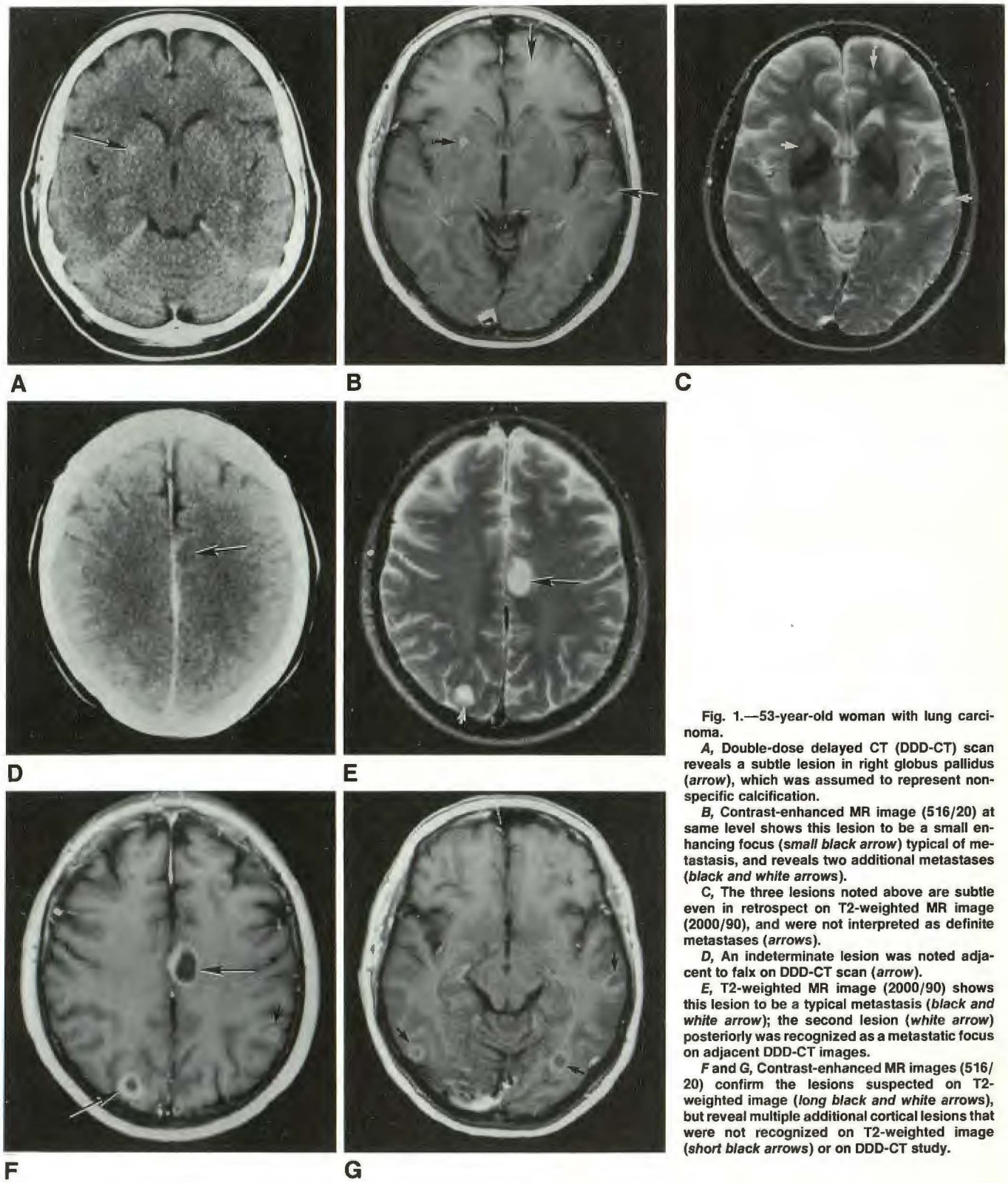

Fig. 1.—53-year-old woman with lung carcinoma.

A, **Double-dose delayed CT (DDD-CT) scan reveals a subtle lesion in right globus pallidus (*arrow*), which was assumed to represent nonspecific calcification.**

B, **Contrast-enhanced MR image (516/20) at same level shows this lesion to be a small enhancing focus (*small black arrow*) typical of metastasis, and reveals two additional metastases (*black and white arrows*).**

C, **The three lesions noted above are subtle even in retrospect on T2-weighted MR image (2000/90), and were not interpreted as definite metastases (*arrows*).**

D, **An indeterminate lesion was noted adjacent to falx on DDD-CT scan (*arrow*).**

E, **T2-weighted MR image (2000/90) shows this lesion to be a typical metastasis (*black and white arrow*); the second lesion (*white arrow*) posteriorly was recognized as a metastatic focus on adjacent DDD-CT images.**

F **and** ***G,*** **Contrast-enhanced MR images (516/20) confirm the lesions suspected on T2-weighted image (*long black and white arrows*), but reveal multiple additional cortical lesions that were not recognized on T2-weighted image (*short black arrows*) or on DDD-CT study.**

dures of choice for demonstration and localization of cerebral metastases. CT is widely available, often less expensive than MR, more sensitive to acute hemorrhage and bone abnormalities, and can be performed in obtunded, unstable, or uncooperative patients [16].

Shalen et al. [11] found that a high-dose infusion of contrast followed by delayed CT imaging increased sensitivity for detecting metastases by as much as 67% as compared with immediate CT scanning [11]. If diagnosis had been based solely on the findings of CT performed immediately after

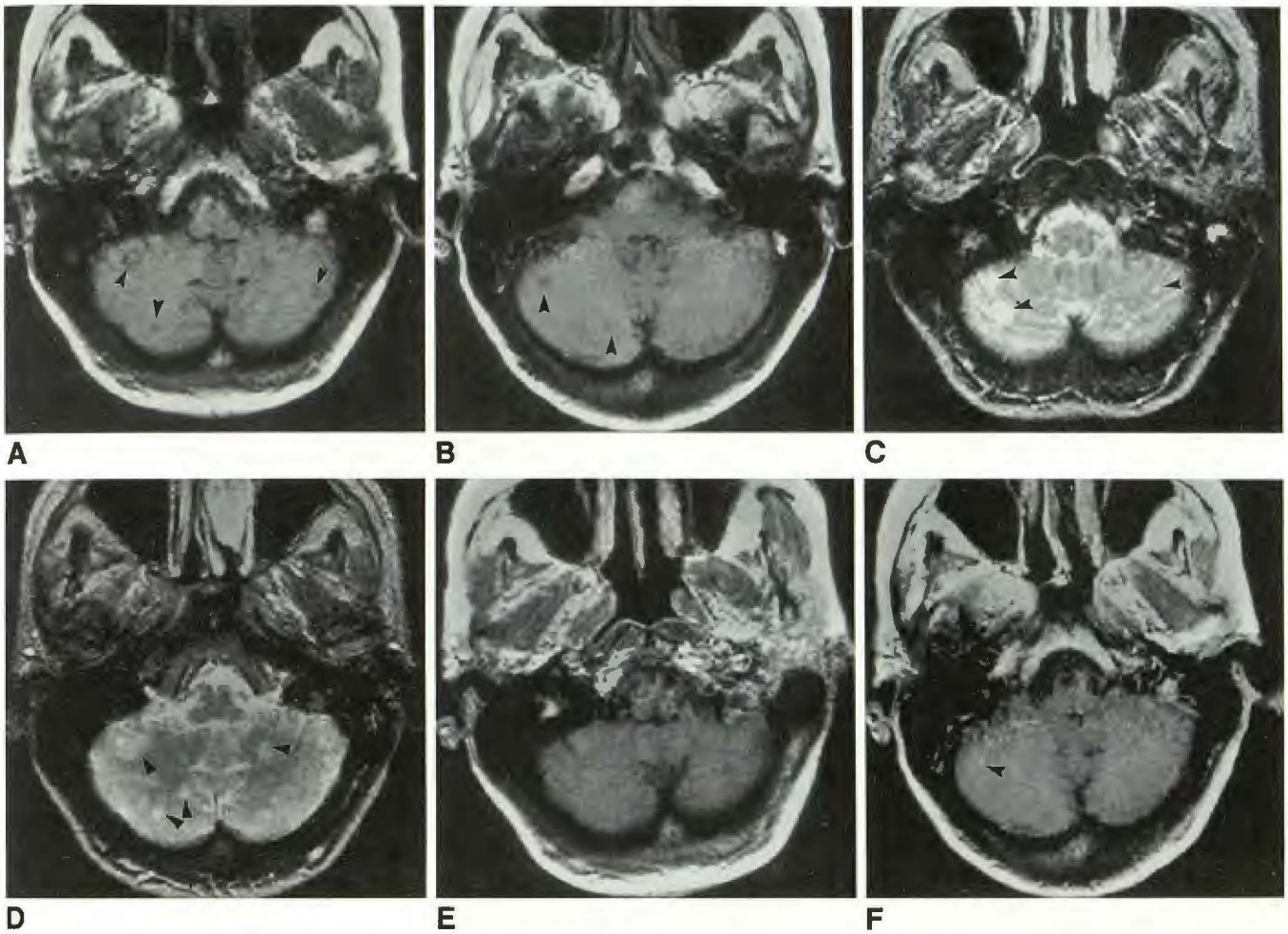

Fig. 2.—63-year-old woman with multiple infratentorial metastases, best seen on T2-weighted MR images. Double-dose delayed CT (DDD-CT) scan was interpreted as showing one definite posterior fossa mass.

***A* and *B*, Precontrast axial T1-weighted MR image (500/20) at 0.5 T faintly reveals multiple subtle hypointense foci in both cerebellar hemispheres (*arrowheads*).**

***C* and *D*, Multiple hyperintense foci (*arrowheads*) are recognizable on T2-weighted MR images (2300/90).**

***E* and *F*, After contrast administration, multifocal lesions enhance to approximate isointensity with normal parenchyma. Only one definite lesion (*arrow* in *F*) was recognized on these postcontrast T1-weighted MR images (500/20).**

contrast administration, 11.5% of the studies would have shown false-negative results [11]. At our institution, DDD-CT has been the routine CT technique for patients thought to have cerebral metastases, particularly since many of our patients receive a relatively high dose of contrast anyway in conjunction with staging or follow-up studies of the chest, abdomen, and/or pelvis. Delayed contrast-enhanced CT can be completed after other metastatic survey examinations without additional appointments or additional contrast injections, although drawbacks include the high dose of iodinated contrast required, the toxicity and anaphylaxis associated with iodinated contrast, ionizing radiation, interference from Hounsfield artifact, and insensitivity for leptomeningeal metastases [17]. Prior studies have suggested that both a high contrast dose (74–80 g I) [11–13] and delayed scanning are important for disease detection. Although substitution of nonionic for ionic contrast agents might result in reduced renal toxicity or allergic reactions, use of nonionic contrast agents produces a substantial increase in the cost of DDD-CT examinations.

Studies of contrast-enhanced MR for diagnosing cerebral metastases to date have largely been in comparison with routine contrast-enhanced CT [5, 7, 8, 10]. Comparative data on DDD-CT vs contrast-enhanced MR are needed in order to choose the optimum imaging method. Compared with CT, MR is often more expensive, not as widely available, relatively slow, less sensitive for detecting acute hemorrhage, particularly at lower field strengths, and less easily scheduled or combined with other staging imaging studies. Although early noncontrast MR studies were promising for hemorrhagic or melanin-containing lesions [18, 19], noncontrast MR was insensitive for detection of leptomeningeal disease, lesions adjacent to CSF interfaces, small lesions without associated hemorrhage or edema, or acute hemorrhage; they also lacked specificity, with many entities having similar MR intensities on T2-weighted images [8, 9, 20–22].

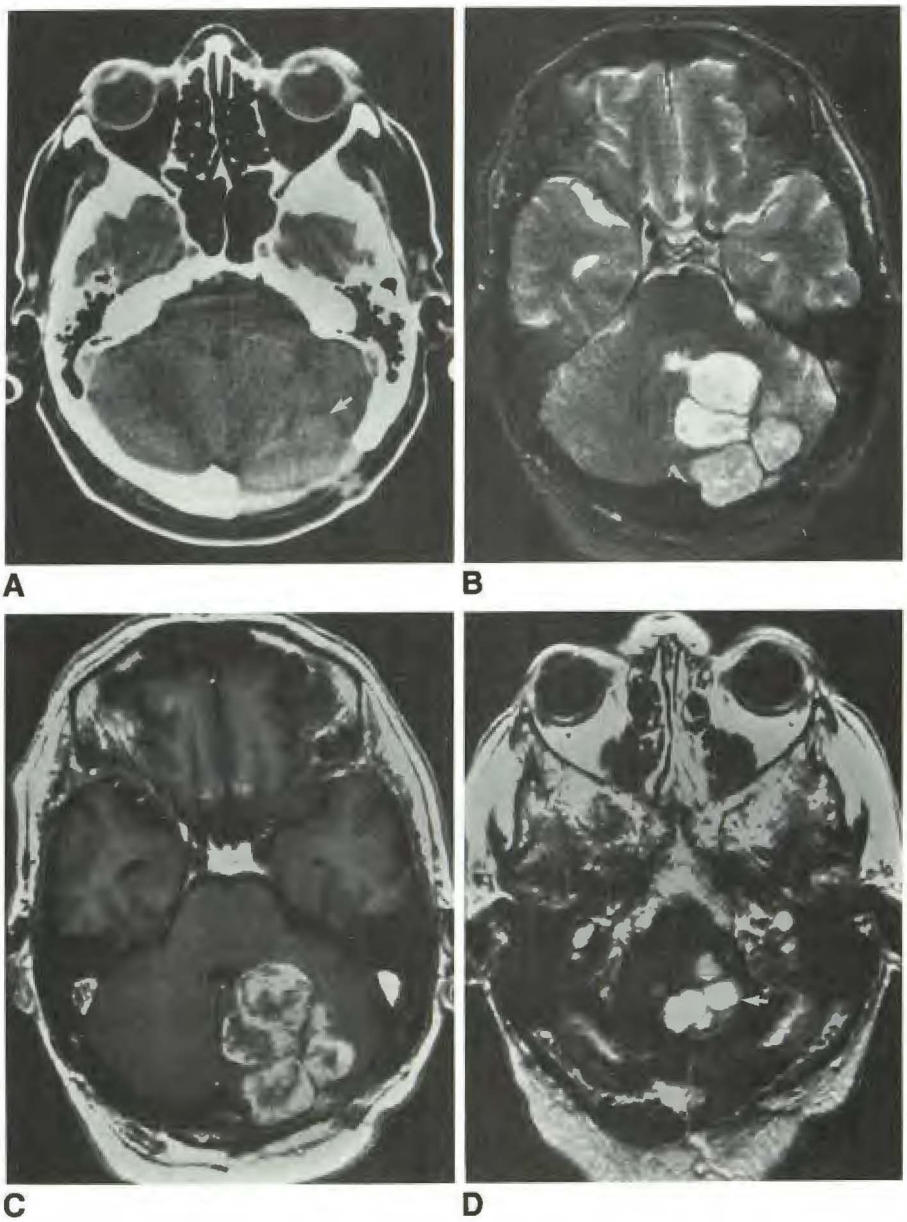

Fig. 3.—A recurrence of metastasis from an unknown primary tumor in the posterior fossa in a patient with prior surgical resection is best seen by MR imaging.

A, **Double-dose delayed CT (DDD-CT) scan shows poorly enhancing mass at surgical site (*arrow*).**

B, **This extensive lesion is much better demarcated from normal parenchyma on T2-weighted MR image (2180/90).**

C **and** ***D,*** **This multifocal and/or multilobular mass enhances markedly (*C*) and extends to foramen magnum (*D*) (*arrow*) on T1-weighted MR studies (566/20).**

Paramagnetic contrast agents have resulted in improved MR sensitivity in detecting metastases [4, 5, 7, 8]. The results of the present study of patients with equivocal or solitary lesions on DDD-CT indicate that contrast-enhanced MR is substantially more sensitive than DDD-CT for lesion detection and localization of cerebral metastatic disease. On the other hand, 21 patients had at least one definite lesion on both DDD-CT and contrast-enhanced MR, suggesting similar sensitivity for overall disease detection. The high percentage of patients with definite metastasis on DDD-CT by retrospective interpretation suggests a study bias in favor of this technique, since the DDD-CT interpretations were in doubt at the time of the actual examination and prompted the referral for MR. Alternatively, use of contrast-enhanced MR to clarify equivocal DDD-CT findings may introduce a bias in favor of that technique.

The improved lesion detection by contrast MR held true in this series not only for studies performed with high-field-strength magnets and short echo times but also for lower-field-strength magnets (0.5 T) with relatively long echo times (TE = 30) and resultant reduced sensitivity to T1 shortening from paramagnetic contrast enhancement and greater flow-related artifacts [5, 23]. Contrast MR permitted superior detection of lesions near dense bone either cortically or in the posterior fossa, and provided confident identification of metastatic lesions in unusual locations (basal ganglia). In patients under consideration for neurosurgical resection, the superior anatomic definition and multiplanar demonstration of lesions was useful for surgical planning.

Studies performed in accordance with our scanning protocol (Table 1) were more sensitive than the DDD-CT studies and could be completed efficiently within an acceptable scan

time. Only one scan was sufficiently degraded by motion as to be unacceptable in spite of a study population with varying degrees of neurologic impairment, although this high percentage of acceptable MR studies may be skewed by the possibility that obviously uncooperative or impaired patients were screened out. Several approaches can be taken to increase the likelihood of obtaining a successful MR study in this population. A complete noncontrast T1-weighted axial scan can often be omitted unless a specific question of hemorrhage vs metastasis is clinically important. The occasional problem in differentiating hemorrhage from enhancement can generally be resolved on the T2-weighted image [10]. Other options include a repeat noncontrast T1-weighted scan at a later date, a noncontrast CT to exclude acute hemorrhage, or a very delayed T1-weighted scan (i.e., several hours after contrast administration), assuming that T1 shortening from enhancement may in some cases diminish while hemorrhage would be stable over a period of several hours [6, 8]. Higher field strength magnets, flow compensation, and improved technology in general result in improved images in less time per MR sequence. Thus MR degradation by motion of uncooperative or unstable patients is reduced. On one hand, studies to date have suggested that a brief delay after contrast enhancement is important for optimal lesion detection [6, 8, 10]; thus, the primary effect of faster MR sequences might be reduced motion rather than a shortened MR examination time. On the other hand, the increased signal-to-noise ratio and shorter echo times with technological improvements in scanning might lessen the advantages of delayed postcontrast images described with earlier-generation MR technology [6, 8].

An efficient MR scanning protocol is important for patient tolerance, motion reduction, and scan time, with potential reductions in examination cost. T2-weighted imaging after contrast administration and elimination of a routine precontrast T1-weighted axial sequence permit a total scan time of about 20–30 min without significant loss of information or degradation of T2-weighted images. Higher doses of gadopentetate dimeglumine may prove advantageous for detection of subtle lesions, although this requires further evaluation of cost-effectiveness and toxicity ([24] and Haustein et al., paper presented at the annual meeting of the Society of Magnetic Resonance in Medicine, New York, August 1990). We agree with previous investigators that the T2-weighted sequence should routinely be a part of the MR examination for suspected metastases [7–10]. It serves as an important complementary sequence for recognition of other lesions (infarct, sequelae of therapy, and vasogenic edema), and rarely demonstrates subtle lesions that might be overlooked otherwise. Earlier investigators have not identified clinically significant degradation of T2-weighted images attributable to gadopentetate dimeglumine given in pharmacological doses [2, 4, 6]. If noticeable T2 shortening due to marked paramagnetic contrast enhancement did occur, this might result in improved definition of the metastatic focus apart from high signal intensity of adjacent vasogenic edema. In the uncommon event that a lesion is rendered isointense with normal parenchyma by T2 shortening, the surrounding abnormal signal from edema on proton-density or T2-weighted images and/or enhancement on T1-weighted images should be sufficient to avoid overlooking the lesion [8].

Although our study includes only patients with equivocal findings on DDD-CT, the implications of our results require careful consideration. Our study does not address the role of contrast MR in the patient with an unequivocally normal DDD-CT; in this population the diagnostic yield of contrast MR might be lower, particularly in centers performing extensive routine screening or frequent follow-up studies. Those patients with no lesions on either examination, those with multiple lesions on both examinations, and those with one lesion on DDD-CT who are not candidates for surgical resection could be adequately assessed with either technique. Although contrast MR in this study proved helpful for confirming the number and location of lesions, this additional information may prove essential for only a limited patient population; that is, candidates for surgical resection. The advantage of detecting additional lesions in the neurosurgical candidate is controversial, since the data supporting surgical resection is based on contrast CT findings of a solitary lesion [15]. Whether detection of additional lesions on MR that are undetected on contrast-enhanced CT predicts reduced survival or results in better patient selection for surgical resection requires further study.

Clinical settings in which DDD-CT may be preferable to contrast-enhanced MR include the patient with acutely altered mental status in order to optimize sensitivity to acute hemorrhage (noncontrast) and minimize motion and scanning time; patients having follow-up studies for known multiple metastases; patients with contraindications to MR or to paramagnetic contrast; and patients who primarily have bone metastases. Although few leptomeningeal/dural and/or bone lesions occurred in this study, other reports suggest advantages of contrast MR for leptomeningeal disease, and limitations of contrast MR compared with noncontrast MR for detecting bone lesions [25]. CT or radionuclide bone scan are the preferable imaging techniques to establish the presence and location of bone metastases, although MR with and without contrast with fat suppression may prove equivalent or superior for anatomic detail (Dillon et al., paper presented at the annual meeting of the American Society of Neuroradiology, Los Angeles, March 1990).

We conclude that contrast-enhanced MR is substantially more sensitive than DDD-CT for detection of cerebral metastases in patients with equivocal DDD-CT examinations. Postcontrast T2-weighted images followed by delayed T1-weighted images are a reasonable compromise to achieve more efficient and shorter MR scan times. Contrast MR demonstrated additional lesions in 37% of patients who had solitary or equivocal lesions on DDD-CT; thus, contrast MR may prove important in the selection of patients for surgical resection. This technique also provided superior anatomic localization and demonstrated both supra- and infratentorial lesions that were not shown on DDD-CT images. In patients with equivocal DDD-CT findings for cerebral metastases, contrast-enhanced MR is superior to DDD-CT for lesion detection; however, the ultimate significance of this improved sensitivity requires further study to elucidate its impact on the choice of treatment method, the patient's quality of life and

rate of survival, and the economic ramifications of greater use of MR imaging.

ACKNOWLEDGMENTS

The authors acknowledge the assistance of Francine Hollowell, Sandy Sullivan, and photographers Roz Vecchio and Jack Kearse in the preparation of this manuscript.

REFERENCES

1. Russell DJ, Rubinstein LJ. Secondary tumors of the nervous system. In: *Pathology of tumors of the nervous system*, 5th ed., Baltimore: Williams & Wilkins, **1989**:825–841
2. Carr DH, Brown J, Bydder GM, et al. Gadolinium-DTPA as a contrast agent in MRI: initial clinical experience in 20 patients. *AJR* **1984**;143: 215–224
3. Runge VM, Schorner W, Niendorf HP, et al. Initial clinical evaluation of gadolinium DTPA for contrast-enhanced magnetic resonance imaging. *Magn Reson Imaging* **1985**;3:27–35
4. Niendorf HP, Laniado M, Semmler W, Schorner W, Felix R. Dose administration of gadolinium-DTPA in MR imaging of intracranial tumors. *AJNR* **1987**;8:803–815
5. Claussen C, Laniado M, Schorner W, et al. Gadolinium-DTPA in MR imaging of glioblastomas and intracranial metastases. *AJNR* **1985**;6: 669–674
6. Schorner W, Laniado M, Niendorf HP, Schubert C, Felix R. Time-dependent changes in image contrast in brain tumors after gadolinium-DTPA. *AJNR* **1986**;7:1013–1020
7. Healey ME, Hesselink JR, Press GA, Middleton MS. Increased detection of intracranial metastases with intravenous Gd-DTPA. *Radiology* **1987**; 165:619–624
8. Russell EJ, Geremia GK, Johnson CE, et al. Multiple cerebral metastases: detectability with Gd-DTPA-enhanced MR imaging. *Radiology* **1987**; 165:609–617
9. Sze G, Shin J, Drol G, Johnson C, Liu D, Deck MDF. Intraparenchymal brain metastases: MR imaging versus contrast-enhanced CT. *Radiology* **1988**;168:187–194
10. Sze G, Milano E, Johnson C, Heier L. Detection of brain metastases: comparison of contrast-enhanced MR with unenhanced MR and enhanced CT. *AJNR* **1990**;11:785–791
11. Shalen PR, Hayman LA, Wallace S, Handel SF. Protocol for delayed contrast enhancement in computed tomography of cerebral neoplasia. *Radiology* **1981**;139:397–401
12. Hayman LA, Evans RA, Hinck VC. Delayed high iodine dose contrast computed tomography. *Radiology* **1980**;136:677–684
13. Davis JM, Davis KR, Newhouse J, Pfister RC. Expanded high iodine dose in computed cranial tomography: a preliminary report. *Radiology* **1979**; 131:373–380
14. Posner JB. Surgery for metastases to the brain. *N Engl J Med* **1990**;322:544–545
15. Patchell RA, Tibbs PA, Walsh JW, et al. A randomized trial of surgery in the treatment of single metastases to the brain. *N Engl J Med* **1990**;322:494–500
16. Zimmerman RD, Heier LA, Snow RB, Liu DPC, Kelly AB, Deck MDF. Acute intracranial hemorrhage: intensity changes on sequential MR scans at 0.5 T. *AJNR* **1988**;9:47–57
17. Lee YY, Glass JP, Geoffray A, Wallace S. Cranial computed tomographic abnormalities in leptomeningeal metastasis. *AJNR* **1984**;5:559–563
18. Woodruff WW, Djang WT, McLendon RE, Heinz ER, Voorhees DR. Intracerebral malignant melanoma: high-field-strength MR imaging. *Radiology* **1987**;165:209–213
19. Atlas SW, Grossman RI, Gomori JM, et al. Imaging of intracranial metastatic melanoma. *J Comput Assist Tomogr* **1987**;11:577–582
20. Davis PC, Friedman NC, Fry SM, Malko JA, Hoffman JC, Braun IF. Leptomeningeal metastasis: MR imaging. *Radiology* **1987**;163:449–454
21. Gomori JM, Grossman RI, Goldberg HI, Zimmerman RA, Bilaniuk LT. Intracranial hematomas: imaging by high field MR. *Radiology* **1985**;157:87–93
22. Kondziolka D, Bernstein M, Resch L, et al. Significance of hemorrhage into brain tumors: clinicopathological study. *J Neurosurg* **1987**;67:852–857
23. Richardson DN, Elster AD, Williams DW III. Gd-DTPA–enhanced MR images: accentuation of vascular pulsation artifacts and correction by using gradient-moment nulling (MAST). *AJNR* **1990**;11:209–210
24. Goldstein H, Kashanian FK, Blumetti RF, Holyoak WL, Hugo FP, Blumenfield DM. Safety assessment of gadopentetate dimeglumine in U.S. clinical trials. *Radiology* **1990**;174:17–24
25. West MS, Russell EJ, Breit R, Sze G, Kim KS. Calvarial and skull base metastases: comparison of nonenhanced and Gd-DTPA-enhanced MR images. *Radiology* **1990**;174:85–91