AJNR

MR demonstration of leukoencephalopathy associated with mitochondrial encephalomyopathy: case report.

F S Sandhu and W P Dillon

AJNR Am J Neuroradiol 1991, 12 (2) 375-379
http://www.ajnr.org/content/12/2/375.citation

MR Demonstration of Leukoencephalopathy Associated with Mitochondrial Encephalomyopathy: Case Report

Fatejeet S. Sandhu[1] and William P. Dillon

The mitochondrial encephalomyopathies are a heterogeneous group of disorders characterized by mitochondrial dysfunction that produce multisystem symptoms. This disorder affects both the central and peripheral nervous systems, skeletal muscles, heart, endocrine glands, gastrointestinal tract, hematopoietic system, and kidneys (Table 1) [1]. Patients with mitochondrial encephalomyopathy can be divided into two large groups [1]. In the first group, severe mitochondrial dysfunction results in patients who are usually quite ill at birth, who deteriorate rapidly, and who die soon thereafter. Included in this group of mitochondrial disorders are Alper, Canavan, Leigh, Menke, and Zellweger syndromes. In the second group of patients the individual appears normal at birth, with progressive neurologic deficits developing later. Included in this group are Kearns-Sayre syndrome (KSS); mitochondrial encephalomyopathy, lactic acidosis, and strokelike episodes (the MELAS syndrome); and myoclonic epilepsy with ragged red fibers (MERRF). Clinically, patients in this latter group commonly present with progressive external ophthalmoplegia plus abnormalities in one or more of the other systems. The diagnosis can be established by muscle biopsy, which characteristically shows ragged red fibers with the Gomori trichrome stain, reflecting abnormal accumulation of mitochondria in the muscle fibers [2].

Most of the literature on mitochondrial encephalomyopathy discusses the clinical, pathologic, genetic, and biochemical abnormalities associated with this disorder. A limited number of articles describe the neuroradiologic manifestations of mitochondrial encephalomyopathy [3–13]. We report a patient with mitochondrial encephalomyopathy in whom the CNS abnormalities are characterized by increased signal in the white matter on T2-weighted MR images. Because of the rarity, complexity, and varied clinical manifestations of mitochondrial encephalomyopathy, this article will not only discuss the radiologic features of this disorder but also will review the clinical features and provide pertinent background information on the biochemical and genetic aspects.

Case Report

A 65-year-old woman was referred for evaluation of chronic ophthalmoplegia as well as weakness and numbness of her legs. At the age of 28, she developed double vision and ptosis for which she was prescribed glasses and noted to have "muscle disease" of her extraocular muscles. In her mid thirties, the patient developed recurrent episodes of pancreatitis that eventually resulted in pancreatic insufficiency.

At age 37 she noted increasing weakness, worse with exertion, in her proximal legs and decreased sensation in her distal lower extremities. Neurologic examination at that time revealed minimal upper- and lower-extremity proximal muscle weakness as well as slightly decreased sensation. Also noted at that time was nearly complete paralysis of the extraocular muscles with preserved pupillary function. The remainder of the cranial nerves were intact. Higher cerebral function was normal. There was no history of loss of consciousness, strokes, or seizures.

Since the initial evaluation, there has been minimal but steady progression of her symptoms. The most recent evaluation at age 65 found nearly complete paralysis of all muscles below the knee with absent deep tendon reflexes. In addition, sensation was absent below the knee. The patient had severe extraocular muscle involvement with nearly frozen eyes and severe ptosis.

Contrast-enhanced CT at this time showed diffuse decreased density in the deep white matter without any enhancement after contrast administration (Figs. 1A and 1B). Despite the abnormalities noted on CT, there were no signs of cerebral dysfunction. The patient was referred to our institution for further evaluation. Electromyographic studies were consistent with sensory motor polyneuropathy and decreased velocity suggestive of a demyelinating process. As part of her workup, she underwent an MR examination, which identified increased signal in the white matter tracts on T2-weighted images (Figs. 1C–1F) without significant atrophy or any areas of focal abnormality. Muscle biopsy identified ragged red fibers. Electron microscopy demonstrated an increase in the number and size of the mitochondria. These findings confirmed the clinical diagnosis of mitochondrial encephalomyopathy, specifically ophthalmoplegia-plus or oculocraniosomatic neuromuscular disease with ragged red fibers, a KSS variant.

Discussion

The term mitochondrial encephalomyopathy describes mitochondrial disease in which both the muscle and the CNS are involved, but, in contrast to mitochondrial myopathy, nervous system dysfunction dominates the clinical picture [1]. This is a heterogeneous disorder with multisystem involvement and variable clinical presentations (Table 1) [1, 14].

Received July 17, 1990; returned for revision September 7, 1990; revision received October 16, 1990; accepted October 22, 1990.

[1] Both authors: Department of Radiology, Box 0628, Neuroradiology Section, L-371, University of California, San Francisco, 505 Parnassus Ave., San Francisco, CA 94143. Address reprint requests to W. P. Dillon.

TABLE 1: Systems Involved in Mitochondrial Encephalomyopathy with Clinical and Laboratory Features[a]

System	Clinical/Laboratory Features
CNS	Dementia, seizures, strokelike episodes, hearing loss, central hypoventilation
Muscle and peripheral nervous	Myopathy (ptosis, ophthalmoplegia, proximal muscle weakness), peripheral neuropathy
Skeletal	Growth retardation, kyphosis
Heart	Cardiomyopathy, heart block
Retina	Pigmentary degeneration
Liver	Abnormal liver function tests
Endocrine/metabolic	Elevated lactic acid in CSF and blood, glucose intolerance, hormonal insufficiency

[a] Modified from Peterson et al. [1].

Depending on the characteristic dominant clinical features, the patient can be subclassified as having one of the following syndromes: KSS, MELAS, or MERRF. Patients with KSS have progressive external ophthalmoplegia, pigmentary degeneration of the retina, and defects in the cardiac conduction secondary to degeneration of the His-Purkinje system [15]. However, all of these features do not have to be present for the patient to be classified as having KSS [16]. In addition, patients with KSS commonly have endocrinopathies (hypoparathyroidism, hypothyroidism, growth hormone deficiency), glucose intolerance, and elevated CSF protein. Patients with MELAS have associated generalized seizures, headache, and recurrent strokelike episodes [17]. Most patients with MELAS develop normally until they experience intermittent nausea and vomiting and headache followed by their first strokelike episode, which commonly results in transient cortical blindness, hemianopia, focal paresis, or paralysis. Angiography does not reveal any significant vascular disease, and the strokelike lesions identified on imaging studies do no correspond to a classic vascular territory. Patients with MERRF have myoclonic epilepsy, ataxia, and muscle weakness with easy fatigability [18]. Although these distinct syndromes have been described, several investigators emphasize that it may be difficult to classify all patients with mitochondrial encephalomyopathy as having a particular syndrome, as there may be a marked overlap of symptoms, especially in the later stages of disease [1, 14, 19]. This appears to be the case in our patient, as she had external ophthalmoplegia but no cardiac conduction abnormalities or retinitis.

This wide variability of clinical expression of mitochondrial encephalomyopathy likely results from the many unique characteristics of the mitochondria themselves. Perhaps the most unique characteristic of mitochondria is that they contain their own DNA (mtDNA) [20]. This mtDNA codes for 13 of the 63 polypeptides that are components of the respiratory chain [21]. The remaining 50 subunits involved in oxidative phosphorylation are synthesized from nuclear DNA. In addition, all of the mtDNA is inherited from the mother, as the ovum contributes all the mitochondria at fertilization while the paternal sperm does not contribute any mitochondria to the developing zygote. Thus, there is a nonmendelian maternal inheritance in mitochondrial encephalomyopathy such that offspring of affected women will express the disease, while offspring of affected men will not inherit the disorder. There is also variability in the extent of expression of the abnormal mtDNA with resultant variability in the severity of clinical symptoms and the distribution of symptoms within the organ systems [22]. This process is called replicative segregation and works as follows. There are thousands of copies of mtDNA in each cell with a mixture of normal and abnormal mtDNA. During replication of the cell, unlike nuclear DNA, there is random partition of the two populations of mtDNA such that expression of the abnormal mtDNA and its resultant abnormal protein will depend on the proportion of abnormal mtDNA in a particular cellular lineage. Additionally, different tissues will be affected unequally depending on the extent to which the individual tissue relies on mitochondrial energy production [21]. Thus, the clinical symptoms will depend on the amount of abnormal mtDNA in a particular tissue and the degree of reliance on mitochondrial energy production in that particular tissue.

Mitochondrial encephalomyopathy is a multisystem disorder with variable clinical expression that results from mitochondrial dysfunction with subsequent abnormal energy production via oxidative phosphorylation. Mitochondria are the subcellular organelles responsible for energy production. The respiratory chain located in the mitochondria produces energy via the transfer of reducing equivalents from nicotinamide-adenine dinucleotide hydrogen (NADH) and succinate to molecular oxygen. The respiratory chain consists of four multienzyme complexes that are embedded in the inner mitochondrial membrane and two low-weight reduction-oxidation carriers, coenzyme Q and cytochrome *c*. These multienzyme complexes involved in oxidative phosphorylation are called complex I (NADH-coenzyme Q oxidoreductase), complex II (succinate–coenzyme Q oxidoreductase), complex III (coenzyme Q–cytochrome *c* oxidoreductase), and complex IV (cytochrome *c* oxidase). The energy generated by these oxidation-reduction reactions is then stored as an electrochemical proton gradient across the membrane, which can then be coupled to the synthesis of adenosine triphosphate from adenosine diphosphate and inorganic phosphate by adenosine triphosphate synthetase (complex V) [23].

It is postulated that various enzymatic abnormalities in the oxidative phosphorylation cycle of the respiratory chain are the biochemical basis for mitochondrial encephalomyopathy [2]. In the MELAS syndrome, a deficiency of subunits of complex I has been described [24]. Other investigators have

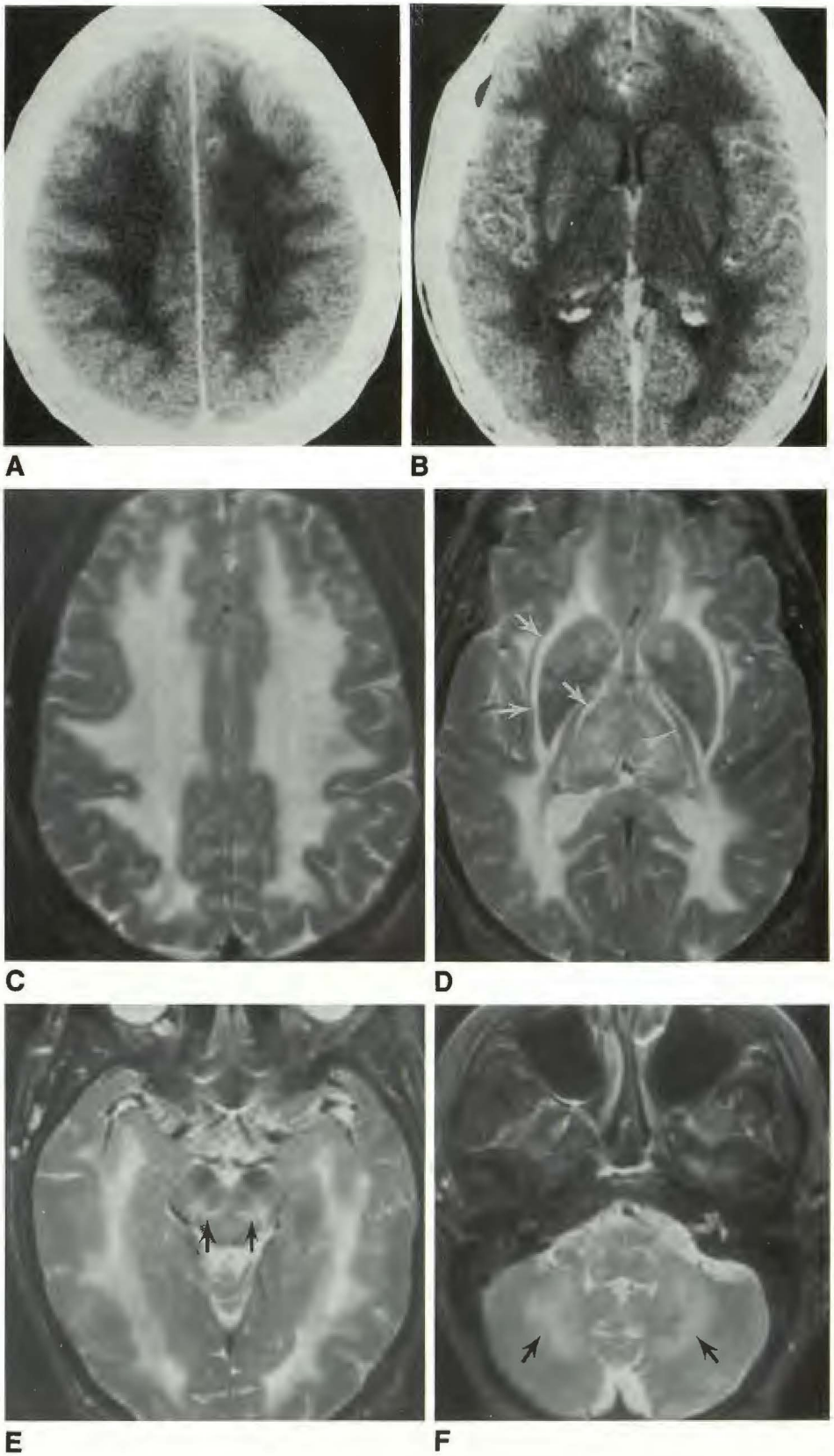

Fig. 1.—*A* and *B*, Axial contrast-enhanced CT scans at level of cerebral white matter (*A*) and lateral ventricles (*B*) show symmetric low density throughout deep frontal and parietal white matter.

C–F, Axial T2-weighted MR images, 2800/80/1 (TR/TE/excitation), through central white matter (*C*), at lateral ventricles (*D*), through midbrain (*E*), and in posterior fossa (*F*). Diffuse symmetric increased signal is present within deep white matter (*C*), internal and external capsule (*D*, *arrows*), medial lemniscus (*E*, *arrows*), and deep cerebellar white matter (*F*, *arrows*). However, note sparing of corpus callosum, part of internal capsule (*arrowhead*), and white matter connecting tracts within basal ganglia (*D*).

demonstrated deletions of mtDNA in patients with KSS or KSS variants [25, 26]. Another group demonstrated abnormalities in the function of complex I and complex IV in a family with MERRF [21]. Thus, it is obvious that an mtDNA mutation or deletion leads to production of an abnormal respiratory chain peptide that results in deficient mitochondrial energy production. As discussed, the specific clinical picture will depend on the degree of enzymatic abnormality and the particular tissue affected.

There is limited experience in the imaging of CNS changes associated with mitochondrial encephalomyopathy. CT findings in MELAS include focal low-density areas in a nonvascular distribution commonly involving the parietal or occipital lobe, lacunar infarcts, ventricular dilatation, and cerebral or cerebellar atrophy. Of note, calcification within the basal ganglia also occurs but appears to predominate in KSS [6, 7]. However, up to 50% of patients with mitochondrial encephalomyopathy may show no neuroradiologic abnormalities [6]. Of note, in two articles describing CT findings in mitochondrial cytopathy, one of the significant appearances was the finding of symmetric low density in the subcortical white matter in three of 13 and five of 18 patients, respectively [3, 4]. This appearance corresponds to the CT findings in our patient. The appearance of diffusely increased signal in the white matter on T2-weighted MR images in our report likely corresponds to the CT appearance of symmetric low-density white matter seen on CT.

As would be expected, many of the MR findings parallel those of CT. Generalized cerebral and cerebellar atrophy have been noted [6]. Cerebral atrophy, predominantly in the parietooccipital areas, with resultant ventricular dilatation and without evidence of focal signal abnormalities, has also been described [9]. One of the more common findings is increased signal in the parietooccipital or temporal lobe on T2-weighted images that involves both gray and white matter in a nonvascular distribution [6, 8, 10]. Of note, two case reports describe abnormal signal in the cortical gray matter of the parietal and occipital lobes on T2-weighted images, with reversion to normal signal intensity on sequential studies 2–4 weeks after the initial event [11, 12]. Increased signal on T2-weighted images has also been noted in the basal ganglia as well as in the cerebellum [6]. While calcification in the basal ganglia is a dominant feature on CT, it has not been appreciated on MR [6]. In one report describing the MR findings in KSS [13], increased signal on T2-weighted images was described in the dentate nuclei, superior cerebellar peduncles, substantia nigra, thalami, pars medialis of both globi palladi, and white matter around the central sulcus. Although enhancement may be noted on enhanced CT images [6, 8], gadopentetate dimeglumine was not administered in any of the articles cited; thus, we do not know if there is enhancement on MR images.

The etiology of white matter abnormalities is unknown. Autopsy studies of the CNS in patients with KSS have identified spongiform changes predominantly of the deep cerebral and cerebellar white matter [27, 28]. In an infant with mitochondrial myopathy in whom CT demonstrated low-density white matter, autopsy identified patchy areas of demyelination with ballooning and fragmentation of the myelin sheaths [29]. Another study of two patients with MELAS syndrome demonstrated extensive microvacuolation of the inner myelin sheath within the spinal cord with stripping of the myelin lamella by macrophages [30]. These investigators postulated that demyelination, probably secondary to the degeneration of oligodendrocytes, occurs in MELAS. Experimental evidence provides further support for demyelination as the cause of the abnormal signal intensities on MR imaging and low-density areas on CT. Cuprizone, a chelating agent that inhibits mitochondrial metabolism, has been shown to induce demyelination secondary to the degeneration of oligodendrocytes [31]. It is possible that a high-energy requirement is necessitated by the highly ordered myelin sheaths and the support of multiple axonal myelin sheaths by each oligodendrocyte. As a result of the abnormal energy production secondary to mitochondrial dysfunction, the oligodendrocyte may not be able to meet its required energy demands and demyelination may ensue. This hypothesis is consistent with the diffuse white matter abnormalities localized to specific tracts observed in our patient.

Another explanation for the white matter changes is diffuse small-vessel ischemia. An autopsy with ultrastructural analysis of cerebral blood vessels in two patients with MELAS syndrome identified a marked increase in the number of mitochondria in the smooth muscle and endothelial cells in the pial arterioles and small arteries up to 250 μm in diameter [32]. Of note, these affected vessels are intimately involved in the autoregulation of cerebral blood flow. With increased cerebral metabolic activity, the affected vessels may not dilate appropriately, resulting in cerebral ischemia. Such "mitochondrial angiopathy" may explain the recurrent strokelike episodes that patients with mitochondrial encephalomyopathy can experience. However, if ischemia causes white matter changes, more focal gray matter abnormalities would be expected than were found in our case.

Diffuse symmetric increased signal in the white matter on T2-weighted images is one of the varied manifestations of mitochondrial encephalomyopathy. However, these changes are nonspecific and may be seen in other dysmyelinating syndromes such as the metabolic leukodystrophies (adrenoleukodystrophy and metachromatic leukodystrophy). Nonetheless, since the clinical manifestations of mitochondrial encephalomyopathy can be so variable, the finding of such white matter abnormalities should lead one to consider mitochondrial encephalomyopathy in the differential diagnosis of diffuse or confluent white matter hyperintensity on T2-weighted MR images.

REFERENCES

1. Peterson PL, Martens ME, Lee CP. Mitochondrial encephalomyopathies. *Neurol Clin* **1988**;6:529–544
2. DiMauro S, Bonilla E, Zeviani M, et al. Mitochondrial myopathies. *Ann Neurol* **1985**;17:521–538
3. Egger J, Kendall BE. Computed tomography in mitochondrial cytopathy. *Neuroradiology* **1981**;22:73–78
4. Bertorini T, Engel WK, DiChiro G, et al Leukoencephalopathy in oculocraniosomatic neuromuscular disease with ragged-red fibers. *Arch Neurol*

1978;35:643–647
5. Seigel RS, Seeger JF, Gabrielsen TO, et al. Computed tomography in oculocraniosomatic disease (Kearns-Sayre syndrome). *Radiology* **1979**; 130:159–164
6. Allard JC, Tilak S, Carter AP. CT and MR of MELAS syndrome. *AJNR* **1988**;9:1234–1238
7. Hasuo K, Tamura S, Yasumori K, et al. Computed tomography and angiography in MELAS (mitochondrial myopathy, encephalomyopathy, lactic acidosis, and stroke-like episodes): report of 3 cases. *Neuroradiology* **1987**;29:393–397
8. Rosen L, Phillips S, Enzmann D. Magnetic resonance imaging in MELAS syndrome. *Neuroradiology* **1990**;32:168–171
9. DeVolder A, Ghilain S, DeBarsy TH, et al. Brain metabolism in mitochondrial encephalomyopathy: a PET study. *J Comput Assist Tomogr* **1988**;12: 854–857
10. Suzuki T, Koizumi J, Shiraishi H, et al. Mitochondrial encephalomyopathy (MELAS) with mental disorder: CT, MRI and SPECT findings. *Neuroradiology* **1990**;32:74–76
11. Taverni N, DelPozzo G, Arnetoli G, et al. Diagnosis and follow-up of mitochondrial encephalomyopathy: CT and MR studies. *J Comput Assist Tomogr* **1988**;12:696–697
12. Abe K, Invi T, Hirono N, et al. Fluctuating MR images with mitochondrial encephalomyopathy, lactic acidosis, stroke-like syndrome (MELAS). *Neuroradiology* **1990**;32:77
13. Demange P, Gia HP, Kalifa G, et al. MR of Kearns-Sayre syndrome. *AJNR* **1989**;10:591
14. Petty RKH, Harding AE, Morgan-Hughes JA. The clinical features of mitochondrial myopathy. *Brain* **1986**;109:915–938
15. Kearns T, Sayre G. Retinitis pigmentosa, external ophthalmoplegia, and complete heart block: unusual syndrome with histologic study in one of two cases. *Arch Ophthalmol* **1958**;60:280–289
16. Berenberg RA, Pellock J, DiMauro S, et al. Lumping or splitting—"ophthalmoplegia-plus" or Kearns-Sayre syndrome? *Ann Neurol* **1977**;1:37–54
17. Pavlakis S, Phillips P, DiMauro S. Mitochondrial myopathy, encephalomyopathy, lactic acidosis and stroke-like episodes: a distinctive clinical syndrome. *Ann Neurol* **1984**;16:481–488
18. Garcia-Silva M, Accardi J, Goutieres J. The syndrome of myoclonic epilepsy with ragged-red fibers: report of a case and review of the literature. *Neuropediatrics* **1987**;18:200–204
19. Egger J, Lake BD, Wilson J. Mitochondrial cytopathy: a multisystem disorder with ragged-red fibers on muscle biopsy. *Arch Dis Child* **1981**; 56:741–752
20. Attardi G. The elucidation of the human mitochondrial genome: a historical perspective. *Bioessays* **1986**;5:34–39
21. Wallace DC, Zheng X, Lott MT, et al. Familial mitochondrial encephalomyopathy (MERRF): genetic, pathophysiological, and biochemical characterization of mitochondrial DNA disease. *Cell* **1988**;55:601–610
22. Wallace DC. Maternal genes: mitochondrial diseases. *Birth Defects* **1987**;23:137–190
23. Lee CP, Martens M. Mitochondrial respiration and energy metabolism in muscle. In: Engel A, Benker B, *Myology*. New York: McGraw-Hill **1986**:643–671
24. Ichiki T, Tanaka M, Nishikimi M, et al. Deficiency of subunits of complex I and mitochondrial encephalomyopathy. *Ann Neurol* **1988**;23:287–294
25. Moraes CT, DiMauro S, Zeviani M, et al. Mitochondrial DNA deletions in progressive external ophthalmoplegia and Kearns-Sayre syndrome. *N Engl J Med* **1989**;320:1293–1299
26. Zeviani M, Moraes CT, DiMauro S, et al. Deletions of mitochondrial DNA in Kearns-Sayre syndrome. *Neurology* **1988**;38:1339–1346
27. Horowitz SJ, Roessmann V. Kearns-Sayre syndrome with hypoparathyroidism. *Ann Neurol* **1978**;3:513–518
28. Daroff RB, Solitare GB, Pincus JH, et al. Spongiform encephalopathy with chronic progressive external ophthalmoplegia. *Neurology* **1966**;16: 161–169
29. Egger J, Kendall BE, Erdohzai M, et al. Involvement of the central nervous system in congenital muscular dystrophies. *Dev Med Child Neurol* **1983**;25:32–42
30. Ohara S, Ohama G, Takahashi H, et al. Alterations of oligodendrocytes and demyelination in the spinal cord of patients with mitochondrial encephalomyopathy. *J Neurol Sci* **1988**;86:19–29
31. Blakemore WF. Demyelination of the superior cerebellar pednucle in the mouse induced by Cuprizone. *J Neurol Sci* **1973**;20:63–72
32. Ohama E, Ohara S, Ikuta F, et al. Mitochondrial angiopathy in cerebral blood vessels of mitochondrial encephalomyopathy. *Acta Neuropathol* (Berl) **1987**;74:226–233