Are your MRI contrast agents cost-effective?
Learn more about generic Gadolinium-Based Contrast Agents.
FRESENIUS KABI
caring for life

AJNR

Physiologic mechanisms underlying the delayed delta sign.

J L Ulmer and A D Elster

AJNR Am J Neuroradiol 1991, 12 (4) 647-650
http://www.ajnr.org/content/12/4/647

This information is current as of April 19, 2024.

Physiologic Mechanisms Underlying the Delayed Delta Sign

John L. Ulmer[1]
Allen D. Elster

The negative or empty delta sign is considered to be nearly pathognomonic of superior sagittal sinus thrombosis on contrast-enhanced CT scans. We describe a visually similar sign, seen in five (10%) of 50 patients who had delayed cranial CT scans performed at intervals greater than 30 min after injection of contrast material. This new sign (which we call the delayed delta sign) closely mimics the classic negative delta sign and may thus represent a potential visual pitfall leading to an erroneous diagnosis of sagittal sinus thrombosis if only postcontrast images are viewed. The physiologic mechanisms underlying the appearance of the delayed delta sign are discussed.

***AJNR* 12:647–650, July/August 1991**

The diagnosis of sagittal sinus thrombosis is usually clear from its clinical and radiologic presentation [1]. In particular, the negative delta or empty triangle sign, first described by Buonanno et al. in 1978 [2], has proved to be a reliable CT finding in this disorder (Fig. 1). Recently, however, we observed a visually similar appearance of the superior sagittal sinus in several patients without clinical evidence of sinus thrombosis who had undergone cranial CT scanning at intervals longer than 30 min following contrast infusion. Because this normal appearance of the sagittal sinus on delayed CT scans mimicked the negative delta sign of true sinus thrombosis, we named this appearance the delayed delta sign. We then set out to determine the rate of occurrence of this sign prospectively and to elucidate the physiologic mechanisms responsible for its appearance.

Subjects and Methods

Cranial CT scanning with and without IV contrast infusion was performed prospectively in 100 patients without clinical indications of sinovenous occlusive disease over a 2-month period. The patients, 51 males and 49 females, ranged in age from 3 to 92 years (mean, 50 years). Following the precontrast study, each patient received contrast material (Omnipaque 300, Winthrop Pharmaceuticals, New York, NY) by rapid drip IV infusion at a dose of 0.5 ml/kg. Cranial CT scanning was then resumed between 1 and 165 min after completion of the infusion. Patients receiving delayed scans were principally those referred for suspected metastatic disease. Patient accrual for this study was completed when technically satisfactory CT scans were obtained in 50 patients studied within 30 min of infusion and 50 patients studied later than 30 min after infusion.

The scans were evaluated by two experienced radiologists who were blinded to knowledge of the time interval between infusion and scanning. Working independently, the readers visually assessed the relative radiologic densities of blood within the superior sagittal sinus and that of the adjacent dural membranes. Each sinus was then categorized by consensus between the two radiologists as appearing either (1) isodense or nearly isodense with the adjacent dura or (2) definitely hypodense relative to the adjacent dura. From this second group of studies the readers selected a subset of cases in which the sagittal sinus demonstrated central marked hypodensity compared with the dura, which potentially mimicked the classic negative delta sign. This subset, composed predominantly of cases scanned later

Received November 19, 1990; revision requested January 30, 1991; revision received February 13, 1991; accepted February 19, 1991.

[1] Both authors: Department of Radiology, Bowman Gray School of Medicine, 300 S. Hawthorne Rd., Winston-Salem, NC 27103. Address reprint requests to A. D. Elster.

0195-6108/91/1204-0647
© American Society of Neuroradiology

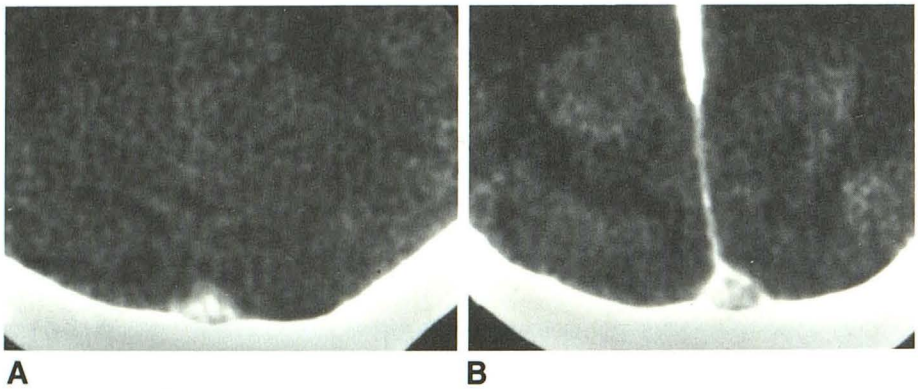

Fig. 1.—Pre- (*A*) and postcontrast (*B*) CT images of superior sagittal sinus in a patient with angiographically proved acute sinus thrombosis.

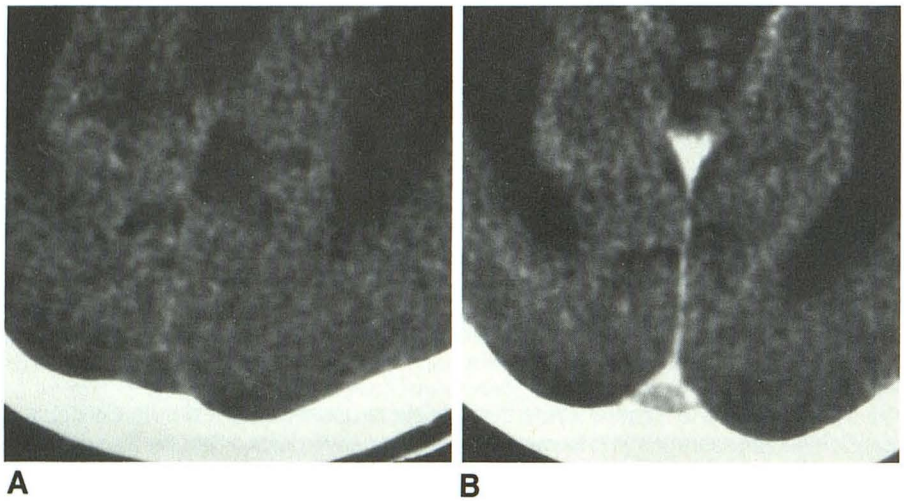

Fig. 2.—Pre- (*A*) and postcontrast (*B*) delayed CT images of superior sagittal sinus region in a patient without sinus thrombosis. Note similarity of true negative delta sign (Fig. 1B) and delayed delta sign (Fig. 2B) when only postcontrast images are compared.

than 30 min following contrast infusion, were thus said to demonstrate a delayed delta sign.

Results

Visibly apparent hypodensity of the superior sagittal sinus relative to dura was directly related to the time interval between contrast injection and CT scanning. This phenomenon was seen in only four (8%) of 50 patients scanned within 30 min of contrast infusion, while it was noted in 29 (58%) of 50 cases scanned later than 30 min after infusion. By consensus of the two readers, in five of these cases the sagittal sinus was sufficiently hypodense relative to dura that potential confusion of this normal appearance of the sinus on delayed images (delayed delta sign) with a true negative delta sign was deemed possible if only postcontrast images were considered. Representative examples of these delayed delta signs are presented in Figures 2 and 3.

To verify the time dependence of the appearance of sinus hypodensity relative to dura, a patient volunteer was scanned at successive intervals from 5 to 55 min following contrast administration. Representative images of the sagittal sinus from this study are shown in Figure 4. A graph of the relative radiologic densities of the sinus and dura as a function of time since injection is presented as Figure 5.

On precontrast scans the dural margins of the superior sagittal sinus demonstrated greater attentuation than did the blood within the sinus. Immediately after contrast administration, marked intravascular enhancement occurred and a reversal of the relative densities between sinus and dura was recorded. By 45–55 min, however, the dura again became denser than the sinus, approaching the precontrast differential (≈8–10 H).

The differential densities between sinus and dura were also measured before and after contrast infusion in each of the five cases in which delayed delta signs were observed. In each case both the sinus and the dura demonstrated enhancement on the delayed postcontrast images, confirming the patency of the sinus. The differential densities between sinus and dura, however, were similar on the precontrast and delayed postcontrast studies. This suggests that equilibrium in the distribution of contrast material between the intravascular and interstitial phases has occurred by the time of the delayed scans, allowing the normal density differences between sinus and dura to be observed again.

Discussion

Sinovenous occlusion occurs in patients of all ages and is associated with significant morbidity and mortality [1]. Char-

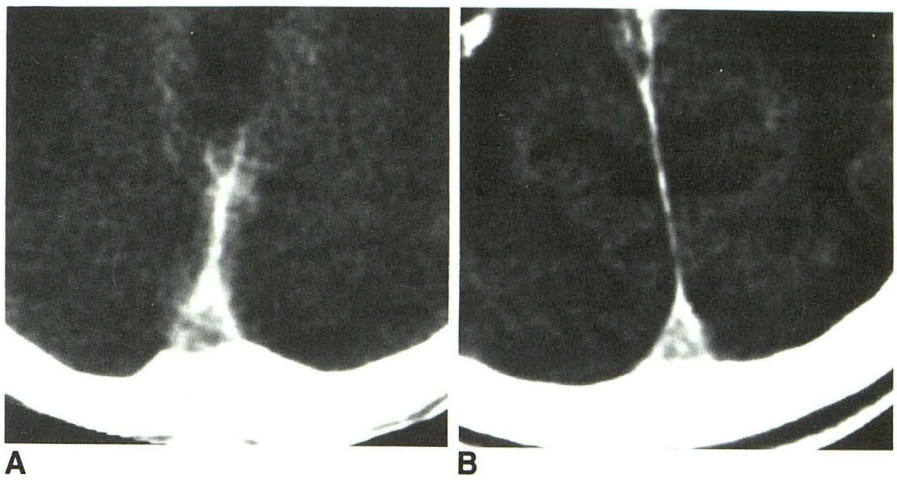

Fig. 3.—*A* and *B*, Contrast-enhanced CT images of superior sagittal sinus region in two other representative patients without sinus thrombosis demonstrate the delayed delta sign.

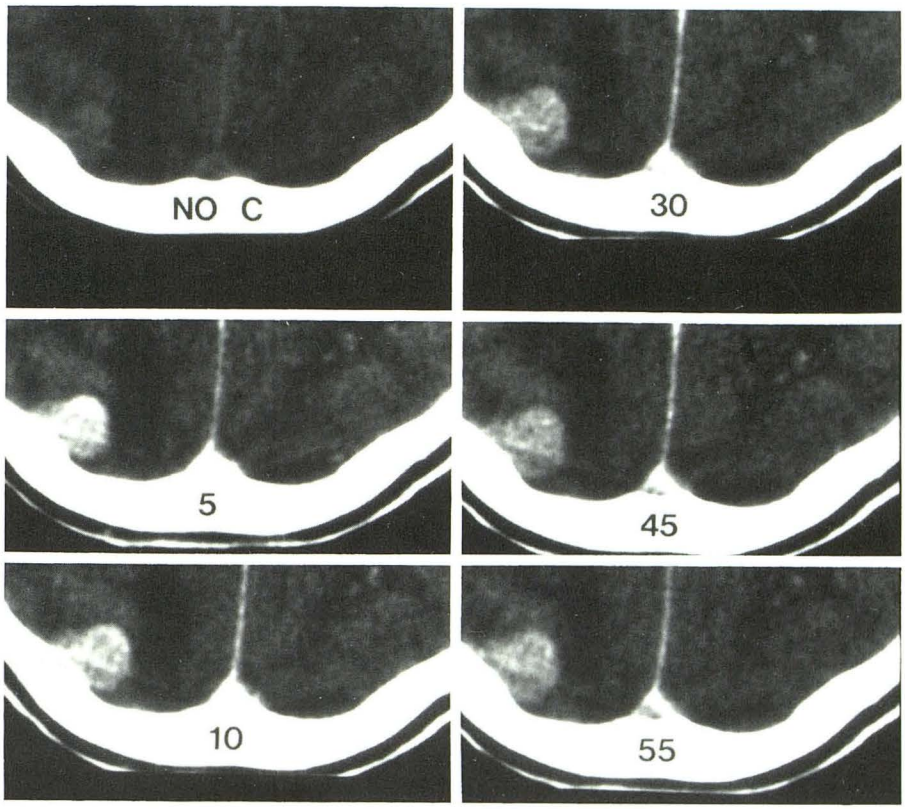

Fig. 4.—CT images of superior sagittal sinus region prior to contrast infusion (*top left*), and 5–55 min after injection. Note progressive relative lucency of the sinus relative to dura on delayed images. The patient had an enhancing metastasis in the right occipital lobe, but no clinical indications of sinus thrombosis.

acteristics of sinus occlusion on unenhanced CT scans include the cord sign (5%), hemorrhage (14.5%), dense vein sign (20%), edema (8%), and compressed ventricles (14%). With contrast administration, tentorial (4%), gyral (1%), and intramedullary vein enhancement (2%) have been reported [3–6]. The most reliable appearance is that of the empty or negative delta sign on enhanced scans seen in approximately 29% of cases of sagittal sinus thrombosis [6]. Several potential visual pitfalls of enhanced CT that may lead to the false diagnosis of superior sagittal sinus thrombosis have been reported [6], including (1) intrasinus arachnoid granulations, fibrous brands, and septa; (2) photon depletion artifacts from dense calvarial bone; and (3) an anomalously high bifurcation of the sagittal sinus into the transverse sinuses.

We agree that competent neuroradiologists should have no difficulty in establishing or refuting the diagnosis of sinus thrombosis on CT when a complete set of pre- and postcontrast images is available and analyzed. This ideal situation may not always be realized, however. At our institution, approximately 5% of CT scans are performed only after

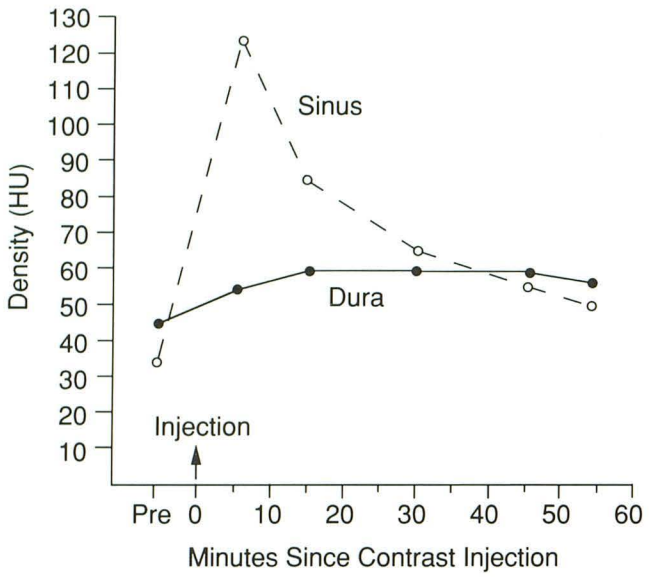

Fig. 5.—Graph of CT densities of sinus and dura in the patient of Figure 4 at various time intervals after contrast administration.

contrast administration. Clinical scenarios in which this may occur include the follow-up of known brain tumors, metastatic work-ups, routine pituitary and orbit studies, CT scans obtained after angiography, and cranial CT that follows a contrast-enhanced study of some other part of the body. In certain clinical circumstances (such as the work-up for metastatic disease or in brain evaluation following stereotaxic biopsy), CT scanning may not begin for 1 or 2 hr after contrast infusion. Furthermore, some of the same patients who undergo delayed postcontrast CT scanning may also be at relatively high risk for development of sinus thrombosis. It is in precisely this group of patients who receive only delayed postcontrast CT scans that the pitfall of the delayed delta sign may occur. As we have demonstrated, a moderate proportion (10%) of such delayed postcontrast scans will demonstrate significantly lower density of the central portion of the superior sagittal sinus relative to its dura, which may simulate the appearance of a true sinus thrombosis.

The appearance of the sagittal sinus relative to dura on CT as a function of time since contrast administration can be reasonably explained by the known pharmacokinetics of iodinated contrast agents [7–13]. After intravascular administration, contrast material rapidly approaches a volume of distribution equal to that of the extracellular space [7–9]. Such equilibrium is not achieved instantaneously, but requires approximately 1–2 hr to occur [10]. Prior to the establishment of this equilibrium, the serum concentration of iodinated contrast material is significantly higher than that of the interstitium. Within the first 30–45 min after infusion, therefore, the radiologic attenuation of blood within the sagittal sinus will be significantly greater than that of its dural membranes. Beyond this time, however, the contrast concentrations in blood and dura should gradually become equalized. At this point the natural precontrast density differences between blood and dura may again become manifest. Our quantitative data support this theory for the origin of the delayed delta sign.

Tissue-specific distribution characteristics may potentially influence relative dural and sinus densities on delayed postcontrast images. For example, it is well recognized that the rate at which plasma-tissue equilibrium is reached is both patient- and organ-dependent [12, 13]. Additionally, long-term (3–5 days) serum measurements in humans suggest that a small fraction of contrast material is slowly released from deep interstitial or intracellular compartments [7, 8]. The different appearances of the sagittal sinuses we have observed on delayed CT scans may also depend on variations in renal function and hydration state, which were not controlled in this study.

In summary, about 10% of delayed postcontrast CT brain images may demonstrate an appearance similar to superior sagittal sinus thrombosis, which we have named the delayed delta sign. Although comparison with a precontrast study would immediately resolve the issue, such images may not always be available. Caution should be exercised in these circumstances in order not to confuse the delayed delta sign with the empty delta sign of true cerebral venous sinus thrombosis.

REFERENCES

1. Merritt HH. *A textbook of neurology*, 6th ed. Philadelphia: Lea and Febiger, **1979**:40–45
2. Buonanno FS, Moody DM, Ball MR, Laster DW. Computed cranial tomographic findings in cerebral sinovenous occlusion. *J Comput Assist Tomogr* **1978**;2:281–290
3. Ford K, Sarwar M. Computed tomography of dural sinus thrombosis. *AJNR* **1981**;2:539–543
4. Rao KCVG, Knipp HC, Wagner EJ. Computed tomographic findings in cerebral sinus and venous thrombosis. *Radiology* **1981**;140:391–398
5. Goldberg AL, Rosenbaum AE, Wang H, Kim WS, Lewis VL, Hanley DF. Computed tomography of dural sinus thrombosis. *J Comput Assist Tomogr* **1986**;10:16–20
6. Virapongse C, Cazenave C, Quisling R, Sarwar M, Hunter S. The empty delta sign: frequency and significance in 76 cases of dural sinus thrombosis. *Radiology* **1987**;162:779–785
7. Edelson J, Shaw D, Palace G. Pharmacokinetics of iohexol, a new nonionic radiocontrast agent in humans. *J Pharm Sci* **1984**;73:993–995
8. Olsson B, Aulie A, Sveen K, Andrew E. Human pharmacokinetics of iohexol: a new nonionic contrast medium. *Invest Radiol* **1983**;18:177–182
9. Kormano M, Dean PB. Extravascular contrast material: the major component of contrast enhancement. *Radiology* **1976**;121:379–382
10. Grönberg T, Sjöberg S, Almen T, Golman K, Grönberg T, Mattsson S. Non-invasive estimation of kidney function by x-ray fluorescence analysis. Elimination rate and clearance of contrast media injected for urography in man. *Invest Radiol* **1983**;18:445–452
11. Sjöberg S, Almen T, Golman K, Grönberg T, Mattsson S. Non-invasive estimation of kidney function by x-ray fluorescence analysis: biological half-life and clearance of contrast material in rabbits. *Invest Radiol* **1981**;16:215–220
12. McChesney EW, Hoppe JO. Studies of the tissue distribution and excretion of sodium diatrizoate in laboratory animals. *AJR* **1957**;78:137–144
13. Knoefel PK, Kraft RP, Knight RD. Sodium versus meglumine diatrizoate in excretory urography. *Invest Radiol* **1974**;9:117–125