

Are your **MRI contrast agents** cost-effective?

Learn more about generic **Gadolinium-Based Contrast Agents**.



FRESENIUS
KABI

caring for life

AJNR

**Spontaneous drainage of an ethmoidal mucocele:
a possible cause of pneumosinus dilatans.**

R A Benedikt, D C Brown, M K Roth, C A Geyer and V N Ghaed

AJNR Am J Neuroradiol 1991, 12 (4) 729-731

<http://www.ajnr.org/content/12/4/729.citation>

This information is current as
of April 19, 2024.

Spontaneous Drainage of an Ethmoidal Mucocele: A Possible Cause of Pneumosinus Dilatans

Richard A. Benedikt,¹ Douglas C. Brown,^{1,2} Maurice K. Roth,³ Carl A. Geyer,^{1,2} and Victor N. Ghaed¹

Idiopathic expansion of a paranasal sinus containing air and without an associated mass has been termed pneumosinus dilatans [1]. This rare disorder has been known to occur in all the paranasal sinuses, but it most commonly affects the frontal sinus. Clinical symptoms include pain, visual loss, proptosis, galactorrhea, and hypopituitarism [2–4]. Proposed mechanisms of origin include developmental, inflammatory, and obstructive.

We present a 17-year-old girl with pneumosinus dilatans of the left ethmoidal sinus. Previous CT studies, obtained 3 months prior to evaluation at our institution, demonstrated an expansile soft-tissue mass in the same left ethmoidal sinus. Interim history included a single episode of massive rhinorrhea.

We hypothesize that spontaneous drainage of a mucocele was the causative agent in our case of pneumosinus dilatans and represents a plausible mechanism of origin for this otherwise idiopathic disorder.

Case Report

A 17-year-old girl was referred to our institution for evaluation and treatment of an expansile left ethmoidal sinus mass. Presenting symptoms included nasal congestion and mild pain, which had been present for several months. Medical and surgical history was otherwise negative. An axial noncontrast CT scan, obtained 3 months earlier at another institution, documented a 3-cm soft-tissue density mass in the left ethmoidal sinus with mild medial bone expansion but without bone destruction (Fig. 1A). The other paranasal sinuses were normal.

At our institution, subsequent direct coronal CT documented an air-filled dilated anterior ethmoidal sinus with medial expansion in the exact location and configuration as the previously seen expansile soft-tissue mass (Fig. 1B). No bone defects were noted. No medical or surgical therapy had been instituted prior to evaluation at our institution. Upon further questioning, the patient described a history of "blowing [her] nose and a big orange ball came out and scared [her]." The diagnosis of pneumosinus dilatans following spontaneous

drainage of a mucocele was made presumptively and, since she was asymptomatic, no treatment was rendered.

Discussion

Pneumosinus dilatans, defined as expansion of a paranasal sinus that contains only air, is a rare entity. In a review of the literature, Reicher et al. [3] found approximately 65 reported cases. Diagnostic criteria proposed by Reicher et al. are (1) enlargement of an air cell or entire sinus, (2) the presence of only air in the abnormal space, and (3) ballooning outward of the walls of the sinus, which may be thinned or demineralized. Diagnosis has been made by either plain film or CT. Several authors have separated pneumocele, expansile paranasal sinus containing air with bone erosion, from pneumosinus dilatans, expansile paranasal sinus containing air without bone erosion. However, these entities likely represent variations of the same disorder, given their similar radiologic and clinical presentations [3]. Secondary sinus expansion—such as reaction to planum sphenoidal meningioma, cerebral atrophy, or acromegaly—has also been termed pneumosinus dilatans, but will be excluded from this discussion [3, 5].

Our case suggests that pneumosinus dilatans may be a sequela to mucocele rather than a separate clinical entity. Vines et al. [4] suggested that spontaneous resolution of mucocele may be a cause of pneumosinus dilatans but believed this to be unlikely. The clinical symptoms of both mucocele and pneumosinus dilatans are similar and related to the mass effect in or about the involved paranasal sinus. Presenting symptoms for mucocele are dependent on location and size, although size bears no relationship to severity of symptoms [6]. Symptoms include pain, visual changes, rhinorrhea, hypopituitarism, and proptosis, and are similar to symptoms reported in patients with pneumosinus dilatans [2–4, 6]. The age range in patients with pneumosinus dilatans is

Received September 11, 1990; revision requested December 27, 1990; revision received January 22, 1991; accepted January 28, 1991.

The opinions or assertions contained herein are the private views of the authors and are not to be construed as official or as reflecting the views of the Department of the Army or the Department of Defense.

¹ Department of Radiology, Walter Reed Army Medical Center, 6900 Georgia Ave., Washington, DC 20307-5001. Address reprint requests to R. A. Benedikt.

² Department of Radiology and Nuclear Medicine, Uniformed Services University of the Health Sciences, Bethesda, MD 20814.

³ Department of ORL-HNS, Walter Reed Army Medical Center, 6900 Georgia Ave., Washington, DC 20307-5001.

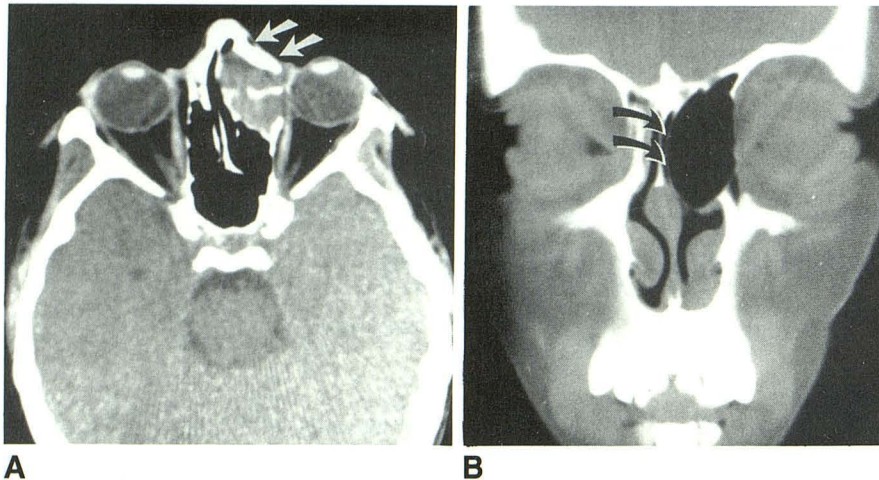


Fig. 1.—17-year-old girl with expansile ethmoidal sinus mass.

A, Initial noncontrast axial CT scan shows expansile soft-tissue mass in left anterior ethmoidal air cell (arrows) with medial expansion into nasal cavity.

B, Follow-up noncontrast coronal CT scan obtained 3 months later shows air-filled expanded anterior ethmoidal air cell in exact location as previously seen soft-tissue mass. Note thinning and medial displacement of medial wall of anterior ethmoidal sinus (arrows).

similar to patients presenting with mucocoeles, usually 20–40 years old. However, pneumosinus dilatans is most frequently reported in males while mucocoeles have an equal sex predilection.

Both mucocoeles and pneumosinus dilatans occur predominantly in the frontal sinus, representing approximately 65% of reported cases [3, 7]. Following involvement of the frontal sinus, mucocoeles occur most frequently in the ethmoidal, maxillary, and sphenoidal sinuses, while pneumosinus dilatans occurs most frequently in the sphenoid, maxillary, and ethmoidal sinuses, respectively [3, 7]. Several possibilities exist for the discrepancy in the relative incidences of these two disorders. First, paranasal sinus drainage varies in the ethmoidal, sphenoidal, and maxillary sinuses: the sphenoidal sinus drains into the superior meatus of the nasal cavity, the ethmoidal drains into the middle and superior meati, and the maxillary sinus drains through the hiatus semilunaris into the middle meatus. The complexity of each sinus drainage varies, which may make ethmoidal mucocoeles less likely to drain spontaneously, particularly since their ostia are the smallest of the paranasal sinuses [7]. Second, associated causes of pneumosinus dilatans, such as blistering and expansion of the sphenoidal sinus as a result of planum sphenoidal meningioma, may alter statistical comparison as may consideration of pneumosinus dilatans and pneumocele as one or two disorders. Third, the relative paucity of reported cases increases the likelihood of statistical variance.

Our case demonstrates spontaneous resolution of a 3-cm ethmoidal sinus mass with an expanded but intact sinus. Other than mucocele, we cannot hypothesize about other masses that may drain spontaneously through an intact sinus, presumably through the sinus ostia. Pathologically, mucocoeles consist of inflammatory cells, acute or chronic with varying amounts of connective tissue [8], a mass that conceivably is sufficiently flexible to pass through an ostia significantly smaller than its width within the sinus.

Previous investigators have proposed several mechanisms for the onset of pneumosinus dilatans: developmental, inflammatory, and obstructive. The most commonly proposed mechanism is an air-block phenomenon in which air enters

but is unable to exit a paranasal sinus owing to partial obstruction of a major sinus ostium [9–12]. This chronic air-pressure elevation causes bone expansion and the subsequent finding of an enlarged, air-filled sinus. Whether sufficient air pressure could be generated and maintained to remodel thin but intact bone structures is not known. This theory also does not explain the absence of accumulated fluid or mass within the sinus during the period of obstruction. Additionally, only one published article has reported stenosis of a sinus ostium [11]. The origin of mucocoeles is unclear, but they likely are caused by obstruction of the sinus ostium with secondary accumulation of mucous secretions [13]. Removal of the ostium obstruction may enable spontaneous drainage of a mucocele.

Reicher et al. [3] proposed that in some cases the abnormally dilated sinus might represent an idiopathic anomaly, particularly in patients who are in early puberty, which is a time of rapid sinus growth. This theory, however, does not explain why the vast majority of cases occur in postpubertal individuals.

The final theory for the pathogenesis of pneumosinus dilatans is chronic inflammation, which incites expansile aeration of the sinus [4, 14]. Inflammatory changes of a chronic nature have been noted in several sinuses that have been evaluated histologically [4, 14]. However, this theory does not explain the absence of fluid within the sinus and the appearance of uniform bone expansion secondary to mass effect in patients with pneumosinus dilatans. Vines et al. [4] considered spontaneous drainage of a mucocele to be a possible but unlikely cause of pneumosinus dilatans owing to the rarity of maxillary mucocoeles and the inability to obtain a history of sinus symptoms in their patient.

In summary, we present a case of pneumosinus dilatans of the ethmoidal sinus that initially presented as an expansile soft-tissue mass. We believe that the expansile sinus mass represented a mucocele even without pathologic confirmation because we can postulate no other expansile mass that would drain spontaneously through the ostia of an expanded but otherwise intact sinus. Our case offers both clinical and radiologic evidence to support this hypothesis. Spontaneous

drainage of a mucocele is likely a rare event as judged by the infrequent diagnosis of pneumosinus dilatans.

We think that spontaneous drainage of a mucocele is a plausible explanation for pneumosinus dilatans, a lesion whose pathogenesis has previously been obscure. Detailed histories obtained from subsequent patients, as well as correlation with previous imaging studies, will test the validity of our hypothesis.

REFERENCES

1. Benjamin CE. Pneumosinus dilatans. *Acta Otolaryngol* (Stock) **1918**;1:412-422
2. Lombardi G. *Radiology in neuro-ophthalmology*. Baltimore: Williams & Wilkins, **1967**:163-166
3. Reicher MA, Bentson JR, Halbach VV, Lufkin R, Hepler RS. Pneumosinus dilatans of the sphenoid sinus. *AJNR* **1986**;7:865-868
4. Vines FS, Bonstelle CT, Floyd HL. Proptosis secondary to pneumocele of the maxillary sinus. *Neuroradiology* **1976**;11:57-59
5. Wiggli U, Oberson R. Pneumosinus dilatans and hyperostosis: early signs of meningiomas of the anterior chiasmatic angle. *Neuroradiology* **1975**;8:217-221
6. Weber AL, Hesselink JR, Oot RF. Radiology of mucoceles. In: English GM, ed. *Otolaryngology*, Vol. 2. Philadelphia: Lippincott, **1987**:1-25
7. Som PM. The paranasal sinuses. In: Bergeron RT, Osborn AG, Som PM, eds. *Head and neck imaging (excluding the brain)*. St. Louis: Mosby, **1984**:Ch. 1, 1-142
8. Canalis RF. Frontal mucoceles. In: English GM, ed. *Otolaryngology*, vol. 2. Philadelphia: Lippincott, **1982**:Ch. 22, 1-11
9. Morrison MD, Tchang SP, Maber BR. Pneumocele of the maxillary sinus: report of a case. *Arch Otolaryngol* **1976**;102:306-307
10. Noyek AM, Zizmor J. Pneumocele of the maxillary sinus. *Arch Otolaryngol* **1974**;100:155-156
11. Zizmor J, Bryce M, Schaffer SL, Noyek AM. Pneumocele of the maxillary sinus: a second case report. *Arch Otolaryngol* **1975**;101:387-388
12. Meyers AD, Burtzchi T. Pneumocele of the maxillary sinus. *J Otolaryngol* **1980**;9:361-363
13. Som PM, Shuger JMA. The CT classification of ethmoid mucoceles. *J Comput Assist Tomogr* **1980**;4:199-203
14. Som PM, Sachdev VP, Biller HF. Sphenoid sinus pneumocele: report of a case. *Arch Otolaryngol* **1983**;109:761-764