



ASNR Career Center

The Go-To Job Site for Neuroradiology Employers and Job Seekers
Start here: careers.asnr.org

AJNR

Iohexol CT ventriculogram of multiple cerebral hydatid cysts.

S Peker, H Celik, M Eryilmaz and O Gurcay

AJNR Am J Neuroradiol 1991, 12 (4) 797

<http://www.ajnr.org/content/12/4/797.citation>

This information is current as
of October 1, 2023.

Iohexol CT Ventriculogram of Multiple Cerebral Hydatid Cysts

Multiple cerebral hydatid cysts are rare and usually occur as a result of spontaneous, traumatic, or surgical rupture of a primary hydatid cyst [1]. Surgical treatment of multiple cysts involves a greater risk than treatment of a single cyst because of the increased risk of cyst rupture. We report the use of nonionic CT ventriculography for the preoperative examination of a patient with multiple hydatid cysts of the brain.

Case Report

A 15-year-old boy had had headache and nausea for 5 months. CT showed a left-sided frontal round 9-cm cystic lesion with daughter cysts (Fig. 1A). At surgery, a primary, parenchymal hydatid cyst was removed intact by using the Dowling technique [2]. The patient was readmitted 1 year later with the same symptoms, and CT showed multiple cerebral hydatid cysts (including a large cyst in the fourth ventricle) (Fig. 1B). For more precise evaluation of the number and location of the multiple lesions, CT ventriculography was performed by injecting iohexol (240 mg/ml) into the occipital horn of the left lateral ventricle (Figs. 1C and 1D). At surgery, the hydatid cyst of the fourth ventricle was removed intact. In two more operations over the next 2 weeks, five additional cysts from the left hemisphere and six from the right hemisphere were removed intact. One left-sided frontal cyst and one right-sided occipital cyst were parenchymal; the other cysts were intraventricular. The lesions varied in size from 1.5 to 6 cm, and a brood capsule was identified among the parenchymal cysts. The patient's subsequent clinical course was complicated by pneumonia and meningitis, and he died 9 days after the last operation.

Discussion

It has been estimated that approximately 2% of cases of hydatid disease have cerebral involvement [3], with brain involvement occur-

ring much more frequently in infants and children [4]. Multiple primary cerebral hydatidosis is caused by ingestion of multiple larvae. Primary hydatid cysts contain scolices and have brood capsules; secondary cysts do not contain scolices and are infertile. In our case, the patient most likely had multiple primary cysts at the time of initial presentation, but only the largest could be detected on CT. Because the density of hydatid cyst fluid is similar to that of CSF, the CT appearance of these lesions is similar to that of other cystic infections of the brain, cystic tumors, and nontumoral cystic lesions such as ependymal cysts. In our case, CT ventriculography after intraventricular injection of nonionic contrast medium was useful for precise delineation of the number and location of the multiple hydatid cysts before surgery. However, the person who does the ventriculography must be sure that no cysts are present at the injection site. Injection of the cystic cavity could cause an allergic reaction or recurrence with multiple cysts [5].

Selcuk Peker
Huseyin Celik
Muzaffer Eryilmaz
Ozdemir Gurcay
Hacettepe University
Ankara, Turkey

REFERENCES

- Paşaoğlu A, Orhon C, Akdemir H. Multiple primary hydatid cysts of the brain. *Turk J Pediatr* 1989;31:57-61
- Carrea R, Dowling E Jr, Guevara JA. Surgical treatment of hydatid cysts of the central nervous system in pediatric age (Dowlings technique). *Childs Brain* 1975;1:4-21
- Rudwan MA, Khaffaji S. CT of cerebral hydatid disease. *Neuroradiology* 1988;30:496-499
- Sharma A, Abraham J. Multiple giant hydatid cysts of the brain: case report. *J Neurosurg* 1982;57:413-415
- Gökalp HZ, Erdoğan A. Hydatid cyst of the aqueduct of Sylvius: case report. *Clin Neurol Neurosurg* 1988;90:83-85

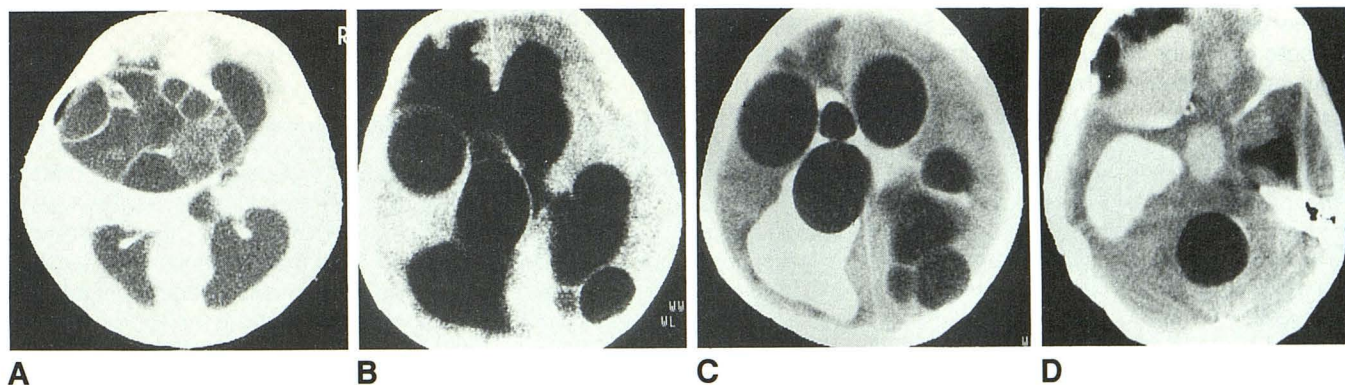


Fig. 1.—Multiple cerebral hydatid cysts.

A, CT scan of brain obtained at time of initial presentation shows a hydatid cyst with daughter cysts.

B, CT scan of brain obtained 1 year after A shows multiple hydatid cysts.

C and D, CT ventriculograms obtained at same time as B after injection of iohexol into occipital horn of left lateral ventricle shows multiple intraventricular and parenchymal cysts (C) and a large cyst in the fourth ventricle (D).