

Are your **MRI contrast agents** cost-effective?

Learn more about generic **Gadolinium-Based Contrast Agents**.



FRESENIUS
KABI

caring for life

AJNR

^{99m}Tc -HMPAO SPECT imaging in interventional neuroradiology: validation of balloon test occlusion.

E B Moody, R C Dawson, 3rd and M P Sandler

AJNR Am J Neuroradiol 1991, 12 (6) 1043-1044

<http://www.ajnr.org/content/12/6/1043.citation>

This information is current as of April 17, 2024.

^{99m}Tc-HMPAO SPECT Imaging in Interventional Neuroradiology: Validation of Balloon Test Occlusion

Permanent occlusion or surgical sacrifice of the internal carotid artery (ICA) is associated with a significant risk of subsequent stroke. Prediction of the functional cerebrovascular changes likely to result from ICA occlusion typically relies on an assessment of neurologic status during a test occlusion with an intraluminal balloon. Even in patients clinically tolerant of ICA test occlusion, the prevalence of postoperative stroke is high. We report our initial experience using ^{99m}Tc-hexamethylpropyleneamine oxime (^{99m}Tc-HMPAO) single-photon emission computed tomography (SPECT) to assess changes in cerebral perfusion during balloon test occlusion and examine its possible role in the selection of patients likely to tolerate permanent occlusion of the ICA.

Methods

After cerebral angiography, a 6-French double-lumen occlusion balloon occlusion catheter (Medi-tech, Watertown, MA) was positioned in the ICA, and the balloon was filled with contrast material. Neurologic evaluation of the patient was performed during occlusion of the ICA. After 5–10 min of occlusion, 20 mCi (740 MBq) ^{99m}Tc-HMPAO (Ceretek, Amersham, Arlington Heights, IL) was injected IV. The test occlusion was maintained for 15 min, provided neurologic sequelae did not develop. At the conclusion of the procedure, the patient was transferred to the nuclear medicine department for SPECT brain imaging.

Baseline ^{99m}Tc-HMPAO SPECT studies were obtained 24–48 hr before or after the balloon test occlusion. Regions of interest were traced to approximate gray matter outlines in the middle cerebral artery (MCA) distributions on several transverse slices. The relative perfusion ratio in the MCA distribution ipsilateral to the occluded carotid artery was determined by dividing the average counts per pixel in the MCA distribution ipsilateral to the occluded artery by the average counts per pixel in the corresponding region on the contralateral side.

Results

We have performed functional brain imaging on six patients following balloon test occlusion of the ICA. Three patients had normal values on baseline studies and on studies obtained during balloon occlusion. One patient was unable to tolerate brief balloon occlusion. In two patients significant perfusion asymmetries developed during test occlusion (Figs. 1 and 2). Table 1 summarizes the clinical and imaging findings on these patients.

Representative Case Study

A 65-year-old man with recurrent laryngeal carcinoma, treated previously with radiation, chemotherapy, and radical laryngectomy, was referred for surgical treatment of recurrent tumor. Encasement of the left ICA by tumor was noted on CT, and it was thought that sacrifice of the left ICA during surgery would be inevitable. The patient tolerated 20 min of occlusion without neurologic signs or symptoms developing, although assessment of speech was difficult because of his previous laryngectomy. Baseline SPECT images (Fig. 2A) showed a mild reduction in perfusion in the left MCA distribution (relative perfusion ratio, 0.94). SPECT images (Fig. 2B) obtained

following ICA occlusion showed a relative perfusion ratio of 0.80 in left MCA distribution compared with the right side. Because of the relative reduction in perfusion of the left MCA during balloon test occlusion, it was decided to perform bypass grafting in conjunction with carotid sacrifice. The patient did well postoperatively.

Discussion

The development of neurologic sequelae during balloon test occlusion provides unequivocal evidence of cerebrovascular compromise;

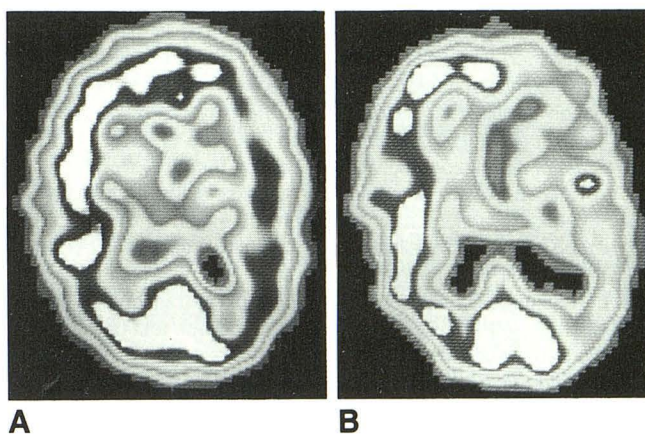


Fig. 1.—A, Baseline ^{99m}Tc-HMPAO SPECT image of patient 1 (Table 1) shows a relative reduction in perfusion of 9.7% in left middle cerebral artery (MCA) distribution.

B, Similar image obtained immediately after balloon test occlusion of internal carotid artery shows a reduction of 17% in left MCA distribution, 7.3% more than that seen on A.

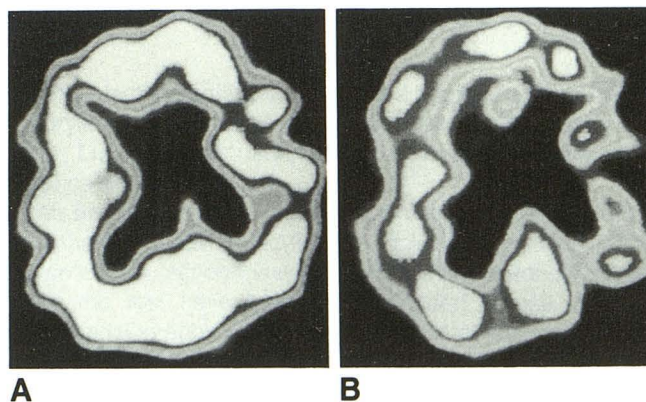


Fig. 2.—A, Baseline ^{99m}Tc-HMPAO SPECT image of patient discussed in Case Report section (patient 3, Table 1) shows a 6% reduction in perfusion in left middle cerebral artery (MCA) distribution compared with perfusion in right MCA distribution.

B, Image obtained immediately after balloon test occlusion of internal carotid artery shows 20% less perfusion in left MCA distribution compared with right MCA distribution.

TABLE 1: Clinical and Imaging Findings

Patient	Diagnosis	Relative Perfusion Ratio		Outcome
		Baseline	Occlusion	
1	Fibromuscular dysplasia of left ICA	0.90	0.83	Planned balloon embolization cancelled Patient referred for vascular bypass
2	Aneurysm of right ICA	S	S	Tolerated permanent ICA ligation
3	Tumor encasing left ICA	0.94	0.80	Vascular bypass performed before ICA ligation
4	Aneurysm of left ICA	S	S	Tolerated permanent ligation left ICA
5	Laryngeal cancer	ND	ND	Clinical failure, ICA not sacrificed
6	Parasellar meningioma	S	S	Tolerated permanent ICA balloon embolization

Note.—ICA = internal carotid artery, S = symmetrical (relative perfusion ratio >0.95), ND = not done.

however, the predictive value of a neurologic examination that shows no sequelae during test occlusion is unknown. The occurrence of stroke after ICA sacrifice has been documented in patients who tolerated balloon test occlusion of the ICA [1], and in a recent study [2], the prevalence of postoperative stroke was 10% when neurologic examination during test occlusion was the only predictive method used before permanent occlusion of the ICA. Use of xenon-133 CT to evaluate cerebral blood flow during balloon test occlusion [1, 3, 4] has provided a means of objectively assessing the hemodynamic changes likely to accompany permanent occlusion of the ICA, but this method has limited availability and is relatively difficult to perform. ^{99m}Tc-HMPAO SPECT imaging of the brain has pharmacologic and logistical advantages over xenon CT. The rapid extraction and stable distribution of HMPAO allow injection during balloon test occlusion in the angiography suite, with imaging being performed at the conclusion of the angiographic procedure. This eliminates the need to transport the patient with the catheter in place, obviates a second inflation of the balloon, and does not require the presence of the angiography team during imaging. SPECT allows assessment of a larger volume of the brain than does xenon CT, and changes in the MCA distribution can be compared with changes in the anterior and posterior cerebral artery distributions.

We think that the method described in this report shows promise as an alternative to xenon CT imaging in the assessment of patients who are at risk for cerebral ischemia or infarction after permanent ICA occlusion. Further study is needed to establish the critical level of perfusion asymmetry that indicates ischemia or stroke after permanent ICA occlusion.

Edward B. Moody
Robert C. Dawson III
Martin P. Sandler

*Vanderbilt University Medical Center
Nashville, TN 37232-2405*

REFERENCES

1. Erba SM, Horton JA, Latchaw RE, et al. Balloon test occlusion of the internal carotid artery with stable xenon/CT cerebral blood flow imaging. *AJNR* 1988;9:533-538
2. Gonzalez CF, Moret J. Balloon occlusion of the carotid artery prior to surgery for neck tumors. *AJNR* 1990;11:649-652
3. Moss AA. Critical review. *Invest Radiol* 1989;7:578-579
4. Steed DL, Webster MW, DeVries EJ, et al. Clinical observations on the effect of carotid artery occlusion on cerebral blood flow mapped by xenon computed tomography and its correlation with carotid artery back pressure. *J Vasc Surg* 1990;11:38-44

The reader's attention is directed to the commentary on this article, which appears on pages 1053-1054.