

Are your **MRI contrast agents** cost-effective?

Learn more about generic **Gadolinium-Based Contrast Agents**.



FRESENIUS
KABI

caring for life

AJNR

Angle-closure glaucoma consequent to embolization of dural cavernous sinus fistula.

K C Golnik, S A Newman and R Ferguson

AJNR Am J Neuroradiol 1991, 12 (6) 1074-1076

<http://www.ajnr.org/content/12/6/1074.citation>

This information is current as of April 19, 2024.

Angle-Closure Glaucoma Consequent to Embolization of Dural Cavernous Sinus Fistula

Karl C. Golnik,¹ Steven A. Newman,¹ and Robert Ferguson²

A variety of sequelae are associated with embolization of a cavernous sinus fistula. Transient or permanent cranial nerve palsies and cerebral ischemic events are most frequent [1]. We report a case of acute angle-closure glaucoma following embolization of a dural cavernous sinus fistula. Prompt recognition and treatment prevented optic nerve damage and visual loss.

Case Report

A 74-year-old woman presented with a 3-month history of right facial ache radiating to the right forehead and temporal region. Three weeks prior to presentation the left eye became red and irritated and binocular horizontal diplopia developed. CT demonstrated a dilated left superior ophthalmic vein. The patient was referred for neuroophthalmic evaluation. Medical and surgical history included hypertension, thrombocytopenia, and bilateral intracapsular cataract extractions (left eye, 1984; right eye, 1986).

Visual acuity was normal but she had 3-mm left ptosis, 3.5-mm left proptosis, and a mild right afferent pupillary defect. A partial left abduction deficit was present. Slit-lamp evaluation revealed a slightly irregular left pupil and an intact vitreous face. Intraocular pressure was low on the left ($T_A = 6$ OS). The third, fourth, and fifth cranial nerves were normal, as was the remainder of the neurologic examination. Cerebral angiography revealed a left dural cavernous sinus fistula with major feeders from the left external carotid artery (Fig. 1A). Retrograde blood flow was demonstrated in both superior and inferior ophthalmic veins.

Therapy was indicated because of the partial sixth nerve palsy and resultant diplopia. Avitene embolization of the distal left internal maxillary artery was accomplished with no immediate complications. Arteriography revealed complete occlusion of the feeders. Four hours after the procedure the patient experienced decreased vision in the left eye. Her left anterior chamber was flat with iridocorneal touch (Fig. 1B). Fundus examination revealed large ciliochoroidal effusions in the left eye. MR imaging indicated blood flow rather than thrombus in the superior ophthalmic vein. The intact vitreous face occluded the previous peripheral iridectomies. The patient was treated with cycloplegics and repeated laser iridectomies, which immediately deepened her anterior chamber (Fig. 1C). The choroidal effusions slowly resolved.

Discussion

The preferred treatment of symptomatic cavernous sinus fistula is embolization either by detachable balloon or by a variety of particulate materials [2]. The choice of technique depends on the source of the feeders and volume of flow. In a recent review of cavernous sinus fistula embolization, successful closures averaged 92% [1]. Undesirable sequelae have, however, been reported. Transient or permanent cranial nerve palsies are the most frequently recognized complications, with rates of occurrence of 0–67% and 0–33%, respectively [1–15]. In treating direct fistulas, Debrun et al. [3] found the rate of cranial nerve abnormalities to increase when more than one balloon was used [3]. The increased volume occupied by multiple balloons presumably causes nerve palsies by direct compression or focal vascular hypoperfusion. Cerebral ischemia most often occurs immediately following the procedure [2, 3, 5–7, 9, 12, 15]. Less commonly, ischemic events have been reported days to weeks later [13, 16]. The pathophysiology of ischemia may include inadvertent embolization of inappropriate vessels or propagation of occlusion-induced thrombosis [2, 3]. Rarely, other sequelae, including intraorbital hemorrhage [6], airway obstruction [9], and death following vascular perforation, have been reported [6, 8]. It has recently been recognized that choroidal effusions and secondary angle closure may be associated with dural cavernous fistulas [17]. It is interesting that in one of these previously reported cases angle closure occurred after embolization, although this was not specifically commented upon.

Angle-closure glaucoma occurs when the aqueous humor outflow channels (trabecular meshwork) are occluded by the peripheral iris. Without egress, aqueous humor accumulates and the intraocular pressure rises. Such symptoms as ocular or periorbital pain, headache, blurred vision, and visual disturbances consisting of halos or rainbows around objects may develop within hours of angle closure. Signs of abrupt increase in intraocular pressure may include conjunctival injection, corneal haziness (edema), a minimally reactive pupil, and, in angle closure, a shallow anterior chamber. Ophthalmic

Received January 30, 1991; revision requested April 5, 1991; revision received April 26, 1991; accepted May 15, 1991.

¹ Department of Ophthalmology, University of Virginia Health Sciences Center, Charlottesville, VA 22908. Address reprint requests to S. A. Newman.

² Department of Radiology, University of Virginia Health Sciences Center, Charlottesville, VA 22908.

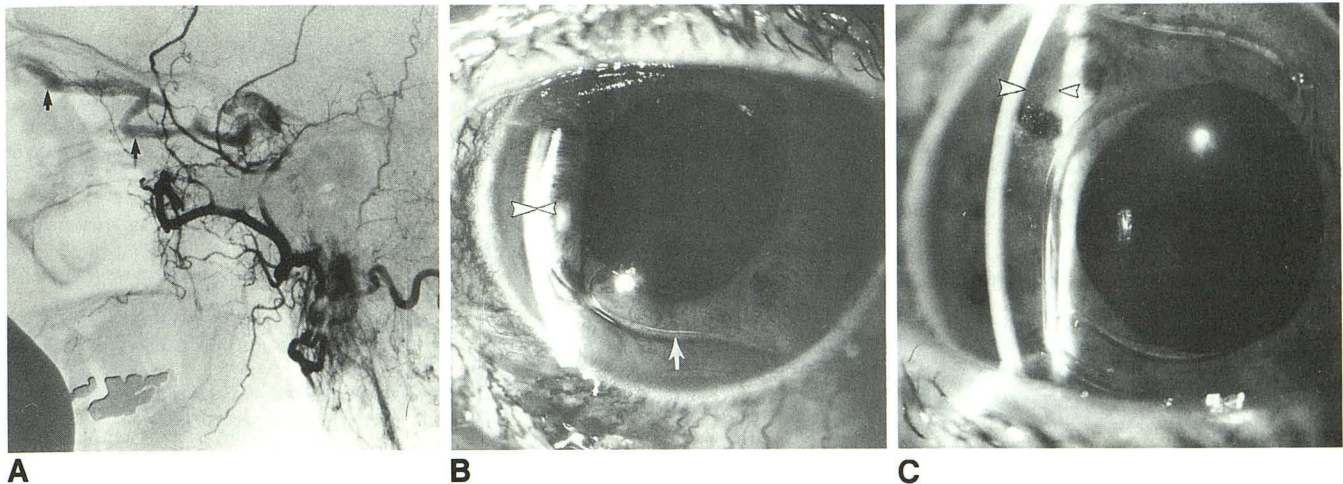


Fig. 1.—74-year-old woman with 3-month history of right facial ache radiating to right forehead and temporal region.
A, Left external carotid angiogram, lateral view, shows left dural cavernous sinus fistula. Venous drainage from the fistula is through the dilated left superior ophthalmic vein (arrows).
B, Several hours after embolization the left anterior chamber was flat. Note the apposition of the corneal endothelium (large arrowhead) and the iris surface (small arrowhead), (arrow = intraocular lens).
C, The left anterior chamber deepened after therapy. Note the distance between the corneal endothelium (large arrowhead) and the iris surface (small arrowhead).

intervention should be immediate and may include topical, oral, and IV medications; laser iridotomy; and perhaps surgical filtration procedures. Persistent increases in intraocular pressure will lead to optic nerve damage or complete loss of vision.

Angle-closure glaucoma may be related to anatomically narrow angles (primary) or may occur as a consequence of any process that shifts the lens or iris forward. The choroid is a vascular plexus between the retina and the sclera that provides nourishment to the outer retina. Choroidal arterial supply is from the posterior ciliary arteries (branches of the ophthalmic artery), and venous drainage occurs through the vortex veins. These veins drain through the superior ophthalmic vein to the cavernous sinus. Ciliochoroidal effusion is an accumulation of fluid in the potential space (suprachoroidal) between the choroid and the sclera. The effusion is usually caused by vascular transudation resulting from an increase in the transcapillary pressure. Either increased venous pressure or decreased intraocular pressure will increase the transcapillary pressure [18]. Alternatively, a hemorrhagic effusion can occur and has been reported in association with carotid cavernous fistula [19]. Presumably, the vessels within the suprachoroidal space, distended by increased venous pressure, may rupture owing to fluctuations in transcapillary pressure. Thus, both types of effusion can occur with changes in transcapillary pressure. This suprachoroidal fluid accumulation causes the less rigid choroid with overlying retina to bulge into the vitreous space. The lens and iris are then rotated forward, occluding the trabecular meshwork. Thus, aqueous humor cannot exit the eye and intraocular pressure increases.

The pathogenesis of our patient's choroidal effusion is unclear. Certainly thrombosis of the superior ophthalmic vein would increase vortex vein pressure and could theoretically

produce transudation and resultant choroidal effusion. However, MR imaging indicated persistent flow in the superior ophthalmic vein. Preembolization angiography demonstrated dilatation and retrograde flow in the superior ophthalmic vein. This may impede choroidal vascular outflow somewhat, but only occasionally enough to produce effusion [17]. It is likely that during embolization, flow in the superior ophthalmic vein changed, resulting in a transient increase in venous pressure. This sort of transient increase in intravenous pressure is not uncommon after occlusion of a carotid cavernous fistula. The increased venous pressure combined with our patient's low intraocular pressure could have increased the transcapillary pressure enough to cause either a transudative or hemorrhagic choroidal effusion. Data supporting this hypothesis are derived from an investigation of eyes with compromised vortex vein outflow caused by a scleral buckling procedure for retinal detachment [20]. Choroidal effusion was found to be most highly associated with the combination of low intraocular pressure and poor venous outflow.

Regardless of the mechanism, rapid recognition of the signs and symptoms of increased intraocular pressure is essential in order to prevent permanent optic nerve damage. Careful monitoring in the immediate postembolization period is necessary to recognize these treatable, but potentially irreversible, ocular sequelae.

REFERENCES

1. Keltner JL, Satterfield D, Dublin AB, Lee BC. Dural and carotid cavernous sinus fistulas. *Ophthalmology* 1987;94:1585-1600
2. Vinuela F, Fox AJ, Debrun GM, et al. Spontaneous carotid-cavernous fistulas: clinical, radiological, and therapeutic considerations. *J Neurosurg* 1984;60:976-984
3. Debrun G, Lacour P, Vinuela F, et al. Treatment of 54 traumatic carotid-

- cavernous fistula. *J Neurosurg* **1981**;55:678-692
4. Tsai FY, Hieshima GB, Mehlinger CM, et al. Delayed effects in the treatment of carotid fistulas. *AJNR* **1983**;4:357-361
 5. Kupersmith MJ, Berenstein A, Flamm E, Ransohoff J. Neuroophthalmic abnormalities and intravascular therapy of traumatic carotid cavernous fistulas. *Ophthalmology* **1986**;93:906-912
 6. Hieshima GB, Higashida RT, Halbach VV. Advances in the diagnosis and treatment of carotid cavernous fistula. *Ophthalmology* **1986**;93:69
 7. Keltner JL, Gittinger JW Jr, Miller NR, Burde RM. A red eye and high intraocular pressure. *Surv Ophthalmol* **1987**;31:328-336
 8. Palestine AG, Younge BR, Piepgras DG. Visual prognosis in carotid cavernous fistula. *Arch Ophthalmol* **1981**;99:1600-1603
 9. Barrow DL, Fleischer AS, Hoffman JC. Complications of detachable balloon catheter technique in the treatment of traumatic intracranial arteriovenous fistulas. *J Neurosurg* **1982**;56:396-403
 10. Kalina RE, Kelly WA. Proliferative retinopathy after treatment of carotid-cavernous fistulas. *Arch Ophthalmol* **1978**;96:2058-2060
 11. Chowdhary UM. Treatment of carotid cavernous fistula using a balloon tipped intra-arterial catheter. *J Neurol Neurosurg Psychiatry* **1978**;41:996-1012
 12. Sekhar LN, Heros RC, Kerber CW. Carotid cavernous-fistula following percutaneous retrogasserian procedures: a report of two cases. *J Neurosurg* **1979**;51:700-706
 13. Farley MK, Clark RD, Fallor MK. Spontaneous carotid-cavernous fistula and the Ehler-Danlos syndromes. *Ophthalmology* **1983**;90:1337-1342
 14. Barrow DL, Spector RH, Braun IF, et al. Classification and treatment of spontaneous carotid cavernous fistulas. *J Neurosurg* **1985**;62:248-256
 15. Berenstein A, Scott J, Choi IS, Perskey M. Percutaneous embolization of arteriovenous fistulas of the external carotid artery. *AJNR* **1986**;7:937-942
 16. Kerber CW. Use of balloon catheter in treatment of cranial arterial anomalies. *Stroke* **1980**;11:210-216
 17. Fourman S. Acute closed-angle glaucoma after arteriovenous fistulas. *Am J Ophthalmol* **1989**;107:156-159
 18. Finlay AE, Fogle JA, Green RW. Ciliochoroidal effusion. In: Duane TD, ed. *Clinical ophthalmology*, vol 4. Philadelphia: Harper & Row, **1987**:Ch. 52, 1-19
 19. Buus DR, Tse DT, Parrish RK. Spontaneous carotid cavernous fistula presenting with acute angle closure glaucoma. *Arch Ophthalmol* **1989**;107:596-597
 20. Aaberg TM. Experimental serous and hemorrhagic uveal edema associated with retinal detachment surgery. *Invest Ophthalmol* **1975**;14:248-253