

Are your **MRI contrast agents** cost-effective?

Learn more about generic **Gadolinium-Based Contrast Agents**.



FRESENIUS
KABI

caring for life

AJNR

MR findings in infantile Refsum disease: case report of two family members.

J Dubois, G Sebag, M Argyropoulou and F Brunelle

AJNR Am J Neuroradiol 1991, 12 (6) 1159-1160

<http://www.ajnr.org/content/12/6/1159.citation>

This information is current as
of April 17, 2024.

MR Findings in Infantile Refsum Disease: Case Report of Two Family Members

J. Dubois,^{1,2} G. Sebag,² M. Argyropoulou,² F. Brunelle²

Refsum disease (RD) is a rare autosomal recessive disorder characterized by an accumulation of phytanic acid. A variant of this disease that appears in children has been described and is called infantile Refsum disease (IRD). IRD is characterized by severe sensorineural deafness, retinitis pigmentosa, mental retardation, facial dysmorphism, hepatomegaly, and growth retardation.

We report the MR findings in two family members with IRD. They were diagnosed on the basis of history, clinical findings, and biochemical studies. Distinctive MR abnormalities of the cerebellum in characteristic locations are also demonstrated.

Case Report

At the age of 6 months, this now 17-year-old boy was observed by his parents to have abnormal eye movements. (Pregnancy and delivery were uncomplicated.) An electroretinogram (ERG) at 8½ months confirmed the presence of retinitis pigmentosa. He walked at 24 months, but developmental function was difficult to evaluate. By 5 years of age, bilateral major sensorineural hearing loss and facial dysmorphism were noted, and growth retardation was present.

In his 10-year-old sister, the product of a normal pregnancy and delivery, nystagmus was evident by 2 months of age. ERG confirmed retinitis pigmentosa. By 1 year of age, bilateral profound sensorineural hearing loss was noted, associated with growth retardation and the same facial anomalies as her brother.

The siblings had the same biochemical anomalies but with different levels. Both had raised plasma levels of phytanic acid, associated with an elevation of the fatty acid ratio C26:C22 in the plasma and in cultured skin fibroblasts. Increased serum pipercolic acid levels were also found. The phytanic acid oxidase was deficient. These anomalies were more severe in the sister (Table 1).

Axial and coronal T1- and T2-weighted MR images of the brain were obtained on a 0.5-T magnet using a multislice spin-echo pulse sequence, 380/12/4 and 1800/60,120/2 (TR/TE/excitations), 9-mm-thick sections, and a 128 × 256 matrix.

No abnormalities were noticed on the MR examination of the boy. In the girl, T1-weighted images demonstrated abnormally decreased signal intensity in the dentate nuclei (Fig. 1A), and T2-weighted images showed increased signal intensity in the same area (Fig. 1B).

Discussion

Classic RD is an autosomal recessive disorder with a defect in alpha-oxidation of phytanic acid. The disorder is characterized by retinitis pigmentosa, peripheral neuropathy, and cerebellar ataxia. The onset is insidious in early childhood or young adulthood [1].

This disorder becomes symptomatic in the first year of life, with retinitis pigmentosa, sensorineural hearing loss, and features different from RD; including hepatomegaly, osteopenia, hypercholesterolemia, hypoalbuminoproteinemia, and developmental delay [1–4]. Life expectancy tables are not yet established. The clinical phenotype differs from clinical RD. The mode of inheritance has not been established, but probably is consistent with an autosomal recessive inheritance. Both males and females are affected [1].

IRD is the consequence of a disorder of the phytanic acid metabolism. In RD the number of peroxisomes is normal with a single enzyme deficiency in the alpha-oxidation of phytanic acid. In IRD, there is a variety of biochemical abnormalities that result from a generalized loss of peroxisomal function due to peroxisomal deficiency. Peroxisomes contain several oxidase enzymes that appear to function by oxidizing many substances that might otherwise be toxic. They appear to be responsible for oxidation of phytanic acid, a 20-carbon branched chain fatty acid that is entirely of exogenous dietary origin. It is not only the plasma level of phytanic acid that is raised: the fatty acid ratio C26:C22 is also elevated in the

TABLE 1: Laboratory Findings

	Brother	Sister	Normal
Phytanic acid	16.33	43.84	1.22–6.84 mol/l
Fatty acid ratio			
C ₂₆ :C ₂₂ plasma	0.028	0.379	0.003–0.021
C ₂₆ :C ₂₂ SF*	0.06	0.09	0.04 + 0.02
Pipercolic acid	8.20	79.08	0.70–2.46 mol/l

* SF = serum fibroblasts

Received January 22, 1991; revision requested March 12, 1991; revision received May 1, 1991; accepted May 3, 1991.

¹ Service de Radiologie, Hôpital Ste-Justine, Montreal, Canada.

² Service de Radiologie, Hôpital des Enfants Malades, 149, rue de Sèvres, 75015 Paris, France. Address reprint requests to J. Dubois.

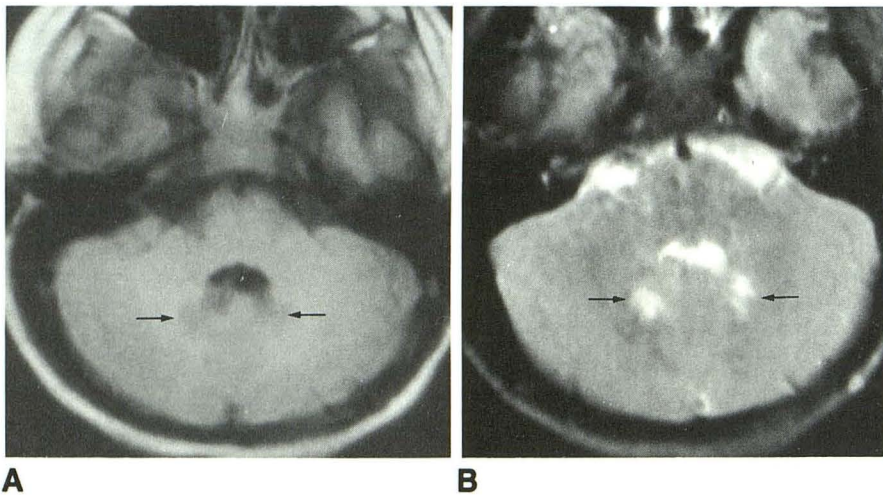


Fig. 1.—MR images of 10-year-old girl with infantile Refsum disease.

A, Axial T1-weighted MR image (380/12/4) shows area of decreased signal in dentate nuclei (arrows).

B, Axial T2-weighted MR image (1800/120/2) shows area of hyperintensity in dentate nuclei (arrows).

plasma, as well as in cultured skin fibroblasts. The plasma has been found to contain abnormal bile acids and increased pipercolic acid levels [2].

The treatment of RD is a strict diet that is low in phytanic acid and phytol. Adherence results in definite clinical improvement. However, in IRD the long-term effects of dietary treatment are not yet known because this disease produces many biochemical abnormalities other than elevated plasma phytanic acid [2].

The literature describes a subtle change in the white matter on pathologic specimens obtained for hypomyelination rather than active demyelination. Descriptions of pathological specimens confirm that IRD causes a diffuse hypomyelination of the brainstem, the olivary, and the dentate nuclei [2]. Focal loss of myelin sheaths with accumulation of fat-laden macrophages and reactive gliosis are found on pathologic specimens. These findings explain the signal abnormalities of the dentate nuclei. No other abnormalities are detected on MR images [2]. To our knowledge this is the first MR study of IRD in children.

A pattern of symmetrical signal abnormalities on MR images involving the region of the dentate nuclei correlates with some pathologic descriptions and appears to be highly suggestive of IRD. However, it might be a difference in the severity of the affection.

In our study of siblings, it is unclear why the brother's MR

examination was normal. The onset of nystagmus, the detection of retinitis pigmentosa, and the onset of sensorineural hearing loss all occurred at an earlier age in the sister. The absolute biochemical levels were different in the two children, with greater abnormalities in the girl. The earlier age of the clinical manifestations and the difference of biochemical levels might provide a clue as to the difference in MR presentation, but heterogeneity of the disease may not be excluded on account of the rarity of the disease.

In conclusion, a pattern of symmetrical signal abnormalities on MR images involving the region of the dentate nuclei correlates with some pathologic descriptions and appears to be highly suggestive of IRD.

REFERENCES

1. Budden SS, Kennaway DP, Buist NR, Poulous A, Weleber RG. Dysmorphic syndrome with phytanic acid oxidase deficiency, abnormal very long chain fatty acids and pipercolic acidemia: studies in four children. *J Pediatr* 1986;108:33-39
2. Valk J, Van Der Knaap MS. *Magnetic resonance of myelin myelination and myelin disorders*. New York: Springer Verlag, 1989:113-118
3. Barth PG, Schutgens RBH, Wanders RJ, Heymans HSA. The spectrum of peroxisomal disorders. In: *Child neurology and developmental disabilities*. Baltimore: Brooker, 1989:69-82
4. Poll-The BT, Saudubray JM, Ogier HA, et al. Infantile refsum disease: an inherited peroxysomal disorder. Comparison with Zellweger syndrome and neonatal adrenoleukodystrophy. *Eur J Pediatr* 1987;146:477-483

The reader's attention is directed to the commentary on this article, which appears on the following pages.