

Are your **MRI contrast agents** cost-effective?

Learn more about generic **Gadolinium-Based Contrast Agents**.



FRESENIUS  
KABI

caring for life

**AJNR**

**Stereotaxic angiography in gamma knife radiosurgery of intracranial arteriovenous malformations.**

W Y Guo, M Lindqvist, C Lindquist, K Ericson, B Nordell, B Karlsson and L Kihlström

This information is current as of April 17, 2024.

*AJNR Am J Neuroradiol* 1992, 13 (4) 1107-1114  
<http://www.ajnr.org/content/13/4/1107>

---

## Stereotaxic Angiography in Gamma Knife Radiosurgery of Intracranial Arteriovenous Malformations

Wan-Yuo Guo,<sup>1,4,5</sup> Melker Lindqvist,<sup>1</sup> Christer Lindquist,<sup>2</sup> Kaj Ericson,<sup>1</sup> Bo Nordell,<sup>3</sup> Bengt Karlsson,<sup>2</sup> and Lars Kihlström<sup>2</sup>

**Summary:** Gamma knife radiosurgery is an effective alternative to embolization or microsurgical removal of small arteriovenous malformations, particularly in eloquent areas of brain tissue. Stereotaxic angiography is a useful diagnostic and targeting adjunct to gamma knife radiosurgery, and the authors present their experience (1,100 patients) with methods and technique, and show how the nidus of the arteriovenous malformation can be defined angiographically. Dose planning employing digitization of the subtraction image enables determination of the spatial coordinates of the lesion by means of an interactive computer program.

**Index terms:** Arteriovenous malformations, cranial; Surgery, stereotaxic; Therapeutic radiology, treatment planning; Cerebral angiography, technique

The concept of radiosurgery was first described by Leksell in 1951 (1). In 1968, the first stereotaxic cobalt-60 gamma knife was installed in Stockholm (2) and, in 1970, this technique was applied to the treatment of an arteriovenous malformation (AVM) (3). The first treatment was performed in a patient with a rather large AVM that was unsuitable for conventional surgery (4). The size of the collimators in the first gamma knife were small and, therefore, prohibited total coverage of the cluster of pathologic vessels of the AVM. The treatment plan for the first patient, however, was designed to deliver radiation that would cause occlusion of the feeding arteries and, subsequently, obliteration of the entire conglomerate of pathologic vessels. This attempt was successful, as proved by a follow-up angiogram in which the AVM could no longer be visualized. In other AVMs, it proved impractical to accurately determine the coordinates for all feeding arteries. Therefore, in small AVMs, the whole cluster of pathologic vessels was included within the irra-

diated volume by using one or multiple isocenters of irradiation. This treatment strategy resulted in obliteration rates of approximately 85% in optimally treated cases (5). Definition and delineation of the AVM "nidus" consequently has become the most important task for stereotaxic angiography. The phrase "a nidus is the heart of an AVM" was first introduced in 1971 by Doppman when describing a spinal cord AVM (6). The concept subsequently acquired broad acceptance and was applied to brain AVMs. Morphologically, a nidus constitutes a network of poorly differentiated and immature vessels toward which multiple feeding arteries converge and from which enlarged veins drain. It represents the site where arteriovenous shunting occurs within an AVM. From the angiographic point of view, the cluster of vessels between the convergent points of multiple feeding arteries and the divergent points of draining veins are the important landmarks when delineating a nidus for radiosurgery.

Gamma knife radiosurgery is an attractive treatment alternative to microsurgical removal or embolization of AVMs, especially for those in eloquent areas of brain. However, the feature can only be taken advantage of when the targeting procedures and the dose planning are equally precise. Theoretically, there is no difference in the catheterization technique between stereotaxic and standard angiography. Their risk and complication are considered to be the same. Diagnostic angiography has always been performed before the scheduling of radiosurgery. Stereotaxic angiography, therefore, is used for diagnostic and targeting purposes. This paper presents the principles and methodology of stereotaxic angiogra-

---

Received June 28, 1991; accepted and revisions requested November 4; revisions received December 10; final acceptance on January 29, 1992.

<sup>1</sup> Department of Neuroradiology, Karolinska Hospital, Karolinska Institute, Stockholm, S-104 01 Sweden.

<sup>2</sup> Department of Neurosurgery, Karolinska Hospital, Karolinska Institute, Stockholm, S-104 01 Sweden.

<sup>3</sup> Department of Radiation Physics, Karolinska Hospital, Karolinska Institute, Stockholm, S-104 01 Sweden.

<sup>4</sup> Department of Radiology, Veterans General Hospital-Taipei, Taiwan, Republic of China.

<sup>5</sup> Address reprint requests to W-Y Guo, Department of Neuroradiology, Karolinska Hospital, Stockholm, S-104 01 Sweden.

phy for gamma knife radiosurgery as developed and currently used in our institution.

## Materials and Methods

### Angiographic Techniques

From January 1970 to May 1991, more than 1,100 stereotaxic angiographic procedures preceding gamma knife radiosurgery of AVMs were performed in our institution. The angiograms of cases treated before February 1990 were obtained using a Coordinat Combi Angiounit using a 0.3-mm focus x-ray tube and AOT film Changer (Siemens, Erlangen, Germany). Since March 1990 the Angioscop Angiounit with Puck Changer and Megalix 125/15/40/82C x-ray tube with switchable focus (0.3, 0.6, and 1 mm) (Siemens) has been used.

The angiographic procedure is preceded by the application of a Leksell stereotaxic frame (Elekta, Stockholm, Sweden) (7). A standard catheterization technique and selective internal carotid, external carotid, or vertebral angiograms are obtained to demonstrate an AVM nidus. For pediatric patients, general anesthesia with hyperventilation technique is usually used. The decrease of  $P_aCO_2$  to the range of 27 to 32 mm Hg during an angiographic procedure will cause contraction of normal subarachnoid arteries but not of pathologic vessels, thus resulting in improved visualization of tumor vessels (8, 9). This effect, although originally reported in tumor cases, is applicable

to AVMs as well. The difference in contraction of the vessels can make the AVM nidus more visible and definable. This technique may be used in any patient but it is more convenient to use controlled hyperventilation under general anesthesia. For AVMs adjacent to eloquent structures or for those with ill-defined margins, it is especially helpful to apply this method.

The amount of contrast medium injection is variable and dependent upon the size and flow rate of the AVM. The injection rate and the total amount are usually higher than that in standard angiograms. The film size of  $24 \times 30$  cm has been used since the beginning. The speed of filming is also variable and dependent upon the size and flow rate of the AVM. As only the AVM nidus should be covered in treatment field, an angiogram of the arterial phase just before the appearance of the draining vein is an ideal one for delineating the nidus for treatment purposes (Fig. 1). For this purpose, in principle, the amount and the rate of the contrast medium injection, and the film speed as well, should be large and high enough to differentiate the AVM nidus from feeders and veins.

For regularly shaped or small AVMs that are supplied by a single arterial territory, a standard anteroposterior (AP) and lateral projections, in which the x-ray beams are orthogonal to the frame, are usually sufficient for delineating and localizing the nidus. For more complicated and for large AVMs, other projections with different angulations of the x-ray tube are necessary, although coordinate deter-

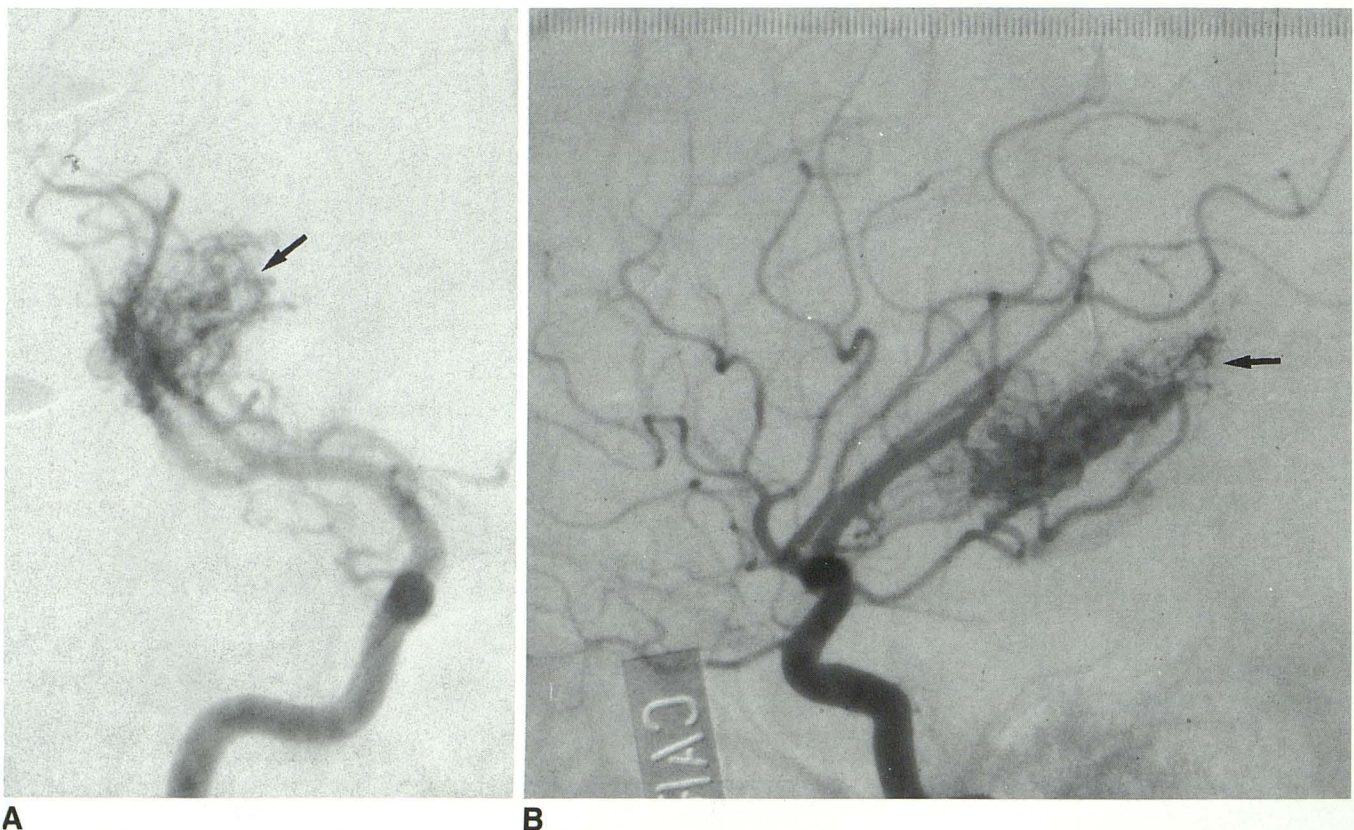


Fig. 1. AP and lateral carotid angiograms showing an ideal phase for delineating an AVM nidus (arrow).




Fig. 2. Device used to fix the localization frame (arrowhead) to the angiographic table (open arrow); the aluminum strips (arrow) are used to adjust the attenuation and increase the clarity of scales.

mination is not performed on these films. These additional projections can provide more information regarding the shape of a nidus and the hemodynamics of an AVM, which can facilitate the treatment planning.

Multiple contrast media injections are required to demonstrate a nidus that has multiple components and are supplied by different major arterial territories. This necessitates a repositioning of the table of the angiounit. To insure that the same positioning was obtained at each series of contrast medium injection, a special baseplate fixation system that attached the stereotaxic frame to the table was used in our first angiounit (10). In our new angiounit, a more compact fixation device (Fig. 2) is available. With these devices, the patient and the table are always moved simultaneously during the angiographic procedure. A wall-mounted laser beam is used as a guide to relocate precisely the patient to the same position for all injections. By using the same positioning, all different components of the AVM nidus can then be overlaid on the same film, creating a complete mapping of the nidus. This composite image is subsequently used for the treatment planning (Fig. 3).

For the subsequent coordinate determination and treatment planning, it is necessary that the Y scales (AP direction) and at least one pair of the Z scales (craniocaudal direction) are visible on the lateral films. For the AP films, the X scales (right-left direction) and at least the Z scales on the lesion side are essential and should be shown on the film. Sometimes, an overexposure of the frame may ob-

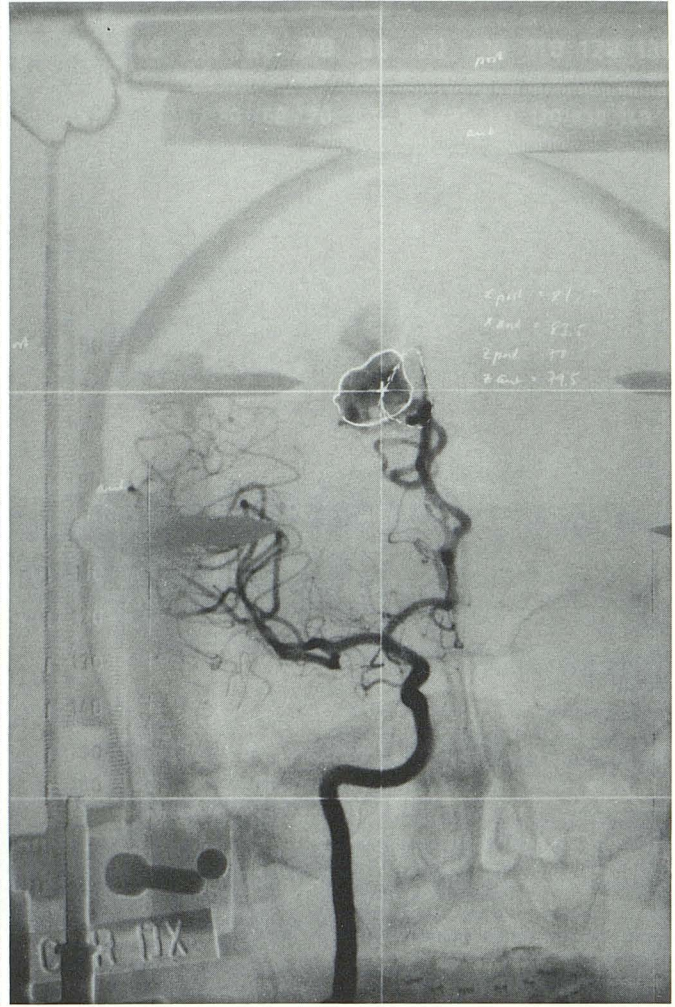
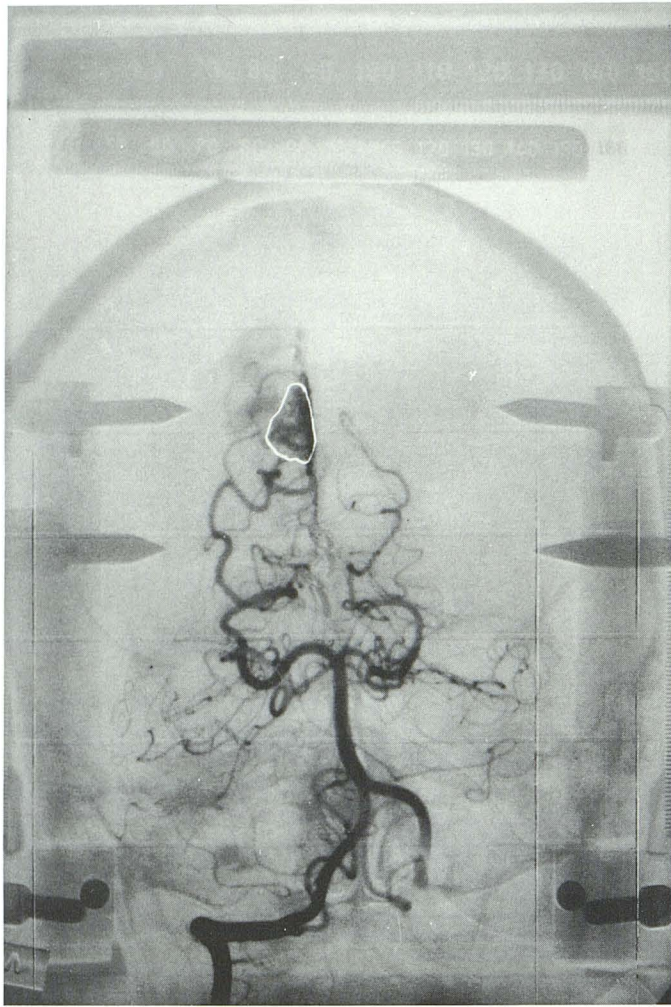
scure the scales. By attaching aluminum strips to the frame, the attenuation can be modulated and the clarity of the scales improved (Fig. 2).

For delineation, the AVM nidus is outlined on the subtraction films taken at those phases just before the appearance of the draining veins. As the scales of the frame are usually subtracted on films, the outline of the nidus is transposed back to its original film. The subsequent coordinate determination and dose planning are performed on the original film.

#### *Determination of Coordinates and Magnification*

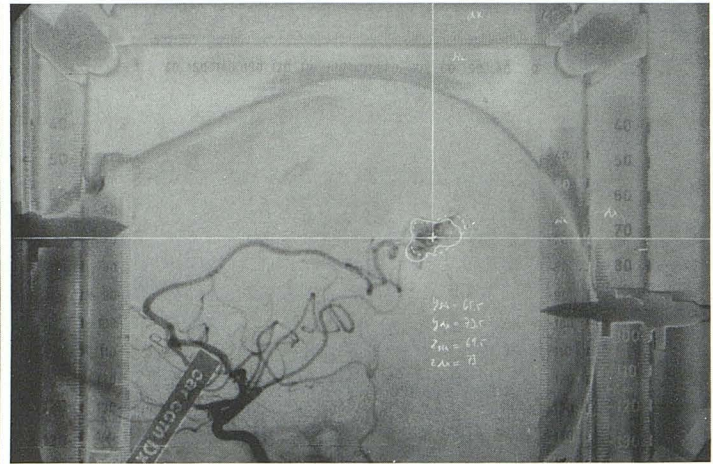
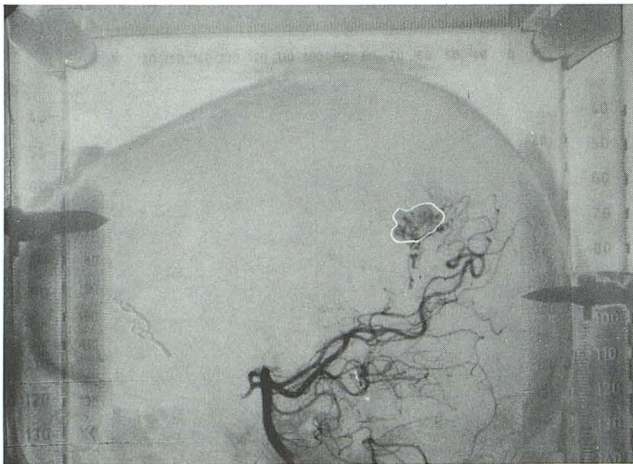
Two reference points are chosen on the angiogram. One is an arbitrary point close to the center of the nidus. This point will be the center of the matrix box. A matrix box can vary in size but should cover the area of interest. Within the box, the absorbed dose of radiation will be determined during the dose planning. The center of the matrix box must be marked on both AP and lateral projections of the angiograms. The orthogonal lines through this point are then drawn on the angiograms to intersect the X, Y, and Z scales at right angles. The figures read from the points that the lines and the scales intersect are used to determine the coordinates of this arbitrary point (Fig. 3). In our institution, two methods for coordinate determination are used independently by a neuroradiologist and a neurosurgeon: a computerized method and a graphic method performed on mm-paper (11, 12). This double check insures the accuracy of the coordinate determination and prevents calculation errors. Another point that must be determined for aligning the dose plan onto the angiogram is the center of the stereotaxic frame. This point is defined by the intersection of the orthogonal lines that are drawn through the midpoints of "100-100 connecting lines" at right angles to each pair of scales (Fig. 4). The projection of this point onto the plane passing through the matrix center can also be determined by the same principle (Fig. 4). Based on these points, the subsequent step of dose planning is performed by the neurosurgeon and the physicist.

The magnification of nidus changes according to its location in the intracranial cavity and the positioning of the patient during an angiography. The magnification of the scales, proximal or distal to the x-ray tube, can be easily determined by comparing the magnified scales and the original scales. As an AVM is a three-dimensional volume and is always located between the scales, the magnification of its nidus is, therefore, between that of the proximal and distal scales. The magnification of a nidus can also be determined graphically on the mm-graphic paper (Fig. 5). Theoretically, the magnification of every part of an AVM nidus is different and can be determined. These differences are, however, insignificant in small and spherical nidi and can be omitted. In larger or "sausage-shaped" nidi, the different magnifications among different parts may be significant and should be taken into consideration in the dose planning in order to minimize an error.



A

B



C

D

Fig. 3. AP and lateral views of carotid and vertebral angiograms showing the reference point (matrix center) of a nidus and composite images for subsequent treatment planning.

- A, AP view of vertebral angiogram: the *continuous line* delineates the nidus fed by branches of the posterior cerebral artery (PCA).
- B, AP view of carotid angiogram: the *continuous line* delineates the nidus fed by the pericallosal artery, and the *interrupted line* delineates the overlaid component fed by the PCA from the vertebral artery.
- C, Lateral view of vertebral angiogram: the *continuous line* delineates the nidus fed by branches of the PCA.
- D, Lateral view of carotid angiogram: the *continuous line* delineates the nidus fed by the pericallosal artery, and the *interrupted line* delineates the superimposed component fed by the PCA from the vertebral artery. The cross marks in the nidus shown on B and D indicate the matrix center for treatment planning; orthogonal lines are drawn through the points. The values read from the intersection of the lines and scales on the frame are used for coordinate determination.

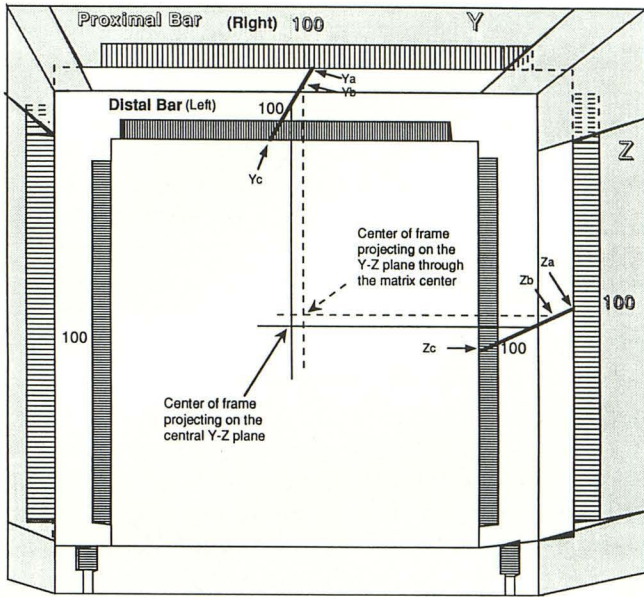


Fig. 4. Schematic diagram showing lateral view of a Leksell localization frame projected on an x-ray film. Two orthogonal *continuous lines* are drawn through the midpoint of "100-100 connecting lines" (YaYc and ZaZc) on the "Y" and the "Z" scales. Their cross-point indicates the position of the frame center projected on the central Y-Z plane. The cross-point of two orthogonal *interrupted lines* indicates the position of the frame center on the Y-Z plane that pass through the matrix center. The points (Yb and Zb), which are the intersecting of the *interrupted lines* and the "100-100 connecting lines" can be determined by the following formulas:

$$YaYb = (YaYc/180) \times (X_R - 10)$$

$$ZaZb = (ZaZc/180) \times (X_R - 10)$$

where  $X_R$ : "X" coordinate of matrix center. (180: the distance between the proximal and the distal scales measured in millimeters.)

*Integration of Dose Plan and Angiogram*

The information obtained from the angiogram is the basis for the dose planning. The dose planning is performed by first selecting a suitable number of shots with a selected collimator size and weighted dose. The dose is calculated at a certain number of points in the dose matrix box, then the isodose curves are calculated and plotted on paper. This paper plot will be superimposed on the angiogram to check the distribution of radiation in the AVM and the surrounding brain structures. For precise alignment of the dose plan and the angiogram, it is crucial to have the magnification correct, the reference points properly marked on the angiogram, and the coordinates of these points accurately located on the dose plan. The center of the stereotaxic frame is a fixed point. It is possible to mark exactly its projection in any plane on the angiogram. This is, therefore, the most reliable point of reference. The position of the matrix center is by definition an arbitrary point and its "Z" coordinates, which may be determined either on an AP or on a lateral film, may, therefore, differ

somewhat in the lateral and AP films. This means that the exact same point has not been marked in these two projections. The distance between the frame center and the center of the matrix along the Y-axis on the lateral film and along the X-axis on the AP film must, however, be the same on the film and on the dose plan for correct alignment.

**Discussion**

We use 24 × 30 cm film instead of 14 × 14 inch film for our angiograms because of its advantages in cost and filing space. The scales that are necessary for coordinate determination, although not seen in their entirety on the small film, can still serve to determine the coordinates accurately. In addition, this accuracy is uninfluenced by the size of the film.

Recently, Sadler et al (13) recommended a technique of slightly misaligning the mask and

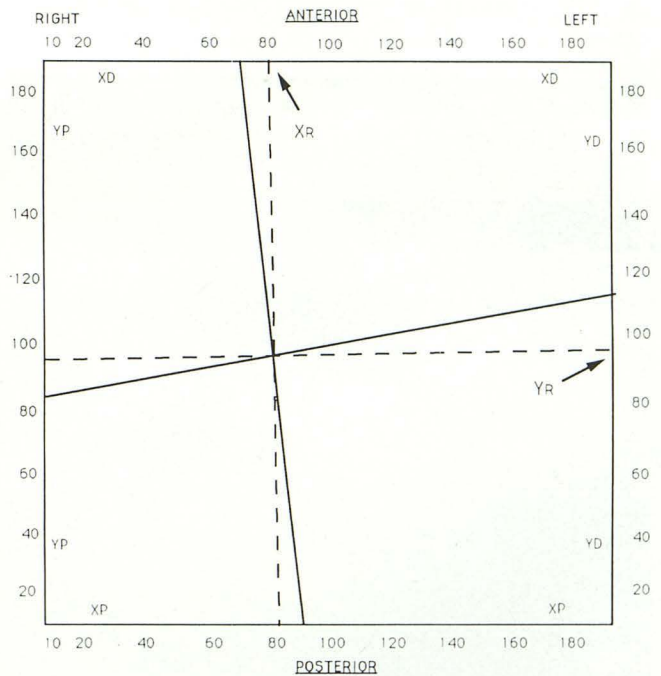


Fig. 5. Schematic diagram showing an example of "X" and "Y" coordinate determination of the matrix center on a mm-paper. The coordinates of the intersection point of two *continuous lines* are the true "X" and "Y" coordinates of the matrix center. Based upon the magnification of "X" and "Y" scales, the magnification of the nidus on the "Y-Z" plane through the matrix center can be determined by the following calculation:

$$\text{Magnification} = M_{YP} - (X_R - 10)(M_{YP} - M_{YD})/180.$$

where YP: proximal scales at Y-direction; YD: distal scales at Y-direction; XP: proximal scales at X-direction; XD: distal scales at X-direction;  $M_{YP}$ : magnification of proximal "Y" scales;  $M_{YD}$ : magnification of distal "Y" scales;  $X_R$ : "X" coordinate of matrix center;  $Y_R$ : "Y" coordinate of matrix center.

the film for subtraction in order to show the scales on the subtraction film for coordinate determination. We use "completely" aligned subtraction films instead. For delineating the nidus, we draw its outline on the subtraction film taken at the phase just before the appearance of draining vein. For coordinate determination, the outline of the nidus is then precisely transposed back to the original film. The coordinate determination and dose planning are performed on this original film. By these steps, not only can the subtraction film demonstrate the outline of the nidus better but also using the original film can diminish any error caused by the subtraction.

Three-dimensional images of the AVM would be ideal for treatment planning. However, the difficulty in performing an axial projection of a stereotaxic angiogram limits the accessibility of true three-dimensional angioimaging reformation. As an angiogram is a dynamic visualization of vascular structures, judging the sequential appearance of different components of the nidus and draining veins and integrating the hemodynamics from different projections can facilitate the delineation of a nidus. This integration can

also offer a three-dimensional perception useful in the subsequent treatment planning.

For AVMs supplied by multiple arterial territories, the repositioning technique allows a complete mapping of all its components on a single film to be used for treatment planning. In some situations, compression of the noninjected artery during contrast medium injection can prevent laminar flow and dilution of the contrast by native blood. This technique is often useful to help fully define the nidus. For example, in thalamic AVMs that are supplied by more than one territory, compression of the carotid artery during contrast injection in the vertebral artery allows maximal contrast filling of the thalamoperforate arteries and delineation of the whole nidus (Fig. 6). This technique is important in most of the deep-seated AVMs, as they are usually supplied by more than one arterial territory.

Several conditions may lead to pitfalls in delineating the nidus. In AVMs presenting with intracranial bleeding, at the acute stage, the intraparenchymal hematoma may cause a mass effect and compress the nidus. This compression can cause underestimation of the true size of the nidus

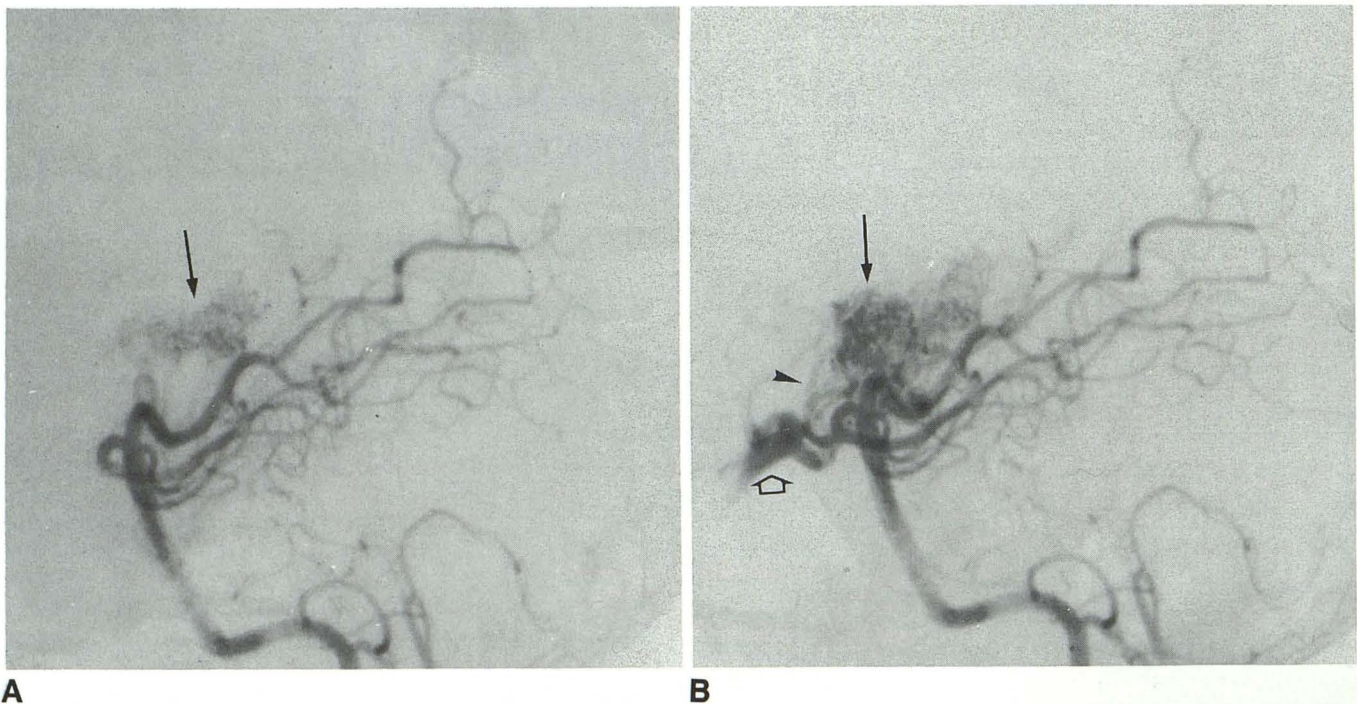


Fig. 6. Lateral view of vertebral angiogram performed without and with compression of ipsilateral carotid artery during the contrast medium injection.

A, Angiogram without compression showing part of the thalamic AVM nidus (arrow).

B, Angiogram with compression showing multiple engorged thalamoperforate arteries feeding the AVM (arrowhead) and all components of the nidus (arrow) as well as the posterior communicating and part of the internal carotid arteries filling in a retrograde fashion (open arrow).

or even misdiagnosis. In some cases, subtotal treatment is obtained by either microsurgery or endovascular embolization procedures. The subsequent development of collateral feeders usually overshadows the true residual nidus and these vessels should not be included in the treatment field (Fig. 7). In these cases, a comparison between the original and the residual nidus is necessary so as not to overestimate the target. For some peripherally located AVMs, the nidus may be obscured by the overlying fixation screws. Meticulous correlation of the nidus displayed on different projections is necessary in these cases to delineate the nidus precisely.

On the angiogram, the arbitrary reference point of the nidus, which is subsequently used as the center of the matrix, and the center of the frame are always used in dose planning. These points can be defined directly on an angiogram after the angiographic procedure. Alternatively, by aligning the x-ray beam to coincide all "100" marks of a stereotaxic frame on a film during the angiographic procedure, the center of the frame may be marked on the angiogram (13). However, the method we use can avoid this time consuming step of x-ray beam alignment. In AVMs with feeders from multiple arterial territories, our repositioning and "nidus-compositing" technique allows these points to be determined by the same method.


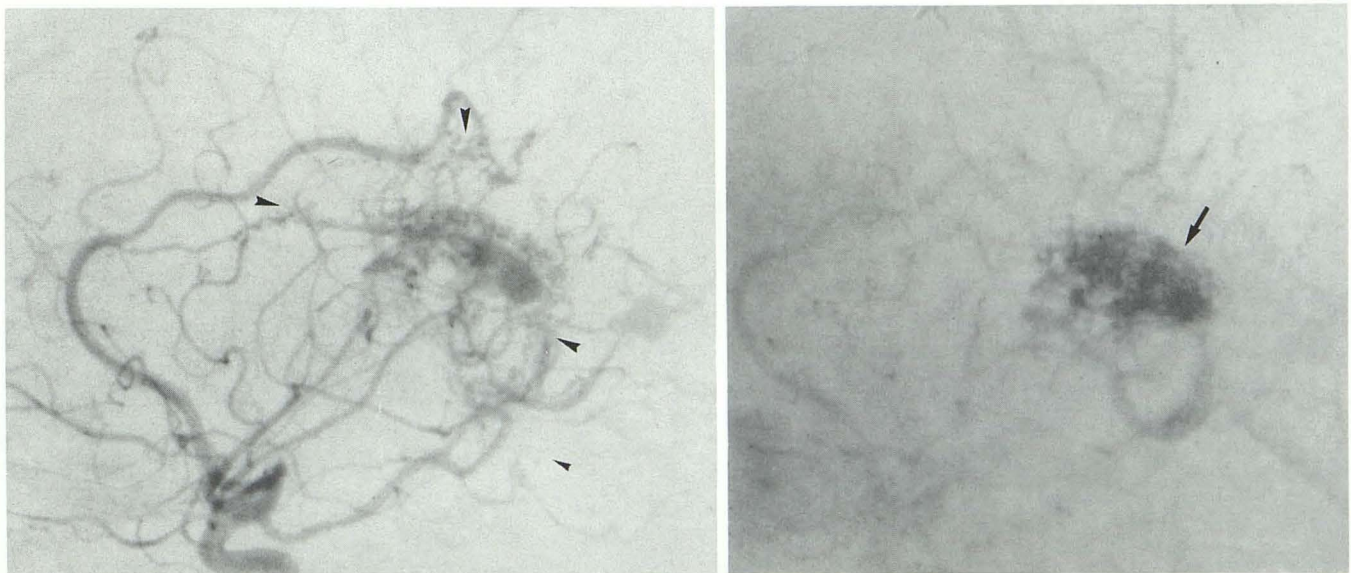


Fig. 8. Localization frame with localizer box (arrows) fixed to the angiographic table. The radio-opaque markers (arrowheads) on the right and left faces of the box are visible.

Recently, a dose-planning system LGP (Leksell Gamma Plan, Elekta) in which the dose plan can be performed directly on the digital images has been tested in our institution. The digitization of the subtractive angiographic film into the computer can be obtained through a simple scanner. This dose-planning system uses a localization box (Fig. 8) similar to that reported by Siddon et al (14). In this method, four radio-opaque markers, small tantalum balls, are fixed in a rectangular configuration to the anterior, posterior, right, and



A

B

Fig. 7. Lateral view of internal carotid angiograms showing a case of a postoperative residual AVM.

A, Early arterial phase showing multiple collateral feeders to the residual AVM that mimic the residual nidus (arrowheads).

B, The true residual nidus (arrow) that should be covered in the treatment field is shown in an angiogram at the later, arterial phase.



left faces of the localizer box. To correctly identify the film orientation, two extra markers are added to the left and anterior faces. With this device, the entire coordinate determination can be performed interactively with a computer. The calculated isodose curves displayed on the monitor can also be integrated into the image, thus increasing the efficiency of this procedure.

## References

1. Leksell L. The stereotaxic method and radiosurgery of the brain. *Acta Chir Scand* 1951;102:316-319
2. Larsson B, Liden K, Sarby B. Irradiation of small structures through the skull. *Acta Radiol Oncol Radiat Phys Biol* 1974;13:512-534
3. Steiner L. Treatment of arteriovenous malformations by radiosurgery. In: Wilson CB, Stein BM, eds. *Intracranial arteriovenous malformations*. Baltimore: Williams & Wilkins, 1984:295-313
4. Steiner L, Leksell L, Greitz T, Forster DMC, Backlund E-O. Stereotaxic radiosurgery for cerebral arteriovenous malformations: report of a case. *Acta Chir Scand* 1972;138:459-464
5. Lindquist C, Steiner L. Stereotactic radiosurgical treatment of arteriovenous malformations. In: Lunsford LD, ed. *Modern stereotactic neurosurgery*. Boston: Martinus Nijhoff, 1988:491-505
6. Doppman JL. The nidus concept of spinal cord arteriovenous malformations: a surgical recommendation based upon angiographic observations. *Br J Radiol* 1971;44:758-763
7. Leksell L, Lindquist C, Adler JR, Leksell D, Jernberg B, Steiner L. A new fixation device for Leksell stereotaxic system: technical note. *J Neurosurg* 1987;66:626-629
8. Harwood-Nash DC, Fitz CR. *Neuroradiology in infants and children*. Saint Louis: Mosby, 1976:685-687
9. Kreuger TP, Rockoff SD, Thomas LJ, Ommaya AK. The effects of changes of end expiratory carbon dioxide tension on the normal cerebral angiogram. *AJR* 1963;90:506-511
10. Bergström M, Greitz T, Steiner L. An approach to stereotaxic radiography. *Acta Neurochir* 1980;54:157-165
11. Bergström M, Greitz T, Ribbe T. A method of stereotaxic localization adopted for conventional and digital radiography. *Neuroradiology* 1986;28:100-104
12. Greitz T, Lax I, Bergström M, et al. Stereotactic radiation therapy of intracranial lesions: methodologic aspects. *Acta Radiol* 1986;25:81-89
13. Sadler LR, Jungreis CA, Lunsford LD, Trapanotto MM. Angiographic technique to precede gamma knife radiosurgery for intracranial arteriovenous malformations. *AJNR* 1990;11:1157-1161
14. Siddon RL, Barth NH. Stereotactic localization of intracranial targets. *Int J Radiat Oncol Biol Phys* 1987;13:1241-1246