AJNR

Cerebral aneurysms: detection and delineation using 3-D-CT angiography.

S Aoki, Y Sasaki, T Machida, T Ohkubo, M Minami and Y Sasaki

AJNR Am J Neuroradiol 1992, 13 (4) 1115-1120
http://www.ajnr.org/content/13/4/1115

Cerebral Aneurysms: Detection and Delineation Using 3-D-CT Angiography

Shigeki Aoki,[1] Yasushi Sasaki,[1] Tohru Machida,[1] Toshiyuki Ohkubo,[1] Manabu Minami,[1] and Yasuhito Sasaki[1]

Purpose: We compared three-dimensional image (3-D-CT) angiography with conventional angiography to determine the clinical usefulness of this technique. **Materials and Methods:** We studied 15 patients with cerebral aneurysms using dynamic CT with intravenous injection of contrast material and reconstructed 3-D-CT angiography. **Results:** 3-D-CT angiography could be performed in conjunction with standard axial high-resolution CT without any additional scanning time and within 10–30 minutes for the overall study. All aneurysms were clearly visualized by 3-D-CT angiography. 3-D-reconstruction was very helpful in demonstrating the neck, shape, and direction of aneurysms, and adjacent vascular and bony structures. One small aneurysm that was difficult to detect on axial images was clearly visualized on 3-D-reconstruction. **Conclusion:** 3-D-CT angiography of cerebral aneurysms could be performed routinely and was helpful in demonstrating the complex anatomy of cerebral aneurysms and surrounding structures. This technique will be of value in surgical planning.

Index terms: Aneurysm, intracranial; Computed tomography, 3-D; Brain, computed tomography; Arteries, cerebral

AJNR 13:1115-1120, Jul/Aug 1992

For many years cerebral angiography has been the technique of choice for demonstrating the intracranial vascular architecture, including aneurysms, but it is invasive, expensive, and subject to a certain percentage of complications. Although magnetic resonance (MR) angiography has been reported to be useful in the evaluation of several cerebrovascular diseases, it has some difficulties in demonstrating aneurysms because of turbulent or slow flow (1–3).

The accuracy of high-resolution axial computed tomography (CT) in the direct diagnosis of cerebral aneurysms has been reported by Schmid et al to be 97.4% (4). They recommended careful on-screen observation before copying images onto films to avoid misinterpretation of axial two-dimensional CT images.

Three-dimensional (3-D)-reconstruction using CT images has been reported in brain tumors (5), facial anomalies (6), cranial bones (7, 8), vertebral diseases (9), pelvic fractures (10), and others. However, few reports have dealt with 3-D-reconstruction in cerebral vascular diseases (11), and to our knowledge, none has dealt with cerebral aneurysms. In the present study, we compared conventional and 3-D-CT angiograms in 15 patients with cerebral aneurysms.

Patients and Methods

Since June 1989 to December 1990, 26 patients with intracranial aneurysms were studied by Seldinger's film angiography of complete intracranial circulation in our hospital. Fifteen patients out of those 26 patients with 15 intracranial aneurysms were also studied using 3-D-CT angiography and these form the basis of this report. In the other 11 patients, 3-D-CT angiography could not be performed because of patient condition or a full scan schedule. Patients' age, sex, and size and location of aneurysms are summarized in Table 1.

Our procedure for 3-D-CT angiography was as follows. After determining the level of the circle of Willis by preliminary thick scan (10 mm), we injected 2 mL/kg of nonionic contrast material (Iopamidol 370, Schering, Berlin, Germany) intravenously within 2 min (about 1 ml/second). Thin-section rapid dynamic CT scanning was started 30 seconds after the injection and lasted about 2 minutes.

Received April 3, 1991; revision requested May 24; revision received on November 1 and accepted November 26.

[1] Department of Radiology, Faculty of Medicine, University of Tokyo, 7-3-1 Hongo, Bunkyo-ku, Tokyo 113, Japan. Address requests for reprints to Shigeki Aoki.

AJNR 13:1115-1120, Jul/Aug 1992 0195-6108/92/1304-1115

Section thickness was 1.5 mm at intervals of 1.5 mm (15–30 sections, 2 seconds per scan plus a 3.5 second intersection delay, 512 × 512 matrix, 12-cm field of view, 120 kV, 120–140 kV (240–280 mAs)). The axial plane was set approximately parallel to the supraorbital-meatal line in order to decrease irradiation to the eyes. 3-D-reconstruction was performed using the GE 9800 HR surface-rendering method (computer programs for 3-D reconstruction have been described elsewhere (12, 13) with a threshold of about 100 HU and reconstruction time of 3 minutes. About 20 different views from different angles of the 3-D image were recorded for comparison (angles were selected by S.A. and Y.S.). After reconstruction of surface image (surface-rendering data set), it took 6.5 seconds to rotate from one angle to the other. We set thresholds and fields of view without using manual tracing or object removal applications, because complicated methods were not practical. Original axial images were also recorded for comparison.

All patients were also studied by conventional film angiography before (two/15) or after (13/15) 3-D-CT angiography. 3-D-CT angiograms alone were retrospectively reviewed blindly by three of the authors (S.A., Y.S., and T.M.) from the viewpoint of aneurysm number. Then we compared 3-D-CT and conventional angiograms from the viewpoint of neck size and position using film angiogram as a standard.

3-D-CT angiography required 2–3 minutes for scanning, 3–4 minutes for 3-D-reconstruction and 6.5 seconds for angle rotation. The total examination time per patient was about 10–30 minutes.

Results

All aneurysms and their necks and parent arteries were clearly visualized on 3-D-CT angiography (Table 1, Figs. 1–4). One middle cerebral artery aneurysm that was extremely difficult to demonstrate on conventional two-dimensional axial images was readily visualized on 3-D images (Fig. 3). 3-D-reconstructed views from different angles were helpful in determining the main direction of the aneurysm, its actual shape, the size of the neck, and its relationship with parent arteries and bony structures. 3-D views from above and below were especially useful in providing information not available from conventional angiograms. Operative views were also helpful for planning surgery and during the operation. Because the surface-rending method shows only the surface (like a shell), the inner surface of aneurysms could be observed by "cutting" them. These unique views were useful for better understanding of the relationship between the aneurysm and its parent arteries.

In giant and relatively large aneurysms, 3-D-CT angiography was helpful in determining a suitable angle on conventional angiography by which to demonstrate the neck and adjacent small vessels.

One false positive aneurysm was found on 3-D-CT angiogram. It was revealed to be due to small branches of artery on conventional angiogram. 3-D-CT angiography occasionally failed to demonstrate small but important vessels such as small posterior communicating and anterior choroidal arteries, which in some cases also could not be identified on conventional angiograms.

Discussion

3-D-CT angiography of cerebral vascular structures can be performed in conjunction with con-

TABLE 1: Summary of patients and aneurysms

Case No.	Age	Sex	Site of Aneurysms	Size (mm)	Neck Size	Neck Site	False Positive An on CT	Recent Hemorrhage	Note
1	61	F	IC-PC	20	A = CT	A = CT	No	No	
2	58	F	Basilar tip	8	A < CT	A = CT	No	No	Right IC stenosis
3	42	M	MCA bifurcation	5	A = CT	A = CT	No	No	Poorly seen on 2D-CT
4	67	F	Intracavernous	25	A < CT	A <> CT	No	No	
5	42	M	A com	35	A = CT	A = CT	Yes	No	Part thromb
6	45	M	VA	20	A = CT	A = CT	No	No	Fusiform, part thromb
7	52	F	IC-PC	3	A = CT	A = CT	No	No	Incidental An
8	54	F	IC-ophthalmic	26	A = CT	A <> CT	No	No	
9	54	F	IC	20	A = CT	A = CT	No	No	
10	54	M	MCA M1	8	A = CT	A = CT	No	No	Fusiform
11	59	F	MCA bifurcation	10	A < CT	A = CT	No	Yes	
12	59	F	MCA bifurcation	12	A < CT	A <> CT	No	No	
13	66	M	VA	15	A = CT	A = CT	No	No	Calcifiction
14	67	F	IC bifurcation	25	A = CT	A = CT	No	No	Fusiform, part thromb
15	68	F	IC-PC	12	A = CT	A = CT	No	Yes	

Note.—MCA = middle cerebral artery; A com = anterior communicating artery; VA = vertebral artery; IC = internal carotid artery; PC = posterior communicating artery; part thromb-partially thrombosed; <> = not equal to; An = aneurysm.

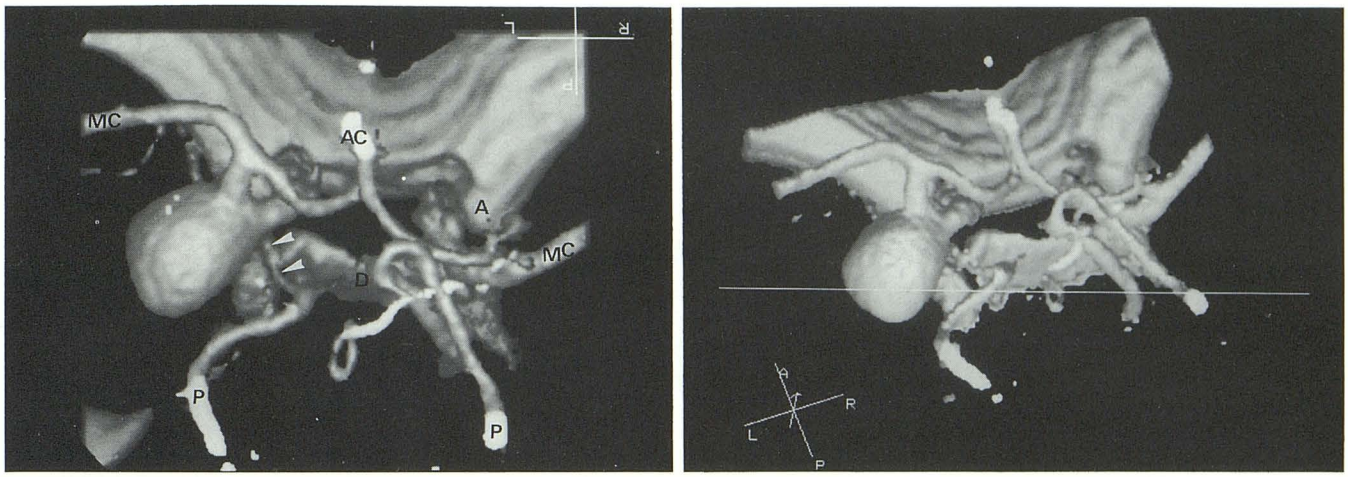

A B

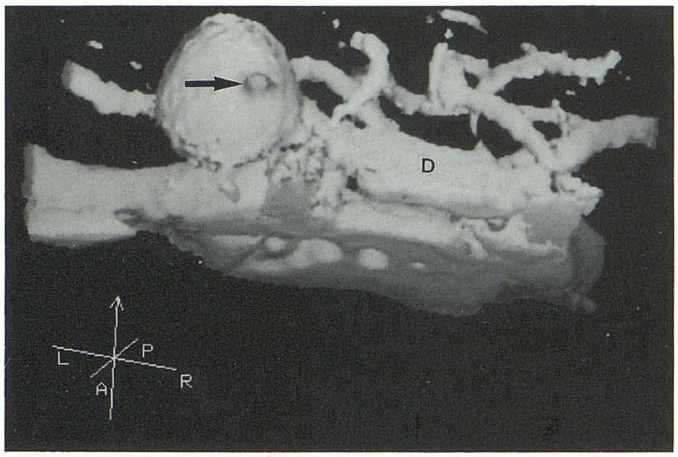

C

Fig. 1. A large ICA-posterior communicating artery aneurysm (case 1).

A, Superior view (view from above). The aneurysm and its neck at the ICA just distal to the posterior communicating artery (*arrowheads*) are clearly demonstrated. *A* = anterior clinoid processes; *D* = dorsum sellae; *AC* = anterior cerebral arteries; *MC* = middle cerebral arteries; *P* = posterior cerebral arteries.

B, Superior-posterior view. The line indicates the cut plane for *C*.

C, Posterior and slightly inferior-lateral view with the cut plane (see *B*) through the aneurysm. The orifice of the aneurysm (*arrow*) was visualized. Because our surface rendering method displayed only the surface of the aneurysm (like a shell), we could observe the inner view of the aneurysm when one "cut" the aneurysm. *D* = dorsum sellae.

Fig. 2. An 8-mm basilar tip aneurysm (case 2). Superior view (view from above). The basilar tip aneurysm (*white arrow*) was visualized with posterior communicating arteries (*arrowheads*). Narrowing of the right ICA due to atherosclerotic changes (confirmed by conventional angiography) was demonstrated as well (*black arrow*). *D* = dorsum sellae; *MC* = middle cerebral artery.

ventional axial high-resolution imaging. Only 2–3 minutes is necessary for scanning and 5–10 additional minutes are needed for processing. This makes the procedure easy to perform routinely.

Compared with conventional angiography, the major advantage of 3-D-CT angiography, in addition to the fact that it is less invasive and inexpensive, is its capacity to provide multiple projections of anatomically complex vascular structures (especially for giant or large aneurysms). "Base view" projections from above and below are especially helpful in clarifying the anatomy of the aneurysm and adjacent vessels. Such images are difficult to obtain by conventional angiography, but can be easily obtained by 3-D-CT angiography. The unique advantage of our surface-rendering 3-D-CT angiography is the view within the aneurysm. 3-D information on the aneurysm and surrounding structures (vessels and bones) can potentially have a significant

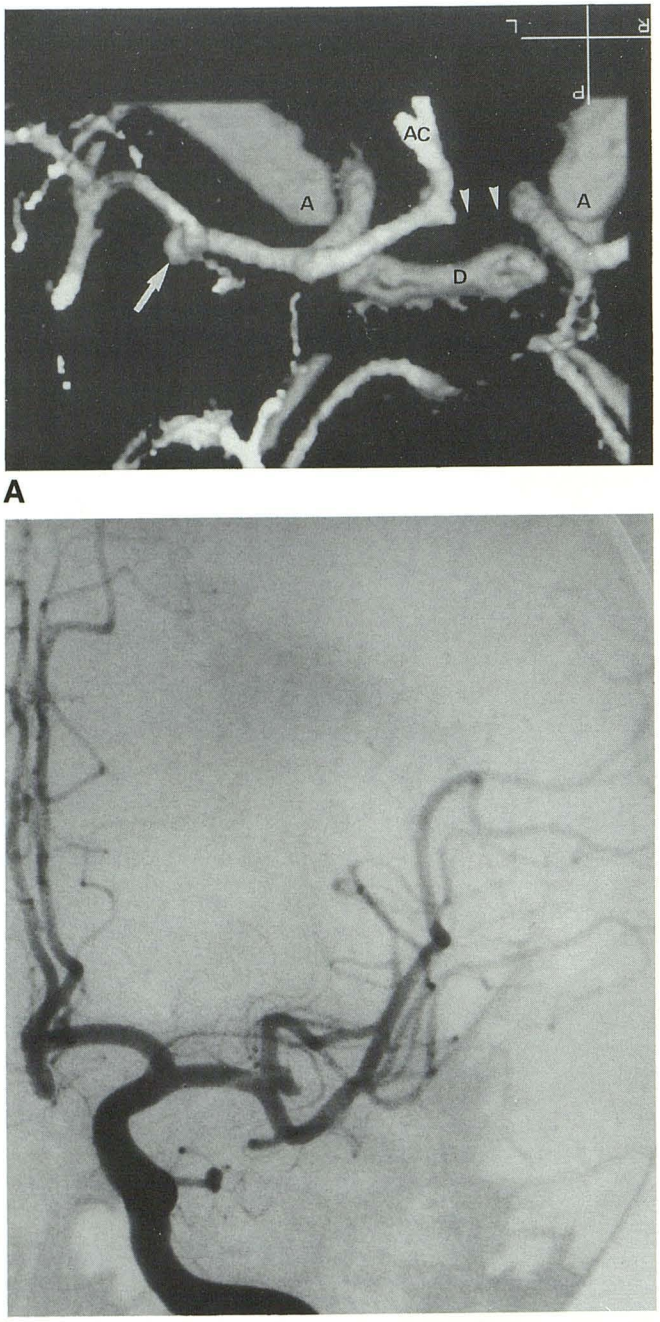

Fig. 3. A 5-mm left middle cerebral artery bifurcation aneurysm (case 3).

A, Superior view (view from above). A small aneurysm is exhibited (*arrow*). The A1 segment of right middle cerebral artery was hypoplastic on conventional angiogram and 3-D-CT suggests it as well (*arrowheads*). *AC* = anterior cerebral arteries; *A* = anterior clinoid processes; *D* = dorsum sellae.

B, Conventional angiogram of the left carotid artery.

impact on decisions regarding surgical indication and surgical approach. The fact that additional views at any angle can be reconstructed whenever it becomes necessary is useful for planning surgery. This also means that, potentially, angiograms from operative views can be reconstructed in the operating room on a real-time basis in the near future.

In giant or large aneurysms, dense opacification of the aneurysm superimposed on adjacent vessels may take identification of the neck difficult using conventional angiography. Several different angles might be necessary to visualize the neck (14, 15). 3-D-CT angiography is useful in this situation to help determine a suitable angle on conventional angiography by which to demonstrate the neck and small vessels.

However, 3-D-CT angiography is inferior to demonstrate small vessels such as hypoplastic posterior communicating artery or the anterior choroidal artery. Since our dynamic scan sequence covers a maximum of 5 cm, it is usually not possible to completely cover both vertebrobasilar and anterior cerebral arteries in one study by our 3-D-CT angiography. This limited field of view is also a disadvantage of 3-D-CT angiography in patients with high clinical suspicion of aneurysms, because multiple aneurysms have to be ruled out. Patient movement might also limit this technique, although sufficient quality images had been obtained in two patients with acute subarachnoid hemorrhage in our study. Therefore, we do not believe that 3-D-CT angiography can substitute for conventional angiography, but we believe it compliments conventional angiography due to better and easy demonstration of 3-D anatomy.

Recently, MR angiography has been developing rapidly (1–3). A preliminary report by Masaryk et al (16) using both spin-echo images and MR angiograms detected 17 of 19 cerebral aneurysms. Nevertheless, MR angiography fails to detect aneurysms that have a very slow flow and underestimates the sizes of those having a turbulent flow. Moreover, thrombus with short T1 (extracellular methemoglobin) can appear bright on MR angiography. Although the 89% accuracy reported in the study of Masaryk et al (15) is high as a preliminary report, it is not superior to the previous report using thin-section CT (4). Contrast-enhanced CT with dynamic scan techniques is very reliable for demonstrating the lumen of aneurysms, because all patent lumina should be enhanced even if there is slow/turbulent flow. Slow and/or turbulent flow and thrombus within or adjacent to aneurysms are still major problems of MR angiography especially in giant ones, al-

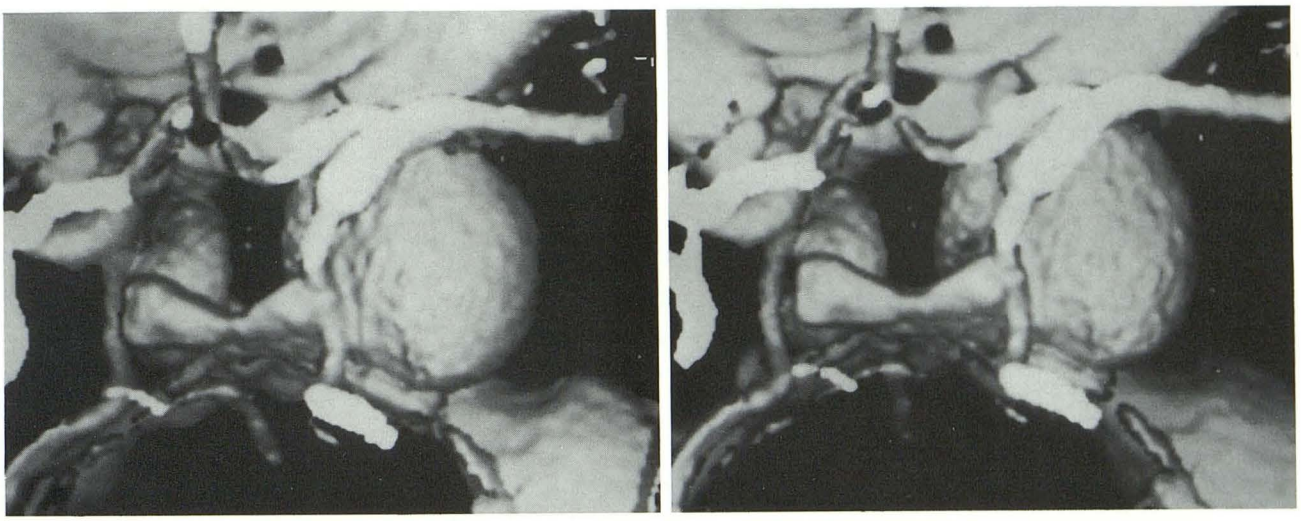

A B

Fig. 4. A giant aneurysm at the cavernous sinus (case 4). Superior views (views from above). *A* and *B* were stereoscopic (lateral tilt with 10° from each other). A large aneurysm was located below the well-developed posterior communicating artery and the posterior clinoid process.

though there will be some progress because there is much research work going on that issue.

In our 3-D-CT angiography, bones were not deleted from reconstruction. This may limit the view from certain angles, but can give the relationship between vessels and bones, which is helpful for planning operation. 3-D-reconstruction is especially useful to grasp the relationship between anterior clinoid processes and internal carotid arteries (ICA). MR angiography can demonstrate only vessels, but lack of information of bones sometimes becomes a disadvantage of MR, such as in ICA aneurysms.

A major disadvantage of 3-D-CT angiography compared with MR is irradiation. The radiation dose to the skin surface in our 3-D-CT angiography is estimated to be 10–30 mGy, according to the report by Gholkar et al (17). This is approximately equal to routine head CT and less than one series of film angiography. Because we avoid direct planes through the orbit, the risk of cataract, which is the primary concern with irradiation in the head, should be lower than with routine CT or with conventional angiography. In patients with aneurysms, several series from different angles are usually performed to visualize the neck on conventional angiography. If 3-D-CT angiography could eliminate one of those series, it would offset the radiation required for this study.

3-D-reconstruction clearly depicted one middle cerebral artery aneurysm that was equivocal on two-dimensional axial CT images. Accuracy of original axial images should be already very high (4). This suggests higher accuracy of 3-D-CT angiography. Although our study was retrospective and patients were limited, 15 out of 16 suspected aneurysms on 3-D-CT angiogram were positive by conventional angiography and no aneurysm was missed. These facts suggest usefulness in screening of patients with relatively low clinical suspicion of aneurysms.

In conclusion, 3-D-CT angiography can be performed routinely, and it provides projections of aneurysms and adjacent vessels that are helpful to recognize the 3-D anatomy of these structures, especially in giant aneurysms. Small aneurysms were also demonstrated clearly. 3-D-CT angiography might be useful in screening aneurysms.

References

1. Masaryk TJ, Modic MT, Ross JS, et al. Intracranial circulation: preliminary clinical results with three-dimensional (volume) MR angiography. *Radiology* 1989;171:793–799
2. Marchal G, Bosmans H, Van fraeyenhoven L, et al. Intracranial vascular lesions: optimization and clinical evaluation of three-dimensional time-of-flight MR angiography. *Radiology* 1990;175:443–448
3. Edelman RR, Mattle HP, Atkinson DJ, Hoogewoud HM. MR angiography. *AJR* 1990;154:937–946
4. Schmid UD, Steiger HJ, Huber P. Accuracy of high resolution computed tomography in direct diagnosis of cerebra aneurysms. *Neuroradiology* 1987;29:152–159
5. Gillespie JE, Adams JE, Isherwood I. Three-dimensional computed tomographic reformations of sellar and para-sellar lesions. *Neuroradiology* 1987;29:30–35
6. Vannier MW, Marsh JL, Warren JD. Three-dimensional CT reconstruction images for craniofacial surgical planning and evaluation. *Radiology* 1984;150:179–184

7. Parisi M, Mehdizadeh HM, Hunter JC, Finch IJ. Evaluation of craniosynostosis with three-dimensional CT imaging. *J Comput Assist Tomogr* 1989;13:1006–1012
8. Howard JD, Elster AD, May JS. Temporal bone: three-dimensional CT. I. Normal anatomy, techniques, and limitations. *Radiology* 1990; 177:421–425
9. Zinreich SJ, Long DM, Davis R, Quinn CB, McAfee PC, Wang H. Three-dimensional CT imaging in postsurgical "failed back" syndrome. *J Comput Assist Tomogr* 1990;14:574–580
10. Burk DL, Mears DC, Kennedy WH, Cooperstein LA, Hebert DL. Three-dimensional computed tomography of acetabular fractures. *Radiology* 1985;155:183–186
11. Katada K et al. Paper presented at 76th Annual Meeting of the RSNA, 1990
12. Frieder G, Gordon D, Reynolds RA. Back to front display of voxel-based objects. *IEEE Comput Graph Appl* 1985;5:52–60
13. Gordon D, Reynolds RA. Image space shading of 3-dimensional objects. *Comput Vision Graph Imaging Proc* 1985;29:361–376
14. Pinto RS, Kircheff II, Butler AR, Murali R. Correlation of computed tomographic, angiographic, and neuroradiological changes in giant cerebral aneurysms. *Radiology* 1979;132:85–92
15. Symon L, Vajda J. Surgical experiences with giant intracranial aneurysms. *J Neurosurg* 1984;61:1009–1028
16. Masaryk TJ, Modic MT, Ross JS, Ruggieri P, VanDyke C, Tkach J. MR angiography of intracranial aneurysms (abstr). *AJNR* 1989;10: 893–894
17. Gholkar A, Gillespie JE, Hart CW, Mott D, Isherwood I. Dynamic low-dose three-dimensional computed tomography: a preliminary study. *Br J Radiol* 1988;61:1095–1099