AJNR

Postoperative dissemination of fat particles in the subarachnoid pathways.

J D McAllister, L N Scotti and J W Bookwalter

AJNR Am J Neuroradiol 1992, 13 (4) 1265-1267
http://www.ajnr.org/content/13/4/1265

This information is current as of October 12, 2024.

Postoperative Dissemination of Fat Particles in the Subarachnoid Pathways

John D. McAllister,[1] Louis N. Scotti,[1] and John W. Bookwalter[2]

Summary: A case of postoperative dissemination of fat particles into the cerebrospinal fluid pathways is reported. Following removal of a foramen magnum meningioma, a postoperative MR scan showed fat droplets in the basal cisterns and in the frontal horns of the lateral ventricles. The patient was asymptomatic and a repeat MR scan 7 months later was normal, with resolution and clearing of the previously noted cerebrospinal fluid fat.

Index terms: Iatrogenic disease or disorder; Magnetic resonance, Postoperative

Spontaneous or surgical rupture of a dermoid cyst is a well-known cause of dissemination of fat throughout the subarachnoid space. Operative or postoperative seepage of fat into the cerebrospinal fluid is a far less likely etiology. We report a case of cisternal and intraventricular "fat wash-in" following surgery for removal of a foramen magnum meningioma.

Case Report

A 65-year-old woman presented with progressive suboccipital headaches, left ear fullness, and numbness of the left thumb and index finger. On physical examination, no neurologic deficits could be demonstrated. A postcontrast magnetic resonance (MR) scan revealed an intense, homogeneously enhancing left anterolateral intradural mass at the level of the foramen magnum that displaced the cervical spinal cord to the right. The preoperative diagnosis was a foramen magnum meningioma (Figs 1 and 2A).

Suboccipital craniotomy and C1 and C2 laminectomy were performed and as the dura was opened in the midline at the level of the foramen magnum, a large left anterior tumor was identified and resected. A CO2 laser was used to coagulate the base of the tumor bed at its dural attachment. The dura was closed in the midline without the use of synthetic or autologous graft. Recovery was uneventful.

MR scan of the brain obtained 7 weeks after surgery showed no residual tumor in the foramen magnum. There were multiple, round, high signal intensity collections consistent with fat in the perimesencephalic and suprasellar cisterns on the short TR images (Figs. 2B and 3A). Fat droplets could also be identified in the most anterior aspect of the frontal horns of the lateral ventricles (Fig. 3C). On long TR images, these areas demonstrated decreased signal intensity isointense to that of the subcutaneous fat (Figs. 3B and 3D). The patient was asymptomatic and a repeat MR scan 6 months later showed no evidence of fat within the subarachnoid or intraventricular space (Fig. 4).

Discussion

The diagnosis of fat fluid levels have been reported on plain films (1), CT and MR (2). The operative complication of dissemination or seepage of fat droplets into the subarachnoid space is a rare event. A literature search revealed a previous case report of postoperative fat within the basal cisterns following a translabyrinthine excision of an acoustic neuroma (3). The authors related this complication to fat grafting in the mastoid cavity.

In our reported case, the exact origin of the fat is uncertain. There was no packing with fat. A possible explanation relates to the use of a CO2 laser to coagulate the tumor bed. This was capable of generating sufficient heat to cause necrosis to a depth of approximately 0.5 mm, the approximate thickness of the dura. This may have allowed seepage of epidural fat into the subarachnoid space, which was then carried by

Received August 8, 1991; revision requested September 11; revision received November 5 and accepted November 8.

[1] Department of Radiology and [2] Neurosurgery, St. Francis Medical Center, 45th Street (off Penn Avenue), Pittsburgh, PA 15201. Address reprint requests to L. N. Scotti, MD.

AJNR 13:1265–1267, Jul/Aug 1992 0195-6108/92/1304-1265 © American Society of Neuroradiology

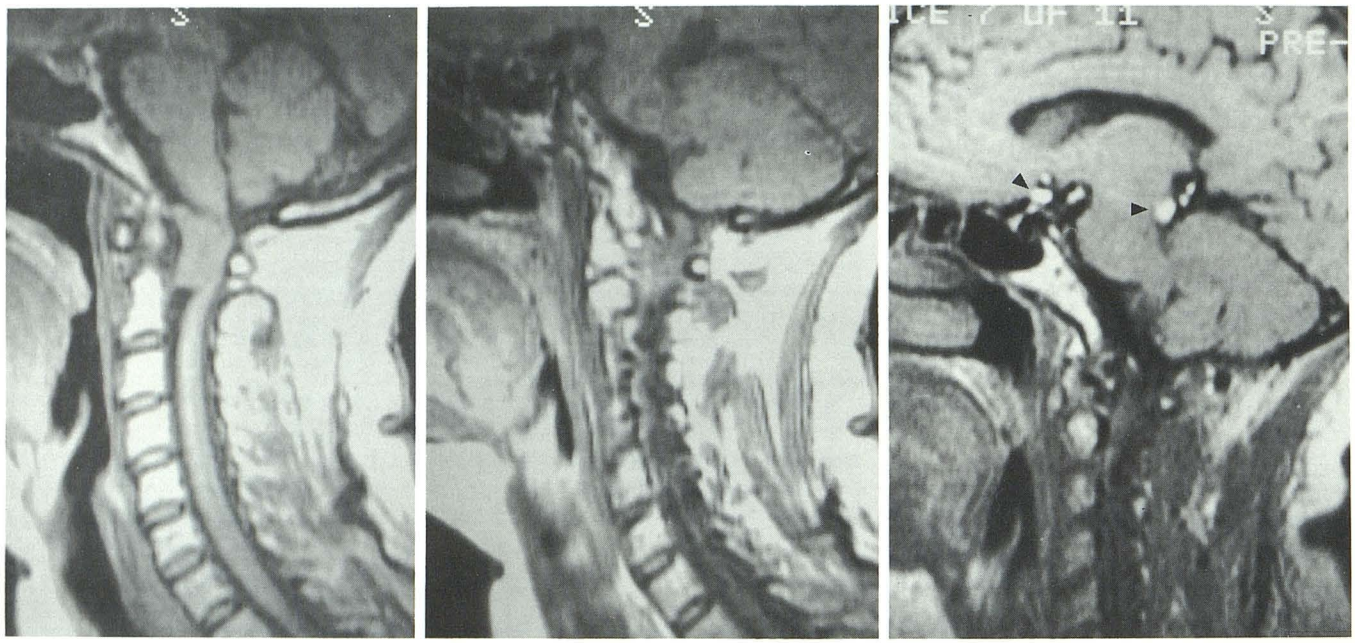

Fig. 1. Preoperative sagittal MR image 560/30/4 (TR/TE/excitations) shows an anteriorly located foramen magnum meningioma.

Fig. 2. *A*, Preoperative parasagittal MR image (560/30) showing normal basal cisterns.

B, Postoperative parasagittal MR (630/30) shows small fat droplets of high signal intensity in the suprasellar and quadrigeminal cisterns (*arrowheads*).

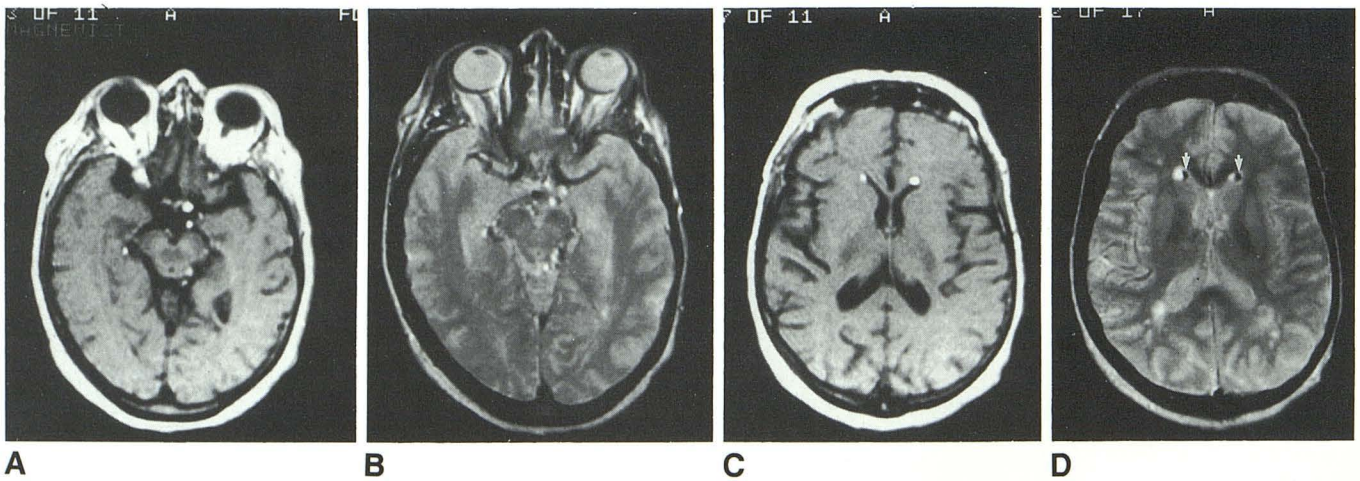

Fig. 3. *A*, Axial MR image (630/30) shows multiple fat droplets in the perimesencephalic cistern.

B, Axial MR image (2075/85) shows the decreased signal intensity of the fat droplets on the long TR image, which are isointense to subcutaneous fat.

C, High signal fat droplets in the anterior aspect of the frontal horns on the axial MR image (630/30).

D, Chemical shift artifact on the long TR axial image (2075/85) (*arrows*).

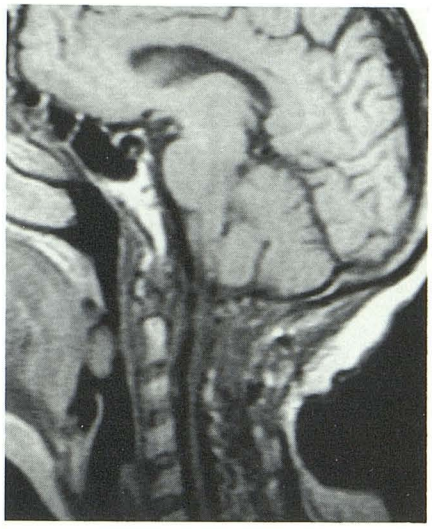

Fig. 4. Parasagittal MR (630/30) 7 months later shows the absence of fat in the subarachnoid spaces.

the cerebrospinal fluid bulk flow into the basal cisterns with reflux into the ventricular system.

In contradistinction to the previously reported case, our patient remained asymptomatic, and there was no clinical or laboratory evidence to suggest an aseptic meningitis. This complication is more frequently seen following rupture of a dermoid cyst (4). It would appear that a meningeal response to mature autogenous fat may be unpredictable.

While admittedly rare, operative seepage and dissemination of fat into the cerebrospinal fluid pathway can occur following a recent paraspinal or intraspinal surgical procedure. The radiologist should be aware of this potential complication and consider it in the differential diagnosis of fat in the subarachnoid space.

References

1. Maravilla KR. Intraventricular fat-fluid level secondary to rupture of an intracranial dermoid cyst. *AJR* 1977;128:500–501
2. Stephenson TF, Spitzer RM. MR and CT appearance of ruptured intracranial dermoid tumors. *Comput Radiol* 1987;11:249–251
3. Reece AT, O'Reilly B, Teasdale E, Todd NV. Subarachnoid fat embolism complicating autologous fat grafting following translabyrinthine excision of acoustic neuroma. *J Laryngol Otol* 1989;103: 870–871
4. Osborne DR. Epidermoid and dermoid tumors: radiology. In: Wilkins RA, Rengachary SS, eds. *Neurosurgery*. New York: McGraw-Hill, 1985:662–667