

Are your **MRI contrast agents** cost-effective?

Learn more about generic **Gadolinium-Based Contrast Agents**.



FRESENIUS  
KABI

caring for life

**AJNR**

**Xenon/CT cerebral blood flow studies during continuous depth electrode monitoring in epilepsy patients.**

D W Johnson, J P Hogg, R Dasheiff, H Yonas, S Pentheny and A Jumao-as

This information is current as of May 7, 2024.

*AJNR Am J Neuroradiol* 1993, 14 (1) 245-252  
<http://www.ajnr.org/content/14/1/245>

# Xenon/CT Cerebral Blood Flow Studies during Continuous Depth Electrode Monitoring in Epilepsy Patients

David W. Johnson,<sup>1</sup> Jeffrey P. Hogg,<sup>2</sup> Richard Dasheiff,<sup>3</sup> Howard Yonas,<sup>2</sup> Susan Pentheny,<sup>1</sup> and Asela Jumao-as<sup>4</sup>

**PURPOSE:** To observe and describe cerebral blood flow (CBF) alterations immediately following depth electrode stimulation of the temporal lobe in patients with medically intractable epilepsy. **MATERIALS AND METHODS:** Five patients with partial epilepsy undergoing presurgical evaluation were chosen for xenon/CT cerebral blood flow (Xe/CT CBF) measurement immediately following electrically stimulated seizures via stereotactically placed temporal lobe depth electrodes. Each patient had a baseline Xe/CT CBF study. Four of the five patients had a total of seven temporal lobe stimulations each followed by a Xe/CT CBF study. The other patient had right temporal lobe electrical status epilepticus and was scanned without stimulation or electroencephalogram monitoring. **RESULTS:** Of the four baseline or interictal scans, no areas of abnormally low flow were detected, but one baseline scan had elevated flows of  $115 \text{ mL} \cdot 100 \text{ g}^{-1} \cdot \text{min}^{-1}$  in the left temporal lobe. One stimulation elicited 8 seconds of afterdischarge potentials, but no alteration of CBF was detected. One stimulation elicited an aura but no electrographic seizure was detected. This resulted, however, in bitemporal lobe elevation of CBF. The other five temporal lobe stimulations resulted in 17–63 seconds of afterdischarge potentials and all resulted in elevation of CBF to  $69\text{--}118 \text{ mL} \cdot 100 \text{ g}^{-1} \cdot \text{min}^{-1}$ . One of these five stimulations resulted in seizure and localized elevation of CBF. Following seizure activity, elevated CBF began to return to baseline levels by 20 minutes. **CONCLUSION:** This study reveals a direct spatial and temporal relationship of elevated CBF with seizures. This study provides the most direct data to date in human subjects that focal seizure activity elevates CBF. Since seizures are known to increase metabolic activity in the activated tissue, this data also supports the assumption of coupling between CBF and metabolism during the pathologic process of a seizure.

**Index terms:** Seizures; Xenon, cerebral blood flow; Computed tomography, xenon study; Brain, temporal lobe

AJNR 14:245–252, Jan/Feb 1993

Accurate localization of seizure foci in patients with medically intractable complex partial epilepsy is often difficult to achieve. Multiple functional and anatomical imaging modalities are often employed in the workup with the hope that the data from these different diagnostic modalities

will converge upon the location of the seizure focus. Many have studied alterations of cerebral metabolism and/or blood flow as they relate to ictus (1–6) but the study of local or global alterations of cerebral blood flow (CBF) during ictus has remained elusive because of the difficulty of obtaining well-documented simultaneous electroencephalographic (EEG) and CBF data coincident with the seizure. Anatomical imaging technologies such as computed tomography (CT) or magnetic resonance (MR) do not lend themselves to imaging seizures but rather depend on imaging structural abnormalities such as mesial temporal sclerosis, tumor, or posttraumatic encephalomalacia that may explain the cause of the seizures. Frequently, there is no obvious anatomic abnormality that identifies the seizure focus. Furthermore, seizures often last only a matter of seconds

Received December 13, 1991; revision requested January 10, 1992; revision received February 25 and accepted March 25.

<sup>1</sup> Department of Radiology, University of Pittsburgh School of Medicine, Presbyterian University Hospital, Pittsburgh, PA 15213. Address reprint requests to D. W. Johnson.

<sup>2</sup> Department of Radiology, University of Pittsburgh School of Medicine, Montefiore University Hospital, Pittsburgh, PA 15213.

<sup>3</sup> University of Pittsburgh Epilepsy Center, (Departments of Neurology and Psychiatry, School of Medicine, and Department of Veteran's Affairs, Neurology Service) Rm 625, 3515 Fifth Ave, Pittsburgh, PA 15213.

<sup>4</sup> 356 E. Chicago St., Cold Water, MI 49036.

AJNR 14:245–252, Jan/Feb 1993 0195-6108/93/1401-0245

© American Society of Neuroradiology

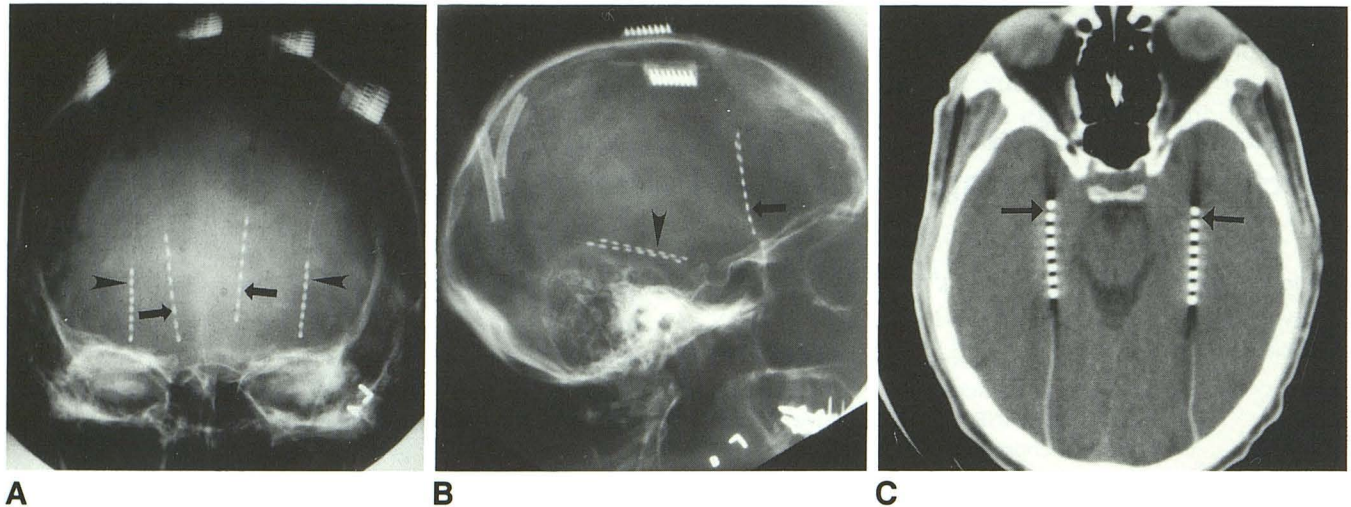


Fig. 1. Typical placement of depth electrodes. A and B, anteroposterior and lateral views of the skull, demonstrating typical location of the frontal (*arrows*) and temporal (*arrowheads*) lobe depth electrodes. C, Axial CT demonstrating location of temporal lobe electrodes. The electrode tips (contacts 1-2) (*arrows*) are placed in the amygdala with the rest of the electrode extending posteriorly through the hippocampus.

to minutes and simultaneous CBF imaging is difficult to obtain.

At our epilepsy center, the presurgical evaluation of patients with medically intractable seizures includes noninvasive imaging with CT, MR,  $^{133}\text{Xe}$  CBF, and Xe/CT CBF measurements. Later, a second phase of more invasive testing is done including stereotactic placement of bitemporal and bifrontal intracranial depth electrodes, allowing continuous depth electroencephalography (CDEEG) to document location, frequency, and type of seizure activity. These patients routinely undergo electrical stimulation via depth electrodes to localize neuronal dysfunction, and to help identify the focus by recapitulating their habitual seizures. A highly selected group of patients were subsequently chosen for simultaneous CDEEG and Xe/CT CBF measurement prior to and immediately following depth electrode stimulation of seizure activity for the purpose of studying the local and regional CBF changes during and immediately following electrically induced seizure activity.

## Materials and Methods

Five patients with simple and/or complex partial epilepsy, refractory to medical therapy, undergoing presurgical evaluation were chosen for Xe/CT CBF measurement immediately following electrical stimulation of seizure activity via the temporal lobe depth electrodes. During prior electrical stimulation these patients demonstrated electroencephalographically recorded seizures with either ab-

sent or only mild clinical symptoms without motion. Thus this group of patients was felt to be most likely to lay motionless during the Xe/CT CBF exam. All studies were performed on the GE 9800 CT scanner. Patients inhaled a mixture of 32% stable xenon and 68% oxygen and were scanned during the first 4.5 minutes of inhalation. A more complete description of the method is described by Johnson et al (7).

The electrode is a flexible cable with eight metallic contacts, designed to spatially locate electrical activity along the contact-bearing portion of the electrode. Each neighboring pair of contacts can be used to stimulate or detect electrical activity in tissue in the immediate vicinity. The location of the electrodes is shown in Figure 1. The very tip of the temporal lobe electrodes were placed in the amygdala with the rest of the electrode extending posteriorly through the hippocampus. The very tip of the frontal lobe electrodes were placed in the orbitofrontal cortex of the frontal lobe.

The electrical stimulus consisted of 0.5 millisecond biphasic square wave pulses, 50 Hz, for 10 seconds applied at constant voltage through a Grass S11 stimulator and two stimulation isolation units. Four subjects received a CDEEG-monitored baseline Xe/CT CBF study prior to depth electrode stimulation. Each of these subjects received at least one (1) 10-second temporal lobe stimulation followed immediately by another Xe/CT study for a total of seven temporal lobe stimulations. In each study, only two levels were imaged by Xe/CT (through the upper temporal and lower frontal lobes above the temporal lobe electrodes, avoiding the eyes). Time interval between the studies was no less than 20 minutes to allow washout of xenon from body tissues. The xenon inhalation was started within seconds after the start of the electrographic seizure, taking 4.5 minutes to acquire the wash-in data. In one

patient, xenon inhalation was started 4 minutes following a 45-second electrographic seizure. One patient had CDEEG-documented electrographic status epilepticus restricted to her right temporal lobe and so was not stimulated. Blood flow maps were analyzed qualitatively, noting geographic distribution of CBF and quantitatively with cortically placed region-of-interest measurements, all 1 cm<sup>2</sup> or larger. Error due to inherent noise of the system is minimized when region-of-interest size is greater than 1 cm<sup>2</sup> (7). In order to highlight pictorially flows above an arbitrary value, all images were computer-enhanced to identify a threshold (Fig. 2). These data were then tabulated and graphed.

## Results

The five patients ranged in age from 21–48 years of age and had a 14- to 37-year history of simple and/or complex partial epilepsy. Each patient had a baseline scan. One patient had two right temporal lobe stimulations and one left temporal lobe stimulation. One patient had both the right and left temporal lobe stimulated. Two patients had one temporal lobe stimulation. Of the four baseline, or interictal scans, where no abnormal electrical activity was recorded, no focal areas of abnormally low flow were detected. Average baseline flows were  $54.8 \pm 13$  mL/100 g/min. Case 1, however, revealed flows of 115 mL/100 g/min in the left temporal lobe. One stimulation elicited an 8-second duration of afterdischarge potentials but no alteration of CBF was detected. One stimulation elicited an aura reported by the patient (case 2) but no EEG-monitored seizure activity was detected. This

resulted in elevation of CBF in both temporal lobe lobes to 74 mL/100 g/min on the left and 65 mL/100 g/min on the right. The other five temporal lobe stimulations resulted in a 17- to 63-second duration of afterdischarges and all resulted in elevation of CBF to 69–118 mL/100 g/min.

Table 1 summarizes our findings in this series. Case 1 is a 27-year-old right hemisphere language-dominant man with onset of epilepsy at age 13. Seizures were simple partial, complex partial, and convulsive. He had a prior right frontal lobectomy for control of his seizures without success, and was being reevaluated for a second epilepsy surgery. Scalp EEG revealed independent right and left temporal lobe spiking. Analysis of ictal depth EEG was complex, with seizures starting from right temporal lobe and left orbitofrontal areas.

His Xe/CT CBF images are illustrated in Figs. 3A–3F. Figure 3G depicts regional CBF (rCBF) as a function of time over the course of his four studies. The patient ultimately underwent a right anterior temporal lobectomy that revealed severe dentate and hippocampal sclerosis. Subsequently, his seizures have come under control with relapses when he misses his antiepileptic drugs.

Cases 2–5 are also summarized in Table 1. Please note that clinical follow-up was limited in case 4 because of her sudden unexplained death. Sudden unexplained death is believed to be the result of seizure-induced cardiac arrhythmia (8).

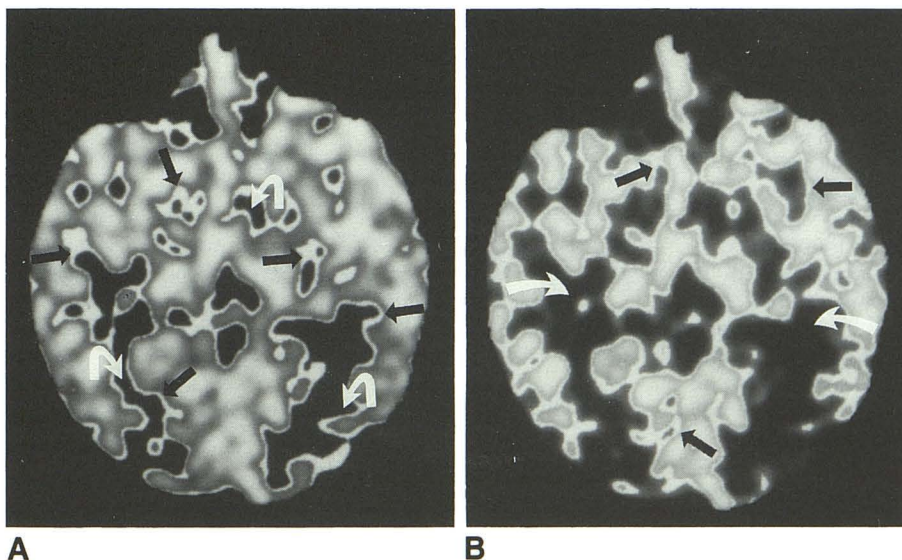


Fig. 2. Explanation of the identify mode.

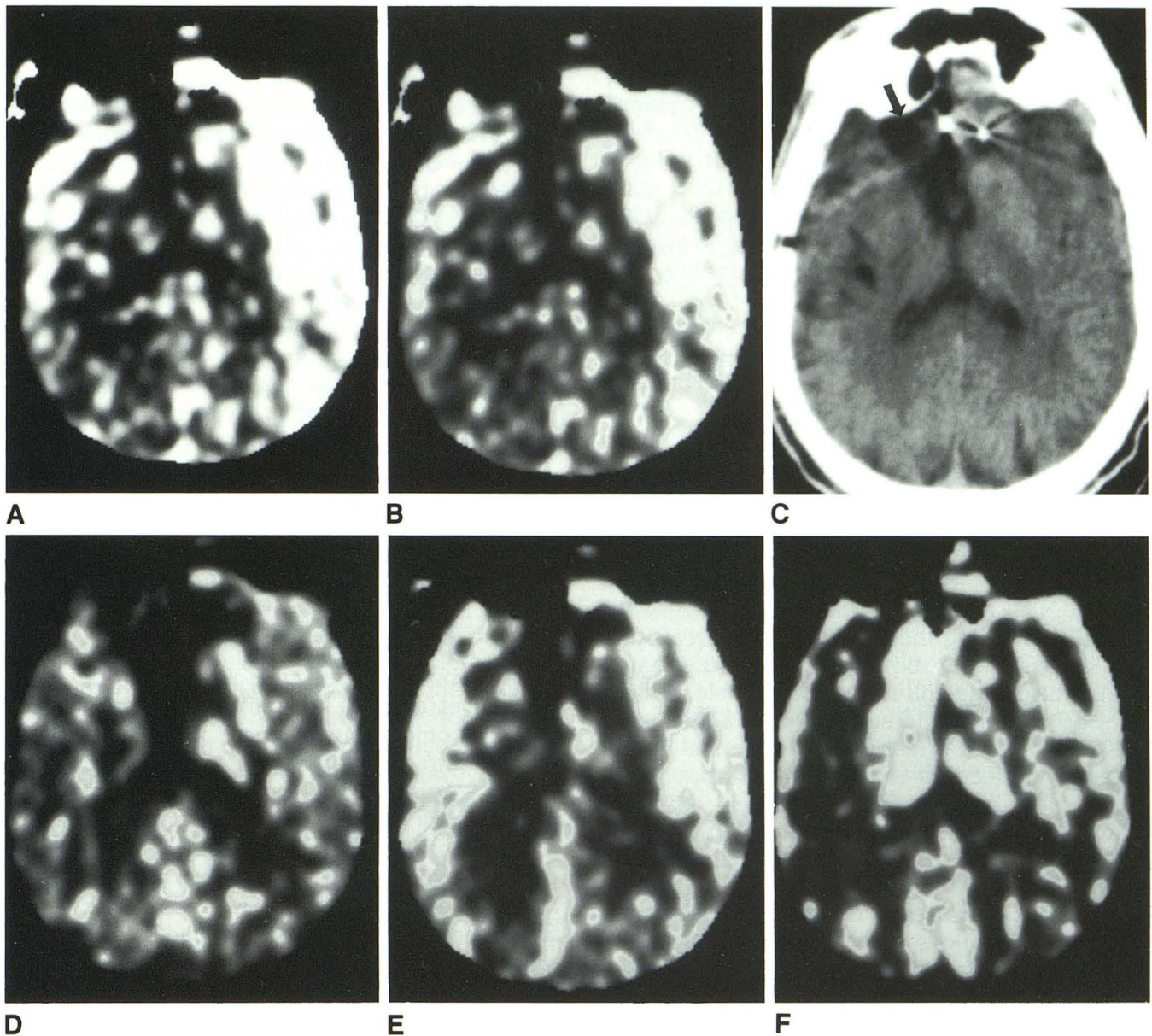
A, For the purpose of highlighting blood flow differences, regions of interest that identify specified blood flow values are superimposed upon the blood flow map. For this image, the specified value level (SVL) is 40 and the specified value range (SVR) is 9. This identifies all pixels with all blood flow values above 44.5 mL · 100 g<sup>-1</sup> · min<sup>-1</sup> as absolute white (black arrows). Values below 35.5 mL · 100 g<sup>-1</sup> · min<sup>-1</sup> are gray to black (curved white arrows) and values between 35.6 and 44.4 are gray to white.

B, On the same image, the SVL/SVR is now set for 60/9. This identifies all pixels (black arrows) with a range of blood flow values from 55.5–64.5 mL · 100 g<sup>-1</sup> · min<sup>-1</sup>. Because a higher range is selected, the gray to black areas (curved white arrows) are larger than in A.

TABLE 1: Summary of findings

Patient No.	Age/ Sex	Time (min)	Area Stimulated	CDEEG Findings	Clinical	rCBF (cc · 100 g <sup>-1</sup> · min <sup>-1</sup> )		Ictal Seizure Foci by CDEEG	Surgery Performed	Surgical Pathology	Clinical Outcome
						Rt	Lt				
						Temporal	Temporal				
1	27/M	0	Baseline	No seizure activity		58	115	Rt temporal, Lt orbitofrontal	Anterior Rt temporal lobectomy	Severe hippocampal sclerosis	Seizure-free on AEDs
		40	Rt amygdala	8-sec AD Rt temporal lobe		45	56				
		60	Lt amygdala	63-sec AD Lt temporal lobe	Also has 35 sec of postictal depression and slurred speech	76	88				
2	48/F	0	Baseline	Epileptiform discharge Lt temporal lobe		49	55				
		20	Rt ant. hipca.	35-sec seizure Rt temporal lobe	10–15 second aura	74	65				
		40	Lt amygdala	No seizure activity	1–2 minutes of auras and visual hallucinations	65	74				
3	41/M	0	Baseline	No seizure activity		55	53	Rt temporal	Anterior Rt temporal lobectomy	Diffuse astrogliosis	Seizure-free on AEDs
		20	Rt amygdala	17 sec AD	Interictal epileptiform discharges seen in both temporal lobes following seizure	79	89				
4	37/F	0	Baseline	Rt temporal status	No stimulation study done	75	57	Rt temporal, Lt, Rt frontal	Anterior Rt temporal lobectomy	Severe hippocampal sclerosis	Sudden unexplained death
5	34/F	0	Baseline	No seizure activity		38	39	Rt frontal, Lt temporal, Rt amygdala	Anterior Rt temporal lobectomy	Cortical gliosis	Reduced seizures on AEDs
		20	Rt amygdala	45-sec seizure in Rt amygdala	Also has 45 sec of clinical symptoms	69	43				

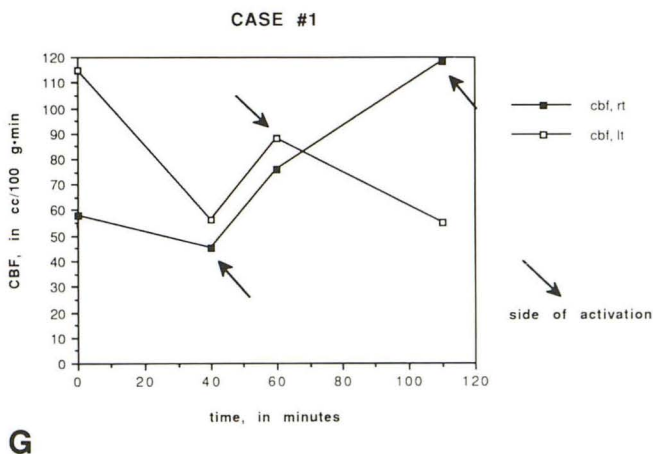
Note.—Rt, right; Lt, left; AED, antiepileptic drug; AD, afterdischarge.



D

E

F



G

Fig. 3. Case 1.

A, Baseline scan. Average right temporal lobe blood flow is  $58 \text{ mL} \cdot 100 \text{ g}^{-1} \cdot \text{min}^{-1}$  and average left temporal lobe blood flow is  $115 \text{ mL} \cdot 100 \text{ g}^{-1} \cdot \text{min}^{-1}$ .

B, Baseline scan with specified value level and range included SVL/SVR is 70/9. There are large areas in the left temporal lobe that are above  $75 \text{ mL} \cdot 100 \text{ g}^{-1} \cdot \text{min}^{-1}$  with fewer areas above that range on the right. The patient was known to have frequent seizures in the morning and may have had an unmonitored seizure during transport to the CT scanner while the EEG was disconnected.

C, CT demonstrates prior partial right frontal lobectomy (arrow). Note also the metal artifact from the frontal electrodes (white arrows).

D, Forty minutes after the first scan, the right amygdala is stimulated. Average right temporal lobe blood flow is  $45 \text{ mL} \cdot 100 \text{ g}^{-1} \cdot \text{min}^{-1}$ . Average left temporal lobe blood flow has now decreased to  $56 \text{ mL} \cdot 100 \text{ g}^{-1} \cdot \text{min}^{-1}$ . SVL/SVR is 70/9. There are fewer areas of flow above  $75 \text{ mL} \cdot 100 \text{ g}^{-1} \cdot \text{min}^{-1}$  in the left temporal lobe. (Continued on page 250)

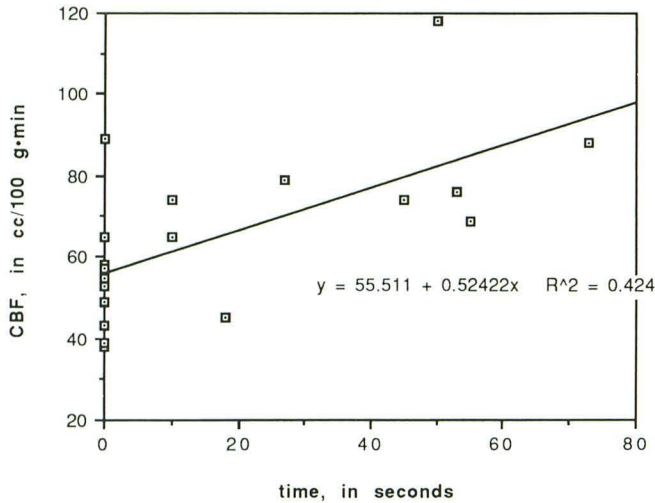


Fig. 4. CBF versus length of time of after-discharge potentials.

We attempted to find a quantitative relationship between the duration of afterdischarge and rCBF. Figure 4 is a scatterplot of the relevant data. It is technically not possible to record the depth EEG during the 10-second electrical stimulus. However, the stimulus itself is equivalent to an afterdischarge and should be capable of altering CBF, therefore, 10 seconds were added on to the time of each afterdischarge potential we recorded to reflect the total duration of brain activation. Because we believe that case 1 did experience an unmonitored seizure in the left temporal lobe prior to the baseline scan, we felt we could exclude that data point. We also excluded data from case 4, because her right temporal lobe was in status epilepticus. Focal status represents a qualitatively different phenomena from the discrete seizures the other patients had, either spontaneously or evoked by our stimulation.

## Discussion

Electrical, drug-induced, or psychophysiological seizure activation studies have long been considered a useful tool in epileptology. Early studies documented an increase in cerebral circulation that accompanied the electrical discharge (9, 10). Observations of altered CBF dur-

ing and after electrical stimulation of seizures in animals and human subjects were also described by Penfield et al in 1939 (11). Through a craniotomy, a heated thermocouple was placed into the cortex or basal ganglia. Because arterial blood is cooler than brain parenchyma, regional increases in blood flow will cause cooling of the thermocouple. Blood flow could not be quantified but the observation of flow alteration could be documented and the elapsed time for return to baseline parenchymal temperature could be recorded. Time for parenchymal temperature to return to baseline was about 3 minutes. Type and duration of seizure activity were not clear from Penfield et al's description (11). They concluded that circulatory increase began shortly after the onset of local neuronal discharge and was probably secondary to increased ganglionic activity. Jasper and Erickson studied alterations of local CBF and pH in response to metrazol (pentamethylenetetrazol) and electrical stimulation of seizure activity using a similar technique and also found that local CBF closely followed EEG changes but preceded changes in pH (12).

Ueno et al used  $^{14}\text{C}$ -antipyrine as a tracer of CBF in monkeys and showed changes in rCBF in response to intracortically injected penicillin-induced seizures (13). Hougaard et al measured regional CBF with  $^{133}\text{Xe}$  correlated with simultaneous EEG changes in four patients during clinical seizure activity (6). Three showed marked focal hyperemia in those areas where EEG was also abnormal but one patient had focal hyperemia and a normal EEG. Interictal flows were also measured in three of the four and in another six patients. Focal hyperemia was observed either spontaneously or in response to intermittent light stimulation, but EEG recordings showed paroxysmal activity in only four of the nine. They felt the lack of correlation between the EEG and rCBF findings was due either to the focus localizing to a deeper structure not involving cells contributing to the scalp EEG recording or the fact that some paroxysmal activity originated in the superficial cortex that was not recorded by EEG.

Fig. 3—Continued. E, Sixty minutes after the first scan, the left amygdala was stimulated. Average right temporal lobe blood flow is  $76 \text{ mL} \cdot 100 \text{ g}^{-1} \cdot \text{min}^{-1}$ . Average left temporal lobe blood flow is  $88 \text{ mL} \cdot 100 \text{ g}^{-1} \cdot \text{min}^{-1}$ . SVL/SVR is 70/9.

F, One hundred and ten minutes after the first scan, right amygdala was again stimulated. Blood flow in the left basal ganglia just above the amygdala is  $118 \text{ mL} \cdot 100 \text{ g}^{-1} \cdot \text{min}^{-1}$ . Blood flow in the right basal ganglia just above the amygdala is  $55 \text{ mL} \cdot 100 \text{ g}^{-1} \cdot \text{min}^{-1}$ . Blood flow in the lateral right temporal lobe cortex has decreased to  $43 \text{ mL} \cdot 100 \text{ g}^{-1} \cdot \text{min}^{-1}$  and the left lateral temporal lobe cortex has decreased to  $67 \text{ mL} \cdot 100 \text{ g}^{-1} \cdot \text{min}^{-1}$ . SVL/SVR is 70/9.

G, Graph of CBF versus time of case 1. Notice that elevated CBF returns to near normal baseline levels in the left temporal lobe after the first and third scans.

Sakai et al also correlated rCBF measurements with EEG in epileptic patients who underwent multiple psychophysiological (motor speech and audiovisual) activation (14). These results, compared with a normal control group, revealed that epileptogenic foci are often accompanied by regional hyperemia interictally or in response to activation. Eleven patients with partial seizures showed substantial regional flow increases in anatomical areas of the brain that correlated with the EEG focus. Another nine showed flow increases in response to psychophysiological activation. They observed regional hyperemia with a surrounding border of decreased flow which they attributed to a primary inhibition of surrounding neuronal activity, a phenomena known to occur rendering this borderzone refractory to excitation. They felt that rCBF measurement may have some usefulness in localization of epileptogenic foci in those whom the EEG may be normal or equivocal and that activation studies may reveal otherwise quiescent epileptogenic foci.

Lee et al performed ictal studies in 16 patients with intractable epilepsy with HIPDM-SPECT, correlating these findings with simultaneously recorded EEGs (2). They were able to localize epileptic foci in 13 of 14 patients with a unilateral temporal lobe focus. There were, however, two patients with bitemporal foci that showed only slightly increased regional cerebral perfusion in bilateral multifocal regions. They felt that adequate interpretation was hampered by the inability to measure rCBF quantitatively, speculating that bilateral multifocal epileptic foci may require smaller increases of cerebral metabolic rate and subsequently smaller increases of CBF.

Valmier et al studied 40 epileptic and 10 normal patients with  $^{133}\text{Xenon}$  (15). Studied interictally, he found that during intermittent light stimulation, in epileptic patients without lesions seen by CT, the suspected seizure focus showed significant rCBF increase and in those patients who had a lesion by CT, significant rCBF increases were not in the region of suspected epileptic focus but in adjacent or contralateral areas. There were five patients that had a seizure several hours before their activation study. Resting studies showed increased rCBF that corresponded to the site of the seizure focus suggesting a "subictal phase." Activation studies showed a variable flow pattern, but usually a flow decrease in the region of resting hyperemia. They concluded that activation studies in this subictal phase will yield different flow patterns. They also felt that activation testing is

useful in improving the accuracy of epileptic focus localization.

Electroencephalography remains the gold standard in seizure localization. Continuous monitoring for extended periods of time is quite feasible but there are important limitations as well. Scalp EEG recordings cannot localize foci originating in deeper structures and depth EEG is invasive and carries with it a low but not insignificant probability of morbidity or mortality. The literature suggests that activation studies can reveal quiescent foci. Cross-sectional CBF evaluation may be a useful alternative if it is repeatable and if it lends itself conveniently to activation testing. Our method of CBF testing has the unique advantage of being able to quantitatively measure blood flow in cross-section and can be repeated within as little as 20 minutes. It is, however, limited by radiation dose, and cannot survey more than 2–3 levels of the brain.

Several observations may be made from our series. First is that baseline flows were normal, averaging about  $55 \text{ mL} \cdot 100 \text{ g}^{-1} \cdot \text{min}^{-1}$ . Second, we could not localize seizure foci based on interictal flows. Third, we estimated the temporal nature of blood flow elevation with seizure activity. Case 1 illustrates this observation. Making the assumption that elevated flows on the baseline scan in the left temporal lobe were indeed secondary to a prior unmonitored seizure, one can see that elevated flows returned to baseline levels twice in a 110-minute period, each time dropping to normal levels by 40–50 minutes (Fig. 3G). In case 2, elevated flows in the right temporal lobe drop  $9 \text{ mL} \cdot 100 \text{ g}^{-1} \cdot \text{min}^{-1}$  in 25 minutes after stimulation of that lobe. Return to baseline may occur in less time. Dymond and Crandall, using depth electrodes and monitoring intracerebral temperature changes to follow local CBF changes in patients with spontaneous seizures found that elevated flows following seizure returned to baseline levels by about 10 minutes (16). Fourth, our case 1 also illustrates the tight spatial linking of seizure activity and CBF elevation. The seizure caused by the final stimulation did not generalize and in fact was limited to the immediate vicinity of the right amygdala (Fig. 3F). The section location is immediately above the amygdala and posterior hippocampus, in order to avoid artifact from the metal probe, and shows localized increased flow. It also shows decreasing flows in the superficial temporal cortex on the right, suggesting that the seizure did not generalize beyond the mesial structures.



A fifth observation from this study is the direct relationship between the length of afterdischarge and the degree of elevation of CBF (Fig. 4). We are not aware of any other literature that reflects this relationship. The one exception is case 4 who was in electrical status epilepticus where blood flow is only moderately elevated. There is some speculation that status epilepticus is not the same disease as simple or complex partial epilepsy. For this reason we excluded this data point from the graph.

Although stable Xe/CT proved reliable and accurate in identifying an actively firing seizure focus (an ictal event), it proved insensitive in identifying the habitual seizure foci in four of the five patients. The exception being case 4 who was in electrical status epilepticus. This seems at variance with reports in the literature as well as our own expectations. During an ictal event both metabolism and blood flow appear coupled and both increase. The expectation would be that both would be decreased compared to surrounding tissue, or control values for similar anatomical areas. However, we did not find this so. It is possible that although metabolism and CBF are coupled during a seizure, they are uncoupled interictally. If so, interictal scanning would be of little value in the presurgical evaluation of epilepsy patients. We plan to study this in a larger patient population.

## References

1. Kuhl DE, Engel J, Phelps ME, Selin C. Epileptic patterns of local cerebral metabolism and perfusion in humans determined by emission computed tomography of  $^{18}\text{F}$ FDG and  $^{13}\text{N}$ H<sub>3</sub>. *Ann Neurol* 1979;8:348-360
2. Lee BI, Markland ON, Wellman HN, et al. HIPDM-SPECT in patients with medically intractable complex partial seizures. *Arch Neurol* 1988;45:397-402
3. Sperling MR, Wilson G, Engel J, Babb TL, Phelps M, Bradley W. Magnetic resonance imaging in intractable partial epilepsy; correlative studies. *Ann Neurol* 1986;20:57-62
4. Stefan H, Pawlik G, Böcher-Schwarz HG, et al. Functional and morphological abnormalities in temporal lobe epilepsy: a comparison of interictal and ictal EEG, CT, MRI, SPECT, and PET. *J Neurol* 1987;234:377-384
5. Valmier J, Touchon J, Daures P, Zanca M, Baldy-Moulinier M. Correlations between cerebral blood flow variations and clinical parameters in temporal lobe epilepsy: an interictal study. *J Neurol Neurosurg Psychiatry* 1987;50:1306-1311
6. Hougaard K, Oikawa T, Sveinsdottir E, Skinhøj E, Ingvar DH, Lassen NA. Regional cerebral blood flow in focal cortical epilepsy. *Arch Neurol* 1976;33:527-535
7. Johnson DW, Stringer W, Marks MP, Yonas H, Good W, Gur D. Stable xenon/CT cerebral blood flow imaging: rationale for and role in clinical decision making. *AJNR* 1991;12:201-213
8. Dasheiff RM. Sudden unexplained death in epilepsy: a series from an epilepsy surgery program and speculation of the relationship to sudden cardiac death. *J Clin Neurophys* 1991;8:216-222
9. Gibbs FA. Cerebral blood flow preceding and accompanying experimental convulsions. *Arch Neurol Psychiatry* 1933;30:1003-1010
10. Gibbs FA, Lennox WG, Gibbs EL. Cerebral blood flow preceding and accompanying epileptic seizures in man. *Arch Neurol Psychiatry* 1934;32:257-272
11. Penfield W, von Santha K, Cipriani A. Cerebral blood flow during induced epileptiform seizures in animals and man. *J Neurophysiol* 1939;2:257-267
12. Jasper H, Erickson TC. Cerebral blood flow and pH in excessive cortical discharge induced by metrazol and electrical stimulation. *J Neurophysiol* 1941;4:333-347
13. Ueno H, Yamashita Y, Caveness WF. Regional cerebral blood flow pattern in focal epileptiform seizures in the monkey. *Exp Neurol* 1975;47:81-96
14. Sakai F, Meyer JS, Naritomi H, Hsu MC. Regional cerebral blood flow and EEG in patients with epilepsy. *Arch Neurol* 1978;35:648-657
15. Valmier J, Touchon J, Baldy-Moulinier M. Interictal regional cerebral blood flow during non specific activation test in partial epilepsy. *J Neurol Neurosurg Psychiatry* 1989;52:364-371
16. Dymond AM, Crandall PH. Intracerebral temperature changes in patients during spontaneous epileptic seizures. *Brain Res* 1973;60:249-254