

Cerebrovascular Transit Characteristics of DyDTPA-BMA and GdDTPA-BMA in Normal and Ischemic Cat Brain

J. Kucharczyk,^{1,3} H. Asgari,¹ J. Mintorovitch,¹ Z. Vexler,¹ S. Rocklage,² A. Watson,² and M. Moseley¹

PURPOSE: To compare the efficacy of two nonionic T2*-shortening contrast agents, DyDTPA-BMA dysprodiamide injection and GdDTPA-BMA gadodiamide injection, as perfusion-sensitive MR imaging agents in normal and acutely ischemic brain. **METHODS:** The magnetic susceptibility effects of intravenous injections of 0.10–0.50 mmol/kg of each contrast agent were quantified on T2-weighted spin-echo images of cat brain before and after unilateral occlusion of the middle cerebral artery by measuring signal intensity changes in the same regions-of-interest in parietal cortex. **RESULTS:** In normal brain, DyDTPA-BMA produced a significantly greater loss of signal intensity than equimolar doses of GdDTPA-BMA. The magnitude of the signal intensity attenuation was dosage-dependent and proportional to the square of the magnetic moments of the two contrast agents. Restoration of baseline image signal intensity was observed within 30 min after each injection. However, injection of GdDTPA-BMA also produced a delayed, persistent hyperintensity on T2-weighted images, presumably due to its underlying T1-shortening effect. Following unilateral occlusion of the middle cerebral artery, unenhanced T2-weighted images failed to show evidence of cerebral injury for 1.5–3 hours. Administration of 0.10–1.0 mmol/kg DyDTPA-BMA shortened the time for detection of perfusion deficits (residual hyperintensity) in 22 of 36 (61%) treated cats, often to within 30 min after arterial occlusion. DyDTPA-BMA enhancement also improved lesion conspicuity in 26 of 36 (72%) cases, and disclosed very small infarcts that were not visible on T2-weighted precontrast images. Perfusion deficits in areas of partial ischemia were seen more clearly on DyDTPA-BMA-enhanced images than after equimolar injections of GdDTPA-BMA. **CONCLUSIONS:** Magnetic susceptibility contrast-enhanced MR imaging enables detection of perfusion deficits associated with acute cerebral ischemia well in advance of conventional T2-weighted spin-echo MR imaging without contrast. DyDTPA-BMA appears to delineate regions of ischemic damage better than GdDTPA-BMA.

Index terms: Contrast media, paramagnetic; Contrast media, effects; Animal studies; Brain, ischemia

AJNR 14:289–296, Mar/Apr 1993

A principal objective of magnetic resonance (MR) imaging in stroke patients is the early differentiation of normal from acutely ischemic tissue. Within minutes of onset of severe cerebral hypoperfusion, there are significant alterations in brain phosphorus metabolite ratios, an increase in lactate, and a decrease in intracellular neuronal and glial pH (1, 2). Activated sodium ion/proton

exchange causes acidification of astrocytes and later neurons, which in turn appears to precipitate a loss of intracellular volume control in brain cells. Ultimately there is net intracellular migration of sodium ions and water (3). The loss of cell volume homeostasis is exacerbated by ischemia-induced disruption of the adenosine triphosphate-dependent sodium/potassium transmembrane pump (4, 5).

Although this early “cytotoxic edema” phase (3) of ischemic brain injury is associated with a 3%–5% elevation in cerebral tissue water (4), the regions of ischemic tissue damage are not reliably shown on the T1- or T2-weighted images routinely used in clinical practice (6, 7). Signal hyperintensity is usually not observed on T2-

Received November 14, 1991; accepted and revision requested February 3, 1992; revision received April 30.

¹Neuroradiology Section, University of California, San Francisco, CA.

²Salutar, Inc, Sunnyvale, CA.

³Address reprint requests to Dr. J. Kucharczyk, Neuroradiology Section, UCSF Medical Center, San Francisco, CA 94143.

AJNR 14:289–296, Mar/Apr 1993 0195-6108/93/1402-0289

© American Society of Neuroradiology

weighted spin-echo images until 6–24 hours after ictus (6, 7), when blood-brain barrier breakdown causes extravasation of protein and accumulation of extravascular water.

The delayed sensitivity of T2-weighted spin-echo MR images to ischemic injury prompted this study of the utility of magnetic susceptibility contrast-enhanced imaging of acute cerebral ischemia. Nonionic lanthanide chelates, like dysprosium (Dy) DTPA-BMA and gadolinium (Gd) DTPA-BMA, produce contrast enhancement via loss of signal intensity (8). The magnitude of the induced hypointensity is determined by the magnetic moment of the ion and the dosage of contrast administered (8, 9). Since DyDTPA-BMA and GdDTPA-BMA remain in the cerebral intravascular compartment following intravenous injection, their influence on image signal intensity is directly related to the fractional voxel volume occupied by vessels containing the agent (9–11). A field gradient is induced between the capillary space and the surrounding perfused tissue, resulting in significant but transient signal loss in regions with normal blood flow (8–11). This “magnetic susceptibility” mechanism of MR contrast enhancement yields significantly greater changes in signal intensity than that attributable to T1 shortening (8).

The initial objective of this study was to compare the cerebrovascular transit characteristics of DyDTPA-BMA and GdDTPA-BMA in the normal cat brain using spin-echo T2-weighted MR images. Subsequently, we evaluated the efficacy of DyDTPA-BMA and GdDTPA-BMA as perfusion-sensitive agents in acute cerebral ischemia.

Methods

All studies were performed using a protocol approved by the ICSF Committee on Animal Research.

A General Electric CSI 2-Te unit equipped with Acustar S-150 self-shielded gradient coils (± 20 G/cm, 15-cm bore size) was used with a 7.5-cm inner-diameter low-pass proton imaging coil. Successive multisection T2-weighted coronal images were obtained for up to 12 hours following occlusion. T2-weighted images 2800/160/2 (TR/TE/excitations) with 3-mm sections and a 1-mm gap were obtained with a field of view of 80 mm, in which two excitations were averaged for each one of the 128 phase-encoding steps, resulting in a total acquisition time of 12 minutes.

In preliminary experiments designed to evaluate the effects of DyDTPA-BMA and GdDTPA-BMA (Omniscan, Salutar, Inc/Nycomed AS/Sanofi-Winthrop) on signal loss and subsequent signal recovery on spin-echo T2-weighted MR images of normal brain, four cats were injected with 0.10 (n = 3), 0.15 (n = 3), 0.25 (n = 2), 0.35 (n = 3), and

0.50 (n =) mmol/kg intravenously of both contrast agents over a 27- to 45-second period between phase-encoding steps 54 and 62 of a 128-phase-encoding acquisition. This injection schedule was chosen to coincide with the period of peak sensitivity of the spin-echo acquisition cycle. The magnetic susceptibility effect was quantified over 60 minutes by comparing signal intensity changes in five series of T2-weighted images using the same region of interest (ROI) in the parietal cortex. In both normal and middle cerebral artery (MCA)-occluded cats (see below), a T2-weighted unenhanced MR image was acquired immediately prior to administration of contrast agent.

In a group of 36 young adult cats, the right MCA was isolated via the transorbital approach and occluded just proximal to the origin of the lateral striate arteries with bipolar electrocautery followed by complete surgical transection. The dural incision and orbit were covered with gauze moistened with saline and absorbable gelatin sponge. Arterial blood gases and mean arterial blood pressure were monitored at regular intervals following MCA occlusion using indwelling polyethylene catheters.

DyDTPA-BMA and GdDTPA-BMA were tested at dosages of 0.10 (n = 3), 0.15 (n = 3), 0.25 (n = 8), 0.50 (n = 22), and 1.0 (n = 3) mmol/kg. Three of the 36 cats were injected with 0.25 and 0.50 mmol/kg dosages of DyDTPA-BMA. The contrast agents were infused intravenously over a 45- to 90-sec period corresponding to phase-encoding steps 32–60 of the 128-phase-encoding T2-weighted image acquisition. Injections of contrast agents were made between 30–60, 90–120, and 150–180 minutes after MCA occlusion. ROI image analyses were carried out in the

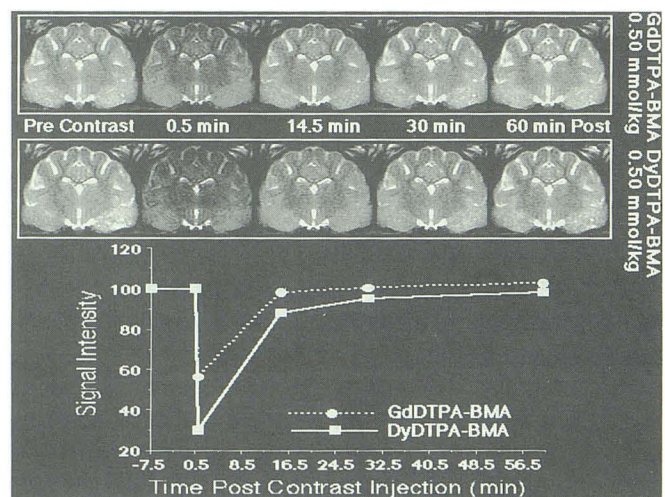


Fig. 1. On T2-weighted images acquired 45 sec after contrast administration, intravenous injection of 0.5 mmol/kg DyDTPA-BMA produced a maximum measured signal intensity loss in cortical gray matter 70% below precontrast baseline values. Signal intensity changes in white matter (internal capsule) were smaller, consistent with the higher cerebral blood volume fraction in gray matter. The same dose of GdDTPA-BMA produced a maximum signal loss 42% below baseline levels. Restoration of precontrast signal intensity was observed within 32.5 min following injection of either contrast agent.

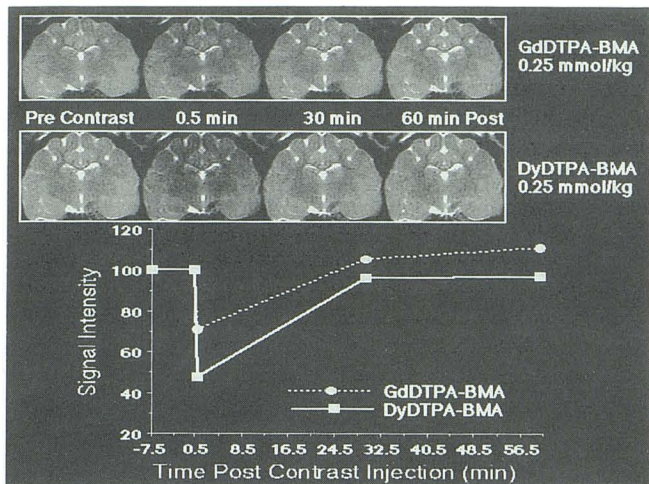


Fig. 2. Injection of 0.25 mmol/kg DyDTPA-BMA produced a maximum 57% reduction in signal intensity. The resulting T2-weighted image (acquired at 0.5 min) had excellent gray matter-white matter differentiation. In the corresponding GdDTPA-BMA-enhanced image there was a maximum 24% reduction in signal intensity. Note that the GdDTPA-BMA-enhanced images acquired at 32.5 and 56.5 min after contrast injection were hyperintense relative to the baseline precontrast image.

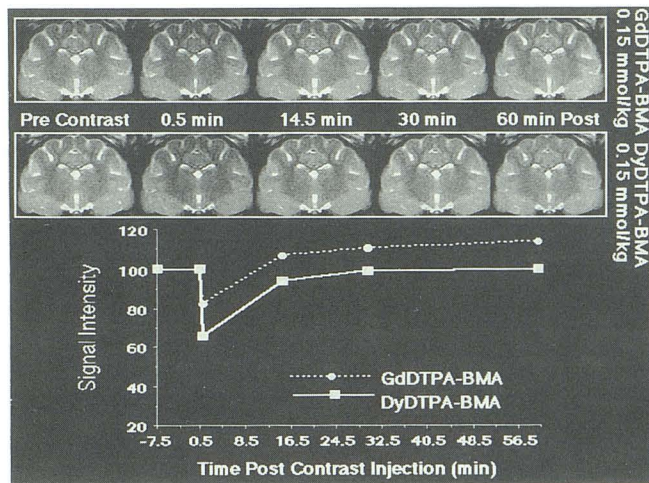


Fig. 3. At 0.15 mmol/kg, DyDTPA-BMA injection induced a peak loss of signal intensity of 35%, whereas the same dose of GdDTPA-BMA produced an 18% reduction in T2-weighted image signal intensity compared with the precontrast image. GdDTPA-BMA administration was associated with a delayed persistent hyperintensity observed in the images acquired 32.5 and 56.5 min after contrast injection.

ischemic inferior parietal gyrus, caudate/putamen, and internal capsule, and compared with the corresponding uninjured contralateral regions. A signal intensity ratio was calculated as the ROI image intensity ratio of an abnormal, ischemic region over that of the normal, contralateral side. Results are expressed as the mean percentage change \pm standard error of the mean.

At the conclusion of the MR protocol, 15 mL/kg of a 2% solution of 2,3,5-triphenyl tetrazolium chloride (TTC)

was infused transcardially. The brain was removed from the cranium after 10–20 minutes, immersed in a 2% TTC solution for another 10–20 minutes, and then stored overnight in 10% buffered formalin in a light-shielded container. Twenty-four to 36 hours later the brain was sectioned coronally at 2–3 mm and immediately examined for histologic evidence of ischemic damage (5, 12, 13) and photographed.

Results

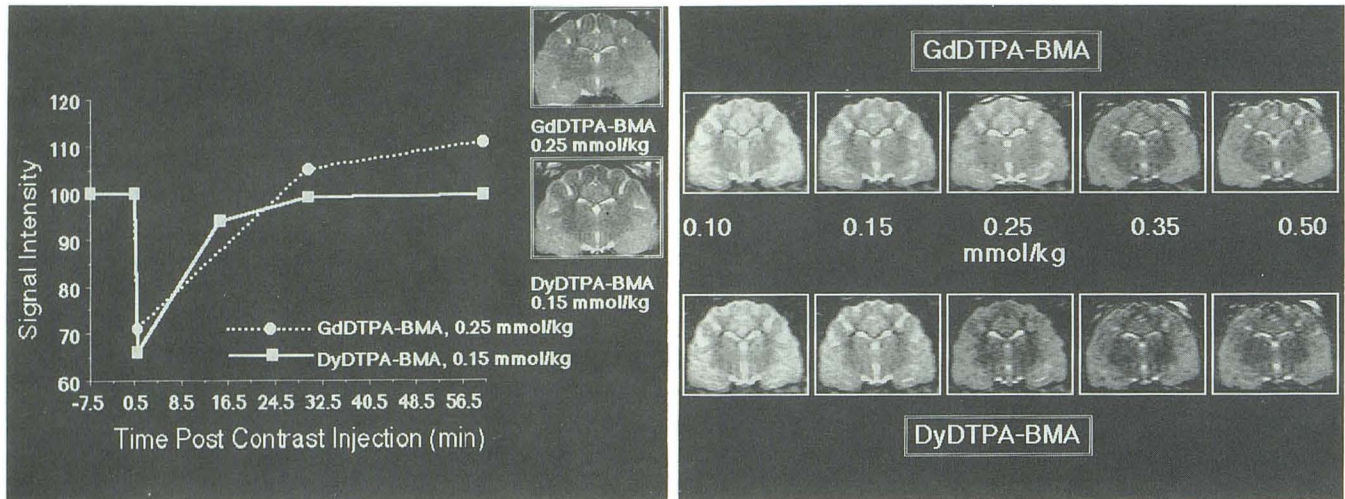
Perfusion Imaging of Normal Brain

Results comparing changes in signal intensity following injection of 0.10–0.50 mmol/kg DyDTPA-BMA and GdDTPA-BMA are shown in Figures 1–4. DyDTPA-BMA produced a 35%–70% dosage-dependent signal attenuation, compared to an 18%–45% signal reduction for equimolar dosages of GdDTPA-BMA. The magnitude of the induced hypointensity was proportional to the ratio of the squares of the magnetic moments for the two contrast agents.

DyDTPA-BMA and GdDTPA-BMA had similar washout profiles. Restoration of the baseline signal intensity followed a parallel time course, and was essentially complete within 30–35 minutes. The signal intensity following DyDTPA-BMA injections never exceeded the precontrast value. After injection of GdDTPA-BMA, however, a persistent hyperintensity was observed on the T2-weighted images acquired 32.5 and 56.5 minutes after contrast injection.

Assessment of Tissue Perfusion Deficits with DyDTPA-BMA

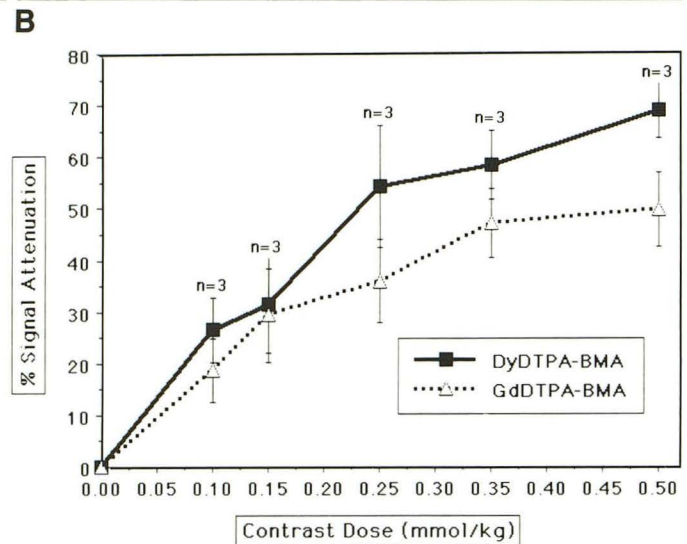
T2-weighted spin-echo images without contrast did not show any significant changes in signal intensity for 1.5–3 hours following MCA occlusion. Following DyDTPA-BMA administration, perfusion deficits caused by occlusion of the MCA were detected on T2-weighted images as regions of relative signal hyperintensity compared to the normally perfused areas in the contralateral hemisphere (Fig. 5). DyDTPA-BMA injections shortened the time of detection of perfusion deficits in 61% of the cases, usually to within 30 minutes after vascular occlusion (Table 1), which was the shortest time that images were obtained following occlusion. In 13 of 19 animals tested with 0.5 mmol/kg DyDTPA-BMA, a perfusion deficit was evident in the first postocclusion image that was completed 24 minutes after MCA occlusion. DyDTPA-BMA also improved the con-



A Fig. 4. A, The transposed dose-response curves for 0.25 mmol/kg GdDTPA-BMA and 0.15 mmol/kg DyDTPA-BMA have nearly overlapping profiles for the first 30 min after contrast injection, which illustrates the significantly greater in vivo magnetic susceptibility influence of DyDTPA-BMA. Note, however, the emergence of the T1 relaxation influence exerted by GdDTPA-BMA seen on the images acquired at 32.5 and 56.5 min after contrast injection, a feature that is not observed on the DyDTPA-BMA-enhanced images.

B, T2-weighted images enhanced with different dosages of GdDTPA-BMA and DyDTPA-BMA. Each of the pairs of images were acquired at the peak of the magnetic susceptibility effect 0.5 min after contrast administration. DyDTPA-BMA induced greater signal intensity loss than GdDTPA-BMA.

C, Dose-response curves for DyDTPA-BMA and GdDTPA-BMA attenuation of signal intensity on T2-weighted MR images of parietal cortex in normal cat brains. Values shown are means + standard error of the mean. Numbers of injections at each dosage of contrast agent are indicated.



C Dose-response curves for DyDTPA-BMA and GdDTPA-BMA attenuation of signal intensity on T2-weighted MR images of parietal cortex in normal cat brains. Values shown are means + standard error of the mean. Numbers of injections at each dosage of contrast agent are indicated.

spicuity of small developing infarcts that were not visible or were ambiguous on T2-weighted images without contrast (Fig. 6) (Table 2).

The maximum anatomic extent of perfusion deficiency was observed within the first 3 hours following vascular occlusion (Fig. 7). During this period, T2-weighted images demonstrated increasing signal intensity (edema) throughout the MCA territory. The onset of T2-weighted hyperintensity was typically preceded by evidence of mass effect (effacement of the cortical sulci). The distribution of increased signal intensity on pre-contrast images was correlated anatomically with regions of perfusion deficiency demonstrated with DyDTPA-BMA-enhanced MR imaging. In subsequent TTC-stained coronal sections (Fig. 8), these areas were found to exhibit characteristics typical of ischemic tissue injury, such as pallor of

staining, coagulation necrosis, and glial proliferation (12-14).

Efficacy of DyDTPA-BMA vs GdDTPA-BMA

Ischemic lesion conspicuity was optimally depicted at dosages of 0.50 mmol/kg of GdDTPA-BMA and 0.25 mmol/kg of DyDTPA-BMA. When tested at equimolar dosages during the first 3 hours following MCA occlusion, DyDTPA-BMA consistently enabled better visualization of perfusion deficits than GdDTPA-BMA did. Perfusion deficits in areas of partial ischemia were also seen more clearly on DyDTPA-BMA-enhanced T2-weighted images than on corresponding GdDTPA-BMA-enhanced images (Fig. 6). In ischemic lesions less than 4-6 hours old, the wash-out (restoration of precontrast signal intensity) of

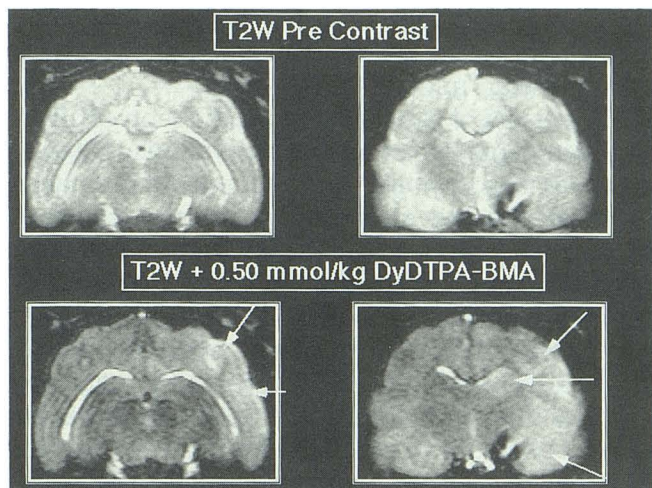


Fig. 5. T2-weighted 2800/160 (TR/TE) spin-echo images at two coronal levels of the same cat brain before (*top panels*) and after (*bottom panels*) intravenous administration of 0.5 mmol/kg DyDTPA-BMA. The contrast-enhanced images acquired 60 min after unilateral MCA occlusion show a clear perfusion deficit (hyperintensity) (*arrows*) in the ipsilateral MCA vascular territory. By comparison, ischemic tissue injury is poorly defined on the precontrast T2-weighted images that were collected 12 min earlier.

TABLE 1: Effect of DyDTPA-BMA administration on the time of detection of cerebral ischemic damage

Dose DyDTPA-BMA (mmol/kg)	No. Cats Tested	Detection of Ischemic Lesion Relative to Onset of T2 Signal Hyperintensity		
		Earlier	Same Time	Later
		0.10	3	0
0.15	3	2	1	0
0.25	8	6	2	0
0.50	19	13	6	0
1.0	3	3	0	0

Note.—Contrast agent was injected a maximum of three times in any single animal, between 30–60, 90–120, and 150–180 minutes after MCA occlusion, and was preceded by a control unenhanced image.

both contrast agents was effectively complete within 30 minutes following injection.

Discussion

Proton MR imaging is sensitive to changes in brain water concentration and proton mobility that occur with cerebral ischemia. Disruption of oxygen transport to cerebral tissues rapidly causes an isoosmotic shift of extracellular fluid into neurons and glial cells (4, 5). Cellular (cytotoxic) edema may actually represent a translocation of water between the extracellular and intracellular compartments rather than a significant de novo increase in brain water (3). It has

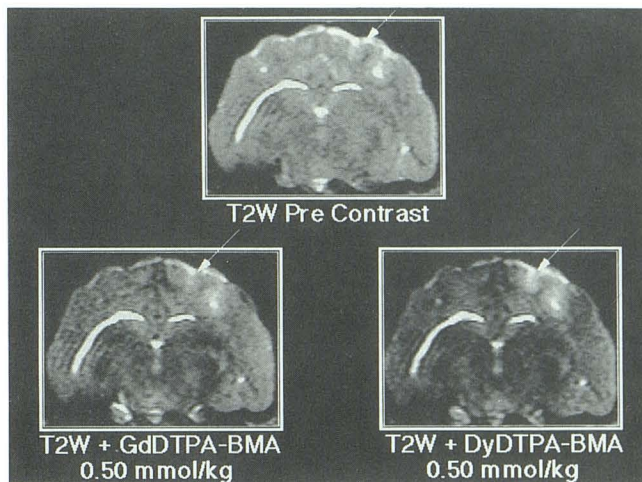


Fig. 6. Contrast injection significantly improved the visibility of a small cortical ischemic lesion. Lesion conspicuity was greater after DyDTPA-BMA (0.50 mmol/kg) injection than an equimolar dosage of GdDTPA-BMA (*arrows*).

TABLE 2: Effect of DyDTPA-BMA administration on ischemic lesion conspicuity

Dose DyDTPA-BMA (mmol/kg)	No. Cats Tested	Lesion Conspicuity		
		Increased	Same	Decreased
0.10	3	0	3	0
0.15	3	1	2	0
0.25	8	5	3	0
0.50	19	17	2	0
1.00	3	3	0	0

Note.—Lesion conspicuity was evaluated by comparing the signal intensity ratio of ischemic tissue with the corresponding region of the contralateral hemisphere in contrast-enhanced and unenhanced T2-weighted images.

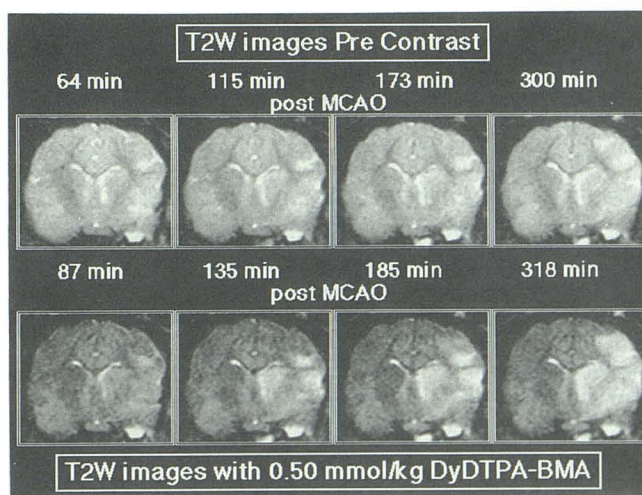


Fig. 7. Evolution of signal intensity changes on DyDTPA-BMA-enhanced (0.5 mmol/kg) and precontrast T2-weighted images of cat brain for 6 hours following unilateral MCA occlusion.

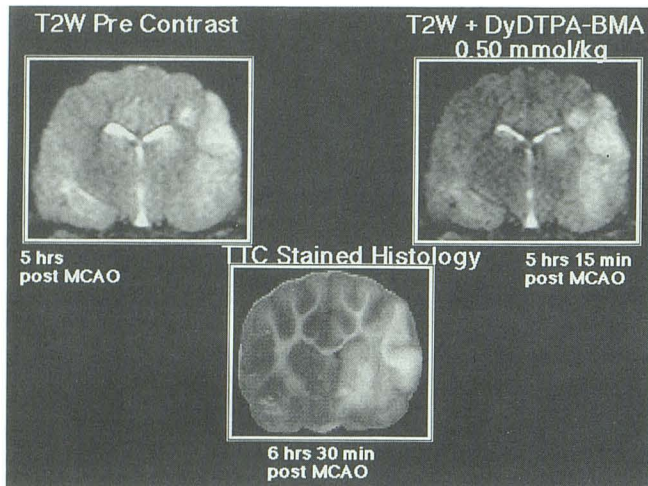


Fig. 8. Five hours after MCA occlusion, tissue edema can be seen throughout the MCA vascular territory on the precontrast T2-weighted image. The region of perfusion deficit demarcated in the image enhanced with 0.5 mmol/kg DyDTPA-BMA corresponds closely to the postmortem histologic section.

been suggested that the 3%-4% increase in total regional water content may, however, be sufficient to account for the visibility of ischemic lesions within 10-45 minutes of arterial occlusion on diffusion-weighted MR images (15-17). Recent studies in stroke patients have shown that vascular abnormalities and morphologic changes may be observed on T1-weighted images as early as 2 hours after ictus without concomitant signal changes on T1- or T2-weighted images (18).

Breakdown of the blood-brain barrier results in seepage of protein-rich water into the extracellular compartment of the ischemic tissues. The onset of vasogenic edema increases tissue pressure and further reduces tissue perfusion. At this stage of ischemia 3 hours to 2 days after vascular occlusion, the MR image is hyperintense on T2-weighting, and adjacent sulci are often effaced due to mass effect (6, 7, 13).

Paramagnetic T1-shortening contrast agents, such as gadopentatate dimeglumine (Gd-DTPA), until recently had limited utility in the MR assessment of acute cerebral ischemia because signal intensity changes appear to be dependent on blood-brain barrier breakdown (19, 20), which is a relatively delayed ischemic event (4-7). In recent studies, stroke patients who underwent Gd-DTPA-enhanced imaging were found to have enhancement of vessels supplying the infarct within 24 hours of ictus, which preceded the development of classic parenchymal enhancement 7-14 days after infarction (21-25). The mechanisms of arterial or parenchymal enhance-

ment observed following Gd-DTPA administration, or its exact pathophysiologic significance, are at present uncertain.

The results of the present investigation confirm and extend our preliminary observations (10) that magnetic susceptibility contrast agents provide a sensitive imaging method for assessing changes in blood volume and tissue perfusion associated with ischemia. In the brain, nonionic lanthanide chelates like DyDTPA-BMA and GdDTPA-BMA are confined to the intravascular space. The field gradient induced at the interface of the capillary space and surrounding tissue results in transient alterations in signal intensity during intravascular passage of contrast through the normally perfused capillary bed (8, 9, 11). The magnitude and duration of the signal attenuation depend on the local dynamic concentration of contrast, the magnetic moment of the metal ion, local vascular geometry, and the rate of delivery of the contrast (11).

The present study demonstrates that in the normal cat brain, regional variations in signal intensity following magnetic susceptibility contrast administration provide excellent anatomic definition of gray and white matter. The magnitude of the signal loss over a wide range of dosages was related to the magnetic moment of the individual contrast agent. DyDTPA-BMA, which has a magnetic moment of 10.6 Bohr magnetons (BM), produced an approximately twofold greater loss of signal intensity than did GdDTPA-BMA, which has a magnetic moment of 7.9 BM (26). This result is in close agreement with the expected difference in signal intensity, which is $(Dy/Gd)^2$ or 1.80 times greater for Dy than Gd (8, 9, 26).

The results of this study indicate further that magnetic susceptibility contrast enhancement facilitates the early differentiation of ischemic from normally perfused brain tissue. DyDTPA-BMA administration advanced the time of detection of cerebral ischemic insults to less than 30 minutes after occlusion, which was the earliest time at which postocclusion-enhanced images were obtained. Unenhanced T2-weighted spin-echo images, by comparison, did not demonstrate hyperintensity until 1-3 hours later. Small infarcts that were missed on T2-weighted images without contrast could be clearly seen after administration of DyDTPA-BMA. Perfusion deficits in areas of partial ischemia were also generally better visualized on DyDTPA-BMA-enhanced T2-

weighted images than on corresponding Gd-DTPA-BMA-enhanced images.

In ischemic lesions less than 4-6 hours old, the restoration of precontrast signal intensity was usually achieved within 30 minutes after administration of either agent. However, GdDTPA-BMA also consistently produced a delayed T1-shortening related hyperintensity on T2-weighted images acquired 30-60 minutes after injection. This aspect of GdDTPA-BMA enhancement may be ascribable to an erosion of the magnetic susceptibility influence of the contrast agent before its more persistent T1-shortening effect. We postulate that this may be due to a small residual intravascular concentration of GdDTPA-BMA. In any case, the delayed and persistent T1-shortening effect associated with this contrast agent complicates the interpretation of images in which multiple injections of GdDTPA-BMA enhancement was the absence of concurrent T1-shortening effects. This observation suggests that injections of DyDTPA-BMA can be repeated without compromising diagnostic efficacy.

Cerebral blood flow was not directly measured in the present study, but the contrast-enhanced images showed considerable regional heterogeneity in perfusion throughout the ischemic MCA territory. Postcontrast signal hyperintensity was observed earlier in the basal ganglia than in the neocortex. This finding is in agreement with previous studies (10) in which nonanastomosing end-arterial tissues, such as the caudate and putamen, were found to be most susceptible to ischemia. By comparison, in collaterally perfused areas such as neocortex, tissue injury may be mitigated somewhat by continued blood flow in the partially ischemic watershed regions (14). These data suggest that magnetic susceptibility-enhanced MR imaging may be useful in evaluating the topography of regional alterations in focal vascular occlusion, and thereby in differentiating permanently damaged tissue in the ischemic core from the reversibly injured ischemic penumbra.

Another important feature of magnetic susceptibility imaging is that it can be employed in conjunction with "ultrafast" MR techniques, like echo-planar imaging, to yield "real-time" images of the cerebral microcirculation (8, 11, 16, 27). By resolving the passage of intravascular contrast material through the capillary bed, kinetic modeling of regional blood flow and volume can be achieved (8, 11, 28, 29). In recent preliminary studies using contrast-enhanced gradient-recalled echo-planar MR imaging (16, 17), DyDTPA-BMA

administration significantly decreased the time for detection of ischemic brain injury and clearly defined the regions of perfusion deficits.

References

- Gyulai I, Schnall M, McLaughlin AC, et al. Simultaneous P-31 and H-1 nuclear magnetic resonance studies of hypoxia and ischemia in the cat brain. *J Cereb Blood Flow Metab* 1987;7:543-548
- Kucharczyk J, Moseley M, Kurhanewicz J, et al. MRS of ischemic/hypoxic brain disease. *Invest Radiol* 1989;24:951-954
- Siesjo B. Cerebral circulation and metabolism. *J Neurosurg* 1984;60:883-908
- Gotoh O, Asano T, Koide T, et al. Ischemic brain edema following occlusion of the middle cerebral artery in the rat: the time courses of brain water, sodium and potassium contents and blood-brain permeability to I-125 albumin. *Stroke* 1987;16:101-107
- Hossman RA, Shrier FJ. Experimental brain infarcts in cats. I. Pathophysiological observations. *Stroke* 1980;11:622-627
- Baker L, Kucharczyk J, Sevick R, et al. Recent advances in MR imaging/spectroscopy of cerebral ischemia. *AJR* 1991;156:1133-1143
- Brant-Zawadski M, Weinstein PR, Bartkowski H, et al. MR imaging and spectroscopy in clinical and experimental cerebral ischemia: a review. *AJNR* 1987;8:39-48
- Villringer A, Rosen BR, Belliveau JW, et al. Dynamic imaging with lanthanide chelates in normal brain: contrast due to magnetic susceptibility effects. *Magn Reson Med* 1988;6:164-174
- Cacheris W, Rocklage SM, Quay S, et al. Magnetic susceptibility imaging with a nonionic contrast agent. *Radiology* 1988;169:383
- Moseley M, Kucharczyk J, Mintorovitch J, et al. Diffusion-weighted MR imaging of acute stroke: correlation with T2-weighted and magnetic susceptibility-enhanced MR imaging in cats. *AJNR* 1990;11:423-429
- Rosen BR, Belliveau JW, Chien D. Perfusion imaging by nuclear magnetic resonance. *Magn Reson Q* 1989;5:263-281
- Bose B, Osterholm JL, Berry R. A reproducible experimental model of focal cerebral ischemia in the cat. *Brain Res* 1984;311:385-391
- Kucharczyk J, Chew W, Derugin N, et al. Nicardipine reduces ischemic brain injury. *Stroke* 1989;20:268-274
- Little JR, Sundt TM, Kerr FWL. Neuronal alterations in developing cortical infarction: an experimental study in monkeys. *J Neurosurg* 1974;39:186-198
- Moseley M, Cohen Y, Mintorovitch J, et al. Early detection of regional cerebral ischemia in cats: comparison of diffusion- and T2-weighted MRI and spectroscopy. *Magn Reson Med* 1990;14:330-346
- Moseley M, Sevick R, Wendland M, et al. Ultrafast magnetic resonance imaging: diffusion and perfusion. *Can Assoc Radiol J* 1991;42:31-38
- Moseley M, Wendland M, Kucharczyk J. Magnetic resonance imaging of diffusion and perfusion. *Top Magn Reson Imaging* 1991;3:50-68
- Yuh WTC, Crain MR, Loes DJ, et al. MR imaging of cerebral ischemia: findings in the first 24 hours. *AJNR* 1991;12:621-629
- McNamara MT, Brant-Zawadski M, Berry I, et al. Acute experimental cerebral ischemia: MR enhancement using GdDTPA. *Radiology* 1986;158:701-705
- Moseley I. Imaging in cerebrovascular disease and head injury. *Curr Opin Neurol* 1989;2:864-869
- Crain MR, Yuh WTC, Greene GM, et al. Cerebral ischemia: evaluation with contrast-enhanced MR imaging. *AJNR* 1991;12:631-639
- Virapongse C, Mancuso A, Quisling R. Human brain infarcts: Gd-DTPA-enhanced MR imaging. *Radiology* 1986;161:785-794

23. Imakita S, Nishimura T, Naito H, et al. Magnetic resonance imaging of human cerebral infarction: enhancement with Gd-DTPA. *Neuroradiology* 1987;29:422-429
24. Imakita S, Nishimura T, Yamada N, et al. Magnetic resonance imaging of cerebral infarction: time course of GdDTPA enhancement and CT comparison. *Neuroradiology* 1988;30:372-378
25. Elster AD, Moody DM. Early cerebral infarction: gadopentetate dimeglumine enhancement. *Radiology* 1990;177:627-632
26. Drago RS. *Physical methods in chemistry*. Philadelphia: Saunders, 1977:424
27. Edelman RR, Mattle HP, Atkinson DJ. Cerebral blood flow: assessment with dynamic contrast-enhanced T2*-weighted MR imaging at 1.5 T. *Radiology* 1990;176:211-220
28. Rosen BR, Belliveau JW, Vera JM, et al. Perfusion imaging with NMR contrast agents. *Magn Reson Med* 1990;14:249-265
29. Belliveau JW, Rosen BR, Kandor HL, et al. Functional cerebral imaging by susceptibility contrast NMR. *Magn Reson Med* 1990;14:538-546