Are your MRI contrast agents cost-effective?
Learn more about generic Gadolinium-Based Contrast Agents.
FRESENIUS KABI
caring for life

AJNR

Hemangiomas and vascular malformations of the head and neck: MR characterization.

L L Baker, W P Dillon, G B Hieshima, C F Dowd and I J Frieden

AJNR Am J Neuroradiol 1993, 14 (2) 307-314
http://www.ajnr.org/content/14/2/307

This information is current as of April 19, 2024.

Hemangiomas and Vascular Malformations of the Head and Neck: MR Characterization

Lori L. Baker,[1,2] William P. Dillon,[1] Grant B. Hieshima,[1] Christopher F. Dowd,[1] and Ilona J. Frieden[3]

PURPOSE: To characterize the MR appearance of the common hemangioma of infancy as well as low- and high-flow vascular malformations of the head and neck. **PATIENTS AND METHODS:** Twenty patients with vascular lesions of the head and neck proved either by pathology, angiography, and/or unequivocal clinical diagnosis were included. Vascular lesions included 15 low-flow lesions (four hemangiomas, 10 venous malformations, one lymphatic malformation), and five high-flow lesions (three arteriovenous malformations (AVMs) and two invasive combined malformations). All patients had MR studies (generally 1.5 T using routine T1- and T2-weighted spin-echo sequences). Nine had postgadolinium, gradient recalled-echo, CT, and/or angiographic studies. **FINDINGS:** Deep hemangiomas and venous malformations demonstrate intermediate signal in T1-weighted images, heterogeneous high signal on T2-weighted images, and prominent enhancement. Involuting hemangiomas show focal areas of high signal intensity on T1-weighted images due to fatty replacement. Venous malformations may demonstrate venous lakes seen as homogeneous regions of high signal intensity on T2-weighted images and phleboliths seen as low signal foci. The one patient with lymphatic malformation showed a large multicystic submandibular mass with large hemorrhage-fluid levels. Features of high-flow lesions (AVMs) include serpiginous signal voids, absence of a dominant mass, and intraosseous extension with decreased marrow signal on T1-weighted images. Invasive combined vascular malformations showed serpiginous flow voids and infiltrative solid masses. Low-flow lesions (hemangiomas, venous, and lymphatic malformations) demonstrate distinct MR findings allowing their differentiation from high-flow lesions (AVMs). Deep hemangiomas and venous malformations appear as solid masses and may look identical. Venous lakes and phleboliths are features of venous malformations which, when present, may help in diagnosis. Combined vascular malformations share features of both low- and high-flow malformations. **CONCLUSION:** MR is useful in delineating the extent of disease and differentiating low- and high-flow vascular lesions.

Index terms: Head, neoplasms; Neck, neoplasms; Arteriovenous malformations, magnetic resonance; Hemangioma

AJNR 14:307–314, Mar/Apr 1993

Soft-tissue vascular lesions form a distinct histopathologic group of lesions within the head and neck that presents a diagnostic challenge both clinically and pathologically. Dilemmas in diagnosis and management have been due in part to a variety of confounding classification systems arising from an unfamiliarity with the pathophysiology and natural history of these complex lesions. As a result, extensive overlapping clinical and histologic terminologies have evolved making appropriate diagnostic and therapeutic decisions difficult.

A variety of classification schemes for vascular lesions have been proposed based on descriptive, histologic, embryologic, and angiographic features (1–3). More recently, Mulliken and Glowacki (4) proposed a comprehensive classification system for vasoformative lesions in children emphasizing their clinical behavior and endothelial cell

Received January 3, 1992; accepted contingent on revision April 9; revision received April 28.

[1] Department of Radiology, Neuroradiology Section, University of California, San Francisco, 505 Parnassus, San Francisco, CA 94143-0628.

[2] Address reprint requests to Lori L. Baker, MD, Staff Radiologist, Mercy Hospital and Medical Center and Radiology Medical Group, Inc., 4077 Fifth Avenue, San Diego, CA 92103-2180.

[3] Department of Dermatology, University of California, San Francisco, 505 Parnassus, San Francisco, CA 94143-0628

AJNR 14:307–314, Mar/Apr 1993 0195-6108/93/1402-0307
© American Society of Neuroradiology

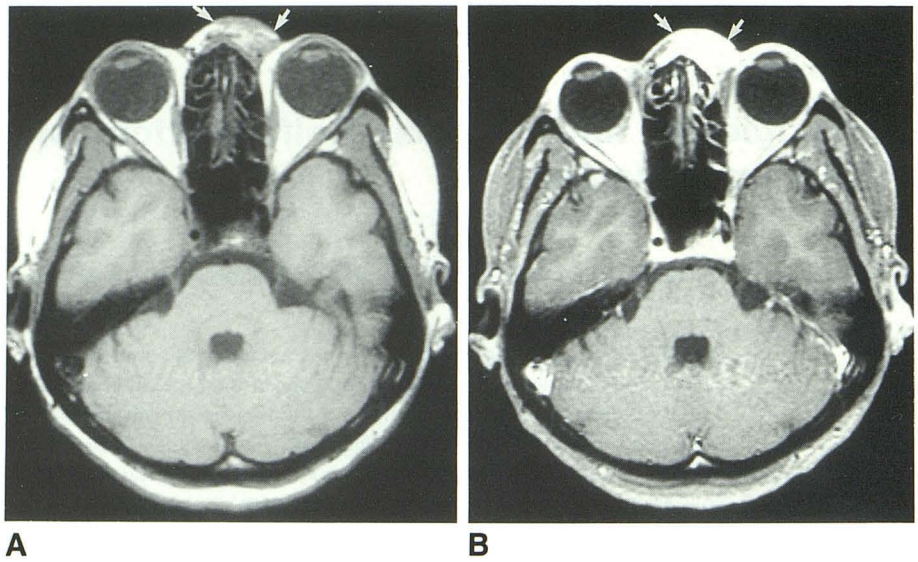

Fig. 1. Ten-year-old girl presenting in early infancy with a small superficial hemangioma which has started to involute.

A, T1-weighted image (650/11) demonstrates a small superficial hemangioma predominantly involving the left aspect of the nasal bridge (*arrows*). Focal hyperintense regions represent focal fatty change within the partially involuted hemangioma.

B, T1-weighted image postgadolinium (500/11) shows prominent, homogeneous enhancement of the hemangioma.

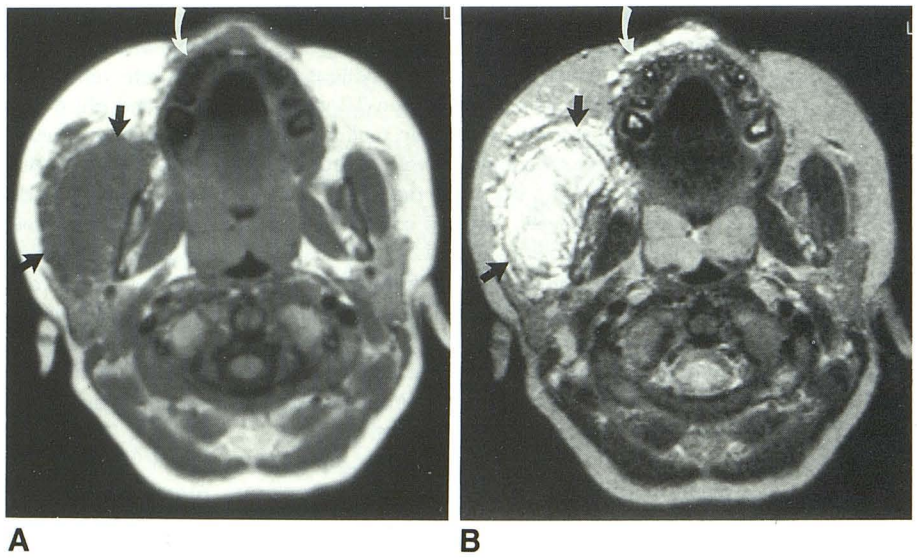

Fig. 2. Four-year-old girl with a rapidly growing right masseter muscle mass that was initially clinically apparent in early infancy.

A, T1-weighted image (685/20) and *B*, T2-weighted image (1809/80). Deep hemangioma involving the right masseter muscle seen as a large solid mass of intermediate signal intensity on T1-weighted images and high signal intensity on T2-weighted images (*black arrows*). Note multiple small satellite lesions (*curved white arrows*) within subcutaneous tissues of right face and anterior to maxillary alveolus.

characteristics. They describe two categories of vascular anomalies of the head and neck: hemangiomas and vascular malformations. Hemangioma is a term limited to the very common vascular lesion of infancy. These cellular tumors exhibit increased mitotic activity resulting from endothelial cell proliferation. Hemangiomas typically appear in early infancy, grow rapidly, and undergo fatty replacement and involution by adolescence (5). Vascular malformations, on the other hand, are lesions resulting from abnormal blood or lymphatic vessel morphogenesis. These lesions are classified by the predominant type of vessel involved and include capillary, venous, lymphatic, and arteriovenous malformations (AVMs). Vascular malformation are present at birth, but may not become clinically apparent until late infancy or childhood. Their growth is commensurate with that of the patient and they do not involute. Although vascular malformations may be comprised of a single type of vascular anomaly, complex lesions with a more invasive natural history also occur that contain several types of anomalous vessels, the so-called combined vascular malformation (6). Some combined vascular malformations may be highly invasive and refractory to a variety of therapeutic interventions. Another way of classifying these lesions is by their vascular flow characteristics (6). Hemangioma as well as capillary, venous, and lymphatic malformations are low-flow lesions. AVMs are high-flow lesions. Combined malformations may be either predominantly low- or high-flow lesions.

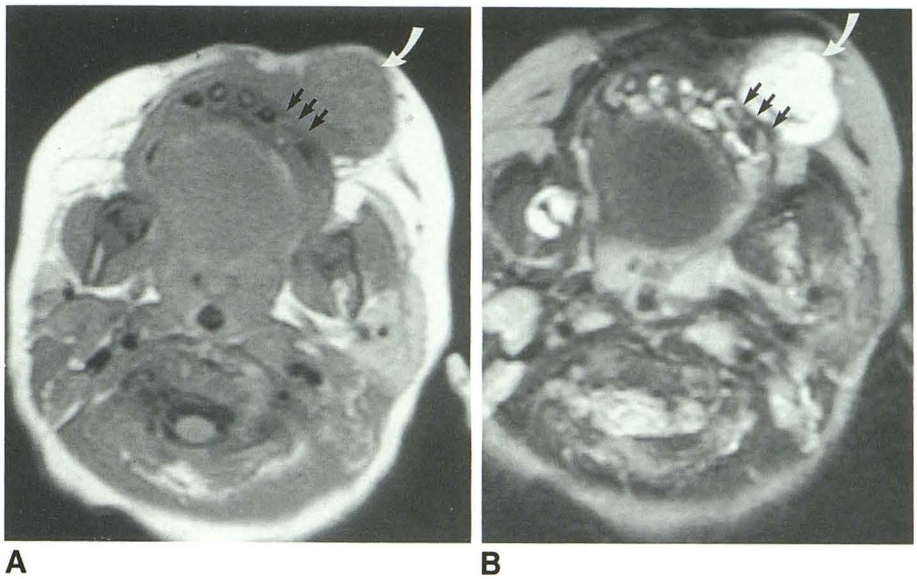

Fig. 3. Ten-month-old girl presenting with a left facial mass at birth that has grown in proportion to her overall growth.

A, T1-weighted image (600/12) and *B*, T2-weighted image (2300/85). Venous malformation of the left face abutting the left aspect of the maxillary alveolus, seen as a mildly heterogeneous mass of intermediate signal intensity on T1-weighted images and high signal intensity on T2-weighted images (*curved white arrows*). Note bony deformity of the left aspect of the maxillary alveolus (*black arrows*).

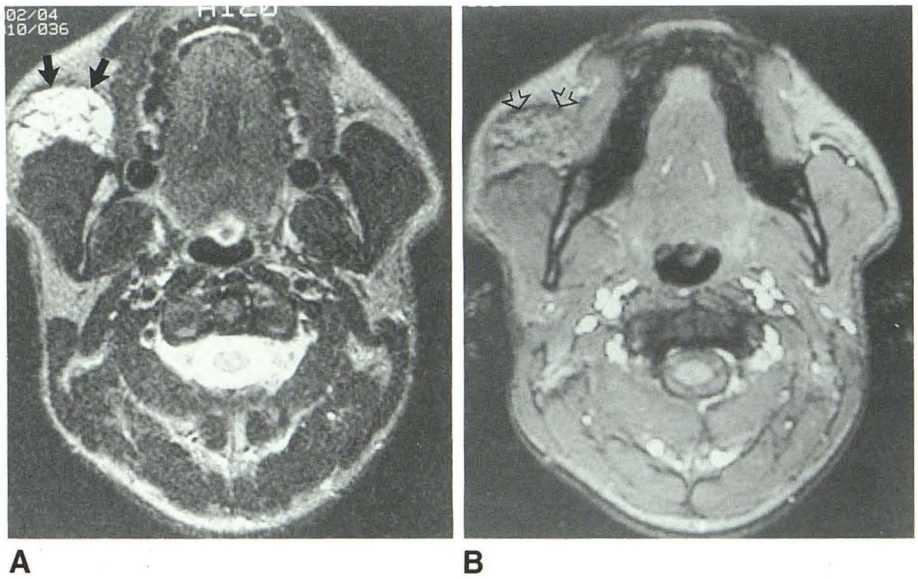

Fig. 4. Thirty-two-year-old man with a slow-growing right facial mass, present at birth.

A, T2-weighted image (2800/80) showing a venous malformation located immediately anterior to the right masseter muscle as a discrete mildly heterogeneous high signal intensity mass (*arrows*).

B, Gradient recalled-echo scan (50/13/20) demonstrating absence of flow-related enhancement within the vascular malformation (*open arrows*).

Distinction between the various low- and high-flow vascular lesions is critical to determining appropriate patient management. Although low- and high-flow lesions are often distinguished by history and physical examination, imaging studies play an important diagnostic role in more difficult cases. While the angiographic and computed tomography (CT) findings of hemangiomas vascular malformations have been previously discussed (7–10), only limited data are available with regard to the capabilities of magnetic resonance (MR) in diagnosis and treatment of these lesions (11–13) (Bilaniuk LT et al, paper presented at the 76th Annual RSNA Meeting, Chicago, IL, 1990). We designed the following study in an effort to clarify the diagnostic contributions of MR imaging in characterizing and differentiating low- and high-flow vascular lesions. A review of the clinicopathologic features and of various therapeutic options available for these lesions is also presented.

Methods

Twenty patients (nine males, 11 females, aged 3 months to 74 years), with vascular malformations of the head and neck proven either by pathology (five patients), angiography (nine patients), and/or unequivocal clinical diagnosis (15 patients) comprised the study group. Clinical diagnosis followed the criteria proposed in the Mulliken and Glowacki classification system (4). Hemangioma was a term reserved for the common endothelial tumor appearing in early infancy that underwent a period of growth followed by involution. Vascular malformations (capillary, venous, lym-

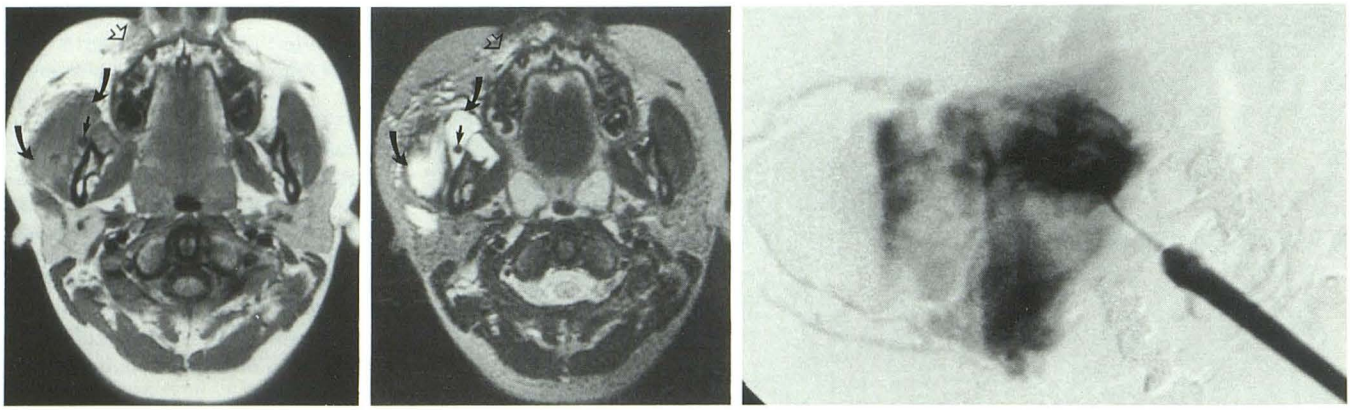

A B C

Fig. 5. Twenty-one-year-old man presenting with a slow-growing right masseter muscle mass, clinically apparent at birth.

A, T1-weighted image (600/20) and *B*, T2-weighted image (3020/80). Venous malformation of the right masticator space. Venous lakes best seen on T2-weighted images as discrete regions of homogeneous high signal intensity (*curved arrows*); corresponding intermediate signal intensity is noted on T1-weighted images. Small foci of low signal intensity within the lakes represent phleboliths (*straight arrows*). Note small satellite lesions within subcutaneous tissues of the right face and anterior to the maxillary alveolus (*open arrows*).

C, Direct puncture and opacification of venous lakes within the venous malformation performed with subsequent alcohol sclerotherapy.

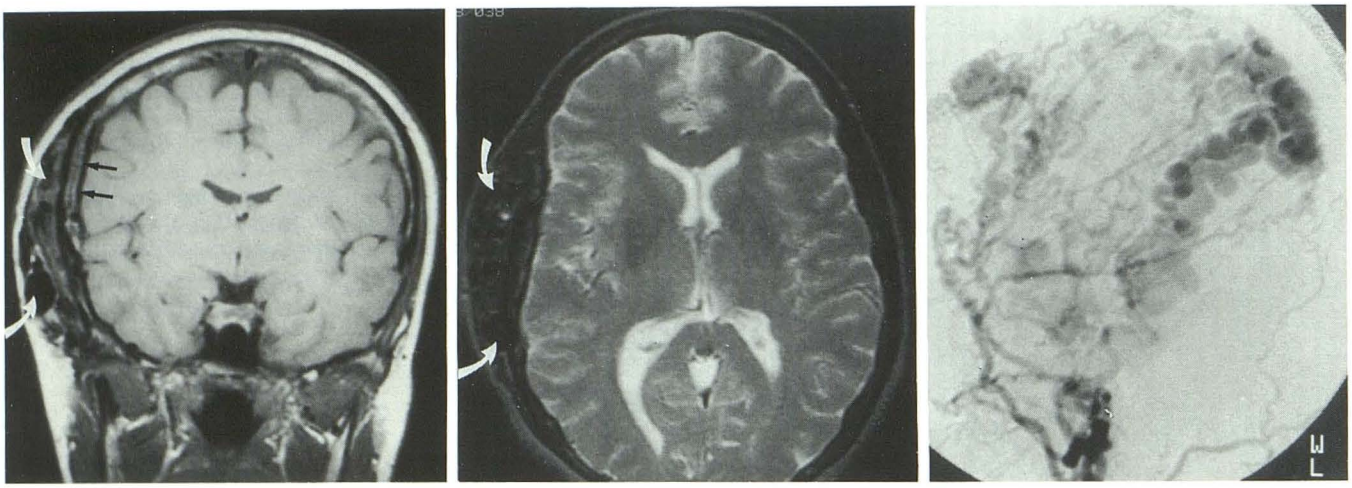

A B C

Fig. 6. Fifty-three-year-old woman presenting with progressively worsening headaches and mild right scalp soft-tissue swelling. No known trauma.

A, T1-weighted image (800/20) and *B*, T2-weighted image (3000/80). Large AVM with prominent serpiginous signal voids involving the right temporalis muscle and subcutaneous tissues of the right scalp on T1-weighted and T2-weighted images (*curved white arrows*). Decreased marrow signal intensity within calvarial bone marrow adjacent to AVM suggesting bony involvement (*black arrows*).

C, Corresponding right external carotid angiogram demonstrating an extensive right scalp arteriovenous malformation.

phatic, arteriovenous) included those lesions present at birth or detected in early infancy that demonstrated growth commensurate with that of the patient and did not involute. Our patient series included four with hemangiomas (2 superficial, two deep), 10 venous malformations, one lymphangioma, three AVMs, and two invasive combined vascular malformations. All patients had MR studies, the majority of which were performed on a 1.5-T system using routine T1-weighted (600–800/20–30/2–4) (TR/TE excitations) and T2-weighted (2000–2400/60–80/1) spin-echo (SE) sequences in at least two orthogonal planes. We also accepted studies of comparable quality from outside institutions. In addition, seven of the patients also had post-gadolinium T1-weighted and/or gradient recalled-echo scans (50–100/7–15/20–50) (TR/TE/flip angle), and nine had conventional angiographic studies.

The MR features evaluated included the site and extent of involvement, number of lesions, margins and contour of the masses, T1 and T2 signal characteristics, enhancement patterns, number and size of associated abnormal vessels, presence of phleboliths, and bony involvement. Clinical histories were reviewed in all patients, with particular atten-

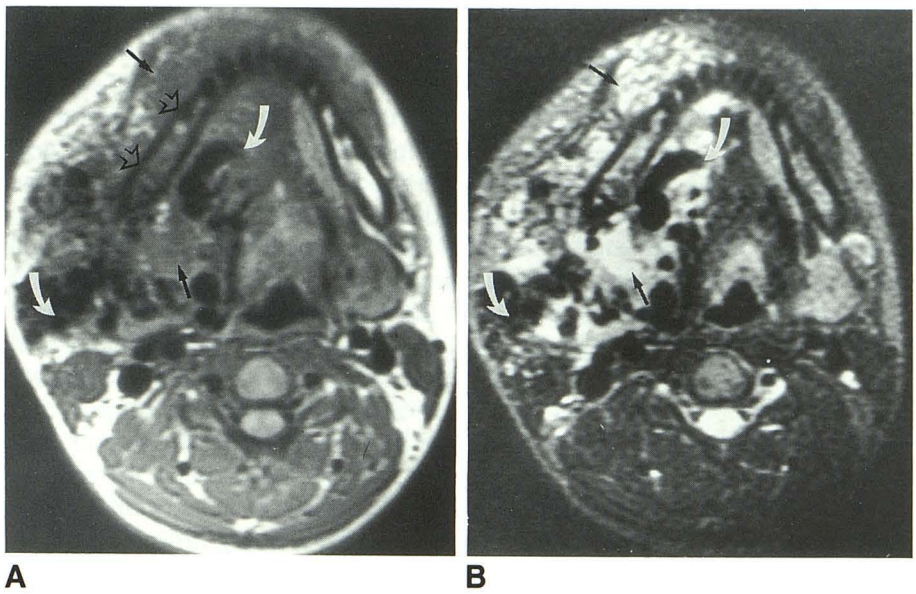

Fig. 7. Twenty-one-year-old woman with a slow-growing right facial mass that became clinically apparent 11 years ago.

A, T1-weighted image (700/20) and *B*, T2-weighted image (2000/70). Large invasive combined malformation demonstrating features of both venous malformations and AVMs. Note multiple large vessels seen as serpiginous signal voids located both superficial and deep to the right body of the mandible (*curved white arrows*). A large, infiltrated solid mass component is also seen demonstrating intermediate signal intensity on T1-weighted images and high signal intensity on T2-weighted images (*solid black arrows*). Decreased marrow signal intensity within the right mandibular body is observed suggesting involvement at this level (*open arrows*).

tion to patient age at the time of lesion appearance and rate of growth. When possible, patients were also physically examined and the compressibility and warmth of the lesion as well as the color, extent of cutaneous involvement, and presence or absence of a thrill or bruit were noted.

Results

Low-Flow Vascular Lesions

Patients with hemangioma had either superficial (two patients) or deep (two patients) lesions presenting in early infancy. These soft-tissue masses differed in size, were compressible, and showed varying degrees of overlying skin discoloration. Superficial cutaneous hemangiomas were intermediate in signal on T1-weighted images and increased in signal on T2-weighted images. Focal areas of high signal intensity on T1-weighted images that decreased in signal on T2-weighted images corresponded to fatty replacement in a partially involuted hemangiomas (Fig. 1). Masses were either heterogeneous or homogeneous without evidence of dilated vascular channels or signal voids. Prominent enhancement was noted on postgadolinium T1-weighted images (Fig. 1). Deep hemangiomas were seen as solid masses involving the deep cutaneous layers and/or musculature. They showed intermediate signal on T1-weighted images and heterogeneous high signal on T2-weighted images (Fig. 2). Numerous small soft-tissue "satellite" lesions were seen immediately adjacent to and/or at some distance from the dominant mass.

Venous malformations were detected at birth or shortly thereafter, manifested by skin discoloration and/or soft-tissue mass. Serial clinical examinations showed no evidence of mass regression or involution. These malformations were predominantly solid masses showing intermediate signal on T1-weighted and heterogeneous high signal on T2-weighted images (Fig. 3). In general, linear or serpiginous signal voids on T1-weighted and T2-weighted images were not a feature of these malformations; however, one patient demonstrated small linear signal voids throughout a predominantly solid mass, likely representing dilated veins. Three venous malformations were associated with adjacent bony remodeling or deformity; however, normal marrow signal intensity was preserved suggesting an absence of intraosseous invasion (Fig. 3). Prominent enhancement was seen on postgadolinium T1-weighted images and was generally homogeneous or mildly heterogeneous. The angiographic findings ranged from avascular masses to those showing varying degrees of tissue staining, often in a lobular configuration; minimal arteriovenous shunting, if any, was present. Gradient recalled-echo scans generally showed absence of flow-related enhancement (Fig. 4). Venous malformations tended to cross fascial planes within the deep spaces of the head and neck. Three patients had prominent dilated veins ("venous lakes") seen as well-defined regions of homogeneous high signal intensity on T2-weighted images (Fig. 5). MR depiction of the venous lakes in two patients facilitated direct

puncture localization for purposes of subsequent sclerotherapy with ethanol (Fig. 5). Phleboliths were depicted as foci of low signal on T1-weighted and T2-weighted images within venous lakes in three patients.

The one patient in our series with a lymphatic malformation presented in early infancy with a rapidly enlarging submandibular mass. MR images demonstrated a large, multicystic submandibular mass with high hemorrhage-fluid levels that extended into the nasopharynx.

High-Flow Vascular Lesions

AVMs showed a distinct constellation of findings compared with the low-flow lesions. Minimal soft-tissue swelling with a palpable thrill and underlying bruit was observed in all three patients. AVMs demonstrated serpiginous signal voids on T1-weighted and T2-weighted images, corresponding to prominent arteriovenous shunts as depicted on angiographic studies (Fig. 6). Mass effect, if any, was minimal and probably secondary to venous congestion. Intraosseous involvement was a feature in two AVMs, correlating with either erosion of bone on CT studies or decreased marrow signal intensity on T1-weighted images (Fig. 6).

Two patients with invasive combined vascular malformations showed features of both venous malformations and AVMs. They tended to be predominantly solid, deeply infiltrative masses demonstrating intermediate and high signal on T1-weighted and T2-weighted images, respectively (Fig. 7). Varying degrees of arteriovenous shunting were also present depicted as serpiginous flow voids. Both patients demonstrated associated bony deformity and abnormal decreased bone marrow signal intensity on T1-weighted images within adjacent structures (Fig. 7).

Discussion

Low-Flow Vascular Lesions

Hemangiomas are the most common tumors of the head and neck in infancy and childhood, comprising approximately 7% of all benign soft-tissue tumors (14). Using the classification system proposed by Mulliken and Glowacki (4), the term "hemangioma" is reserved for those lesions that appear in early infancy, rapidly enlarge, and ultimately involute via fatty replacement by adolescence. The hemangioma may first be detected as an erythematous macular patch, a blanched spot, or a localized telangiectasia, surrounded by a pale halo. Deeper lesions may show only a slightly bluish hue, or the overlying skin may be normal in appearance. The histologic appearance of these lesions depends on the stage of evolution at which they are examined (4, 15). Early lesions are characterized by plump, proliferating endothelial cells that line vascular spaces with small inconspicuous lumina and contain large numbers of mast cells. With lesion maturation, blood flow through these low-flow lesions commences and the vascular endothelium becomes flattened. Regression, or involution, of the hemangioma is accompanied by fibrofatty infiltration and low mast cell counts. Hemangiomas, previously termed "strawberry hemangiomas," are more commonly superficial, and easily diagnosed clinically. However, they may extend deeply through all skin layers and into muscles. Such deep hemangiomas may present as nonspecific soft-tissue masses, making their clinical diagnosis more difficult. In these patients, MR studies may be of use in assessment of these lesions (see below). Bony deformity or skeletal hypertrophy may be associated with hemangioma, but intraosseous invasion is extremely uncommon (6).

Vascular malformations comprise the second major category of congenital vascular lesions (4). This group of lesions reflects abnormalities in blood and lymphatic vessel morphogenesis. Histologically, these vascular lesions are characterized by normal endothelial cells and normal numbers of mast cells throughout their natural history (4, 15). Unlike hemangiomas, vascular malformations are present at birth, although they may not be clinically evident until late infancy or childhood. The growth of these lesions is commensurate with that of the patient and they do not regress or involute. Rapid enlargement of these malformations may occur as a result of trauma, infection, or endocrine changes (eg, pregnancy, puberty) (16). Skeletal abnormalities are more commonly seen in association with vascular malformations (35%) than with hemangioma (17). The classification scheme of these lesions is based on the predominant type of anomalous vessel involved and includes low-flow lesions (capillary, venous, and lymphatic malformations) and high-flow lesions (AVMs). Complex vascular malformations sharing features of multiple types of lesions also occur, termed combined vascular malformations.

The capillary malformation has also been termed the "port wine stain," "capillary heman-

gioma," and "naevus flammeus" (1). These lesions are often distributed in one or a combination of the trigeminal nerve dermatomes. The underlying cheek, lip, and gingiva may also be involved resulting in gingival hypertrophy and chronic bleeding. This lesion is also seen in association with the Sturge-Weber syndrome.

Venous malformations have often been termed "cavernous hemangiomas" (1). However, unlike hemangiomas, these lesions do not involute and may involve bone. From an imaging standpoint, however, venous malformations and deep hemangiomas share many MR features making their differentiation difficult. They are predominantly solid soft-tissue masses that may be superficial and well-defined or infiltrate deeply along fascial planes of the head and neck region. It is not uncommon to see numerous small "satellite" lesions adjacent to the bulk of the mass. The diagnosis of venous malformation may be suggested by the presence of enlarged venous lakes, seen as discrete areas of homogeneous high signal on T2-weighted images, and by the presence of phleboliths. The capability of MR to depict venous lakes may be useful in directing sclerotherapy, as was the case in two of our patients.

Lymphatic malformations, also termed "lymphangioma" or "cystic hygroma," consist of anomalous lymphatic channels and cysts varying in size and shape. MR studies typically demonstrate a predominantly multicystic mass, with or without hemorrhage, that insinuates through fascial planes of the head and neck as was seen in our patient and reported in prior studies (18, 19).

Low-flow lesions of the head and neck are managed in two primary ways. Because the majority of hemangiomas in infancy involute spontaneously, a conservative approach with serial observations of the lesion is the optimal form of management (6, 19). For vascular malformations and rapidly growing hemangiomas that are associated with hemorrhage or ulceration, or those that pose a threat to the patient's airway or vision, several types of therapies have been implemented with varying success including steroid administration (20–22), laser photocoagulation therapy (23), sclerotherapy (24, 25), embolization (26, 27), and surgical resection (28–30).

High-Flow Vascular Lesions

AVMs are high-flow vascular lesions that result from abnormal blood vessel morphogenesis. They are much less common than low-flow vascular malformations. The head and neck region is thought to be one of the most frequent sites of congenital AVMs (2). Congenital and acquired arteriovenous fistulas differ in that the congenital type may show multiple communications between arteries and veins, as opposed to a solitary arteriovenous communication more common in posttraumatic lesions (2). Congenital AVMs are always present at birth, although they may not be clinically apparent until late infancy or childhood. Their growth is commensurate to that of the child, and they do not involute (4–6). Spontaneous enlargement of these malformations may occur due to vessel dilatation following vascular thrombosis, infection, trauma, or endocrine stimulation during puberty or pregnancy (16).

AVMs of the head and neck may be complicated by hemorrhage, loosening of teeth, and infection (6). These patients should undergo complete hematologic evaluation for possible associated coagulopathy as well as selective arteriography to determine the hemodynamic status of the lesion. Selective embolization of the lesion is often helpful prior to surgical intervention (16, 28, 30).

There is a subgroup of patients with combined vascular malformations, that shares features of both low- and high-flow lesions (6). Some of these malformations differ from other subtypes in that they are highly invasive, resistant to all forms of therapy, and can be enormous in size. As seen in our two patients, these lesions tend to involve the deep subcutaneous tissue and musculature. On MR, these lesions demonstrate serpiginous flow voids, characteristic of AVM, as well as infiltrating soft-tissue components typical of venous malformations. All types of vascular malformations have been identified as precursors to this invasive type of vascular lesion (2, 6).

In summary, the initial step in management of a patient with a vascular lesion is to determine whether it is a high- or low-flow lesion, or a combined malformation. History and physical examination often allow clinical diagnosis. In more difficult cases, MR imaging studies may be of help. Low-flow lesions (hemangiomas and capillary, venous, and lymphatic malformations) demonstrate a distinct MR appearance allowing their diagnosis and differentiation from high-flow lesions (AVMs). However, deep hemangiomas and venous malformations are difficult to distinguish as they are predominantly solid-appearing lesions that may look identical on MR studies. Some

venous malformations have prominent dilated veins; the ability of MR to depict these venous lakes helps in differentiation from other types of malformations and may be useful in directing sclerotherapy of these lesions. MR is especially useful in delineating the extent of disease and presence of bone marrow involvement.

References

1. Mulliken JB. Classification of vascular birthmarks. In: Mulliken JB, Young AE, eds. *Vascular birthmarks: hemangiomas and malformations.* Philadelphia: Saunders, 1988:24–37
2. Batsakis JG. *Tumors of the head and neck: clinical and pathological considerations.* 2nd ed. Baltimore: Williams and Wilkins, 1979: 291–312
3. Enzinger FM, Weiss SW. Soft tissue tumors, 2nd ed. St. Louis: Mosby, 1988:489–532
4. Mulliken JB, Glowacki J. Hemangiomas and vascular malformations in infants and children: a classification based on endothelial characteristics. *Plast Reconstr Surg* 1982;69:412–420
5. Finn MC, Glowacki J, Mulliken. Congenital vascular lesions: clinical application of a new classification. *J Pediatr Surg* 1983:18;894–899
6. Kaban L, Mulliken JB. Vascular anomalies of the maxillofacial region. *J Oral Maxillofac Surg* 1986;44:203–213
7. Burrows PE, Mulliken JB, Fellows KE, Strand RD. Childhood hemangiomas and vascular malformations: angiographic differentiation. *AJR* 1983;141:483–488
8. Overholt SL, Gado M, Sessions DG, Ogura JH. Angiography in the diagnosis and management of extracranial vascular lesions of the head and neck. *Laryngoscope* 1978;88:1769–1783
9. Barsky SH, Rosen S, Geer DE. The nature and evolution of port wine stains: a computer-assisted study. *J Invest Dermatol* 1980;74: 154–157
10. Thomas ML. Radiological assessment of vascular malformations. In: Mulliken JB, Young AE, eds. *Vascular birthmarks: hemangiomas and malformations.* Philadelphia: Saunders, 1988:141–169
11. Itoh K, Kazumasa N, Togashi K, et al. MR imaging of cavernous hemangioma of the face and neck. *J Comput Assist Tomogr* 1986; 10:831–835
12. Gelbert F, Riche MC, Reizine D, et al. MR imaging of head and neck vascular malformations. *J Magn Reson Imaging* 1991;1:579–584
13. Meyer JS, Hoffer FA, Barnes PD, Mulliken JB. Biological classification of soft tissue vascular anomalies: MR correlation. *AJR* 1991;157: 559–564
14. Watson WL, McCarthy WD. Blood and lymphatic vessel tumors: report of 1056 cases. *Surg Gynecol Obstet* 1940;71:569–588
15. Glowacki J, Mulliken JB. Mast cells in hemangiomas and vascular malformations. *Pediatrics* 1982;70:48–51
16. Mulliken JB. Vascular malformations of the head and neck. In: Mulliken JB, Young AE, eds. *Vascular birthmarks: hemangiomas and malformations.* Philadelphia: Saunders, 1988:301–342
17. Boyd JB, Mulliken JB, Kaban LB, Upton J, Murray JE. Skeletal changes associated with vascular malformations. *Plast Reconstr Surg* 1984;74:789–795
18. Reede DL, Holliday RA, Som PM, Bergeron RT. Nonnodal pathologic conditions of the neck. In: Som PM, Bergeron RT, eds. *Head and neck imaging.* 2nd ed. St. Louis: Mosby, 1991:531–557
19. Mancuso AA, Dillon WP. The neck. *Radiol Clin North Am* 1989;27: 407–434
20. Bartlett JA, Riding KH, Salkeld LJ. Management of hemangiomas of the head and neck in children. *J Otolaryngol* 1988;17:111–120
21. Edgerton MT. The treatment of hemangiomas. *Ann Surg* 1976;183: 517–530
22. Sasaki GH, Pang CY, Wittliff L. Pathogenesis and treatment of infant skin strawberry hemangiomas: clinical and in-vitro studies of hormonal effects. *Plast Reconstr Surg* 1984;73:359–368
23. Apfelberg DB, Maser MR, White DN, Lash H. A preliminary study of the combined effect of Neodymium: YAG laser photocoagulation and direct steroid instillation in the treatment of capillary/cavernous hemangiomas of infancy. *Ann Plastic Surg* 1989;22:94–104
24. Yakes WF, Haas DK, Parker SH, et al. Symptomatic vascular malformations: ethanol embolotherapy. *Radiology* 1989;170:1059–1066
25. Berthelsen B, Fogdestam I, Svendsen P. Venous malformations in the face and neck: radiologic diagnosis and treatment with absolute ethanol. *Acta Radiol* 1986;27:149–155
26. Leikensohn JR, Epstein LI, Vasconez LO. Superselective embolization and surgery of noninvoluting hemangiomas and A-V malformations. *Plast Reconstr Surg* 1981;68:143–152
27. Forbes G, Earnest F, Jackson IT, Marsh WR, Jack CR, Cross SA. Therapeutic embolization angiography for extra-axial lesions in the head. *Mayo Clin Proc* 1986;61:427–441
28. Persky MS. Congenital vascular lesions of the head and neck. *Laryngoscope* 1986;96:1002–1015
29. Biller HF, Krespi YP, Som PM. Combined therapy of vascular lesions of the head and neck with intra-arterial embolization and surgical excision. *Otolaryngol Head Neck Surg* 1982;90:37–47
30. Persky MS, Berenstein A, Cohen NL. Combined treatment of head and neck vascular masses with preoperative embolization. *Laryngoscope* 1984;94:20–27