

Are your **MRI contrast agents** cost-effective?

Learn more about generic **Gadolinium-Based Contrast Agents**.



FRESENIUS
KABI

caring for life

AJNR

MR appearance of extravasated gadolinium contrast medium.

D A Carrier, J J Ford and L A Hayman

AJNR Am J Neuroradiol 1993, 14 (2) 363-364

<http://www.ajnr.org/content/14/2/363>

This information is current as
of May 14, 2024.

MR Appearance of Extravasated Gadolinium Contrast Medium

David A. Carrier,¹ Joseph J. Ford,² and L. Anne Hayman¹

Summary: This case illustrates that a large zone of signal void can be produced on short relaxation time MR images when gadopentate dimeglumine is injected through an infiltrated intravenous catheter. The authors consider the physics behind this paradoxical decrease in signal intensity where there are high concentrations of gadopentate dimeglumine.

Index terms: Contrast media, paramagnetic

It is well known that low tissue levels of gadopentate dimeglumine (Gd-DTPA) produce an increase in signal (ie, enhancement) on T1-weighted magnetic resonance (MR) images. However, very high concentrations of this agent produce a paradoxical decrease in signal intensity on T1-weighted MR scans (1–3). This paper describes the MR appearance of extravasated Gd-DTPA after injection into an infiltrated intravenous line, and considers the physics that accounts for the distinctive signal intensities identified in this case.

Case Report

A 49-year-old man with a right pyriform sinus mass reported to the MRI suite with a left external jugular intravenous line that appeared to be functioning normally. Precontrast long TR (3000/30–80/1) and short TR (800/16/2) images were obtained using a 1.5-T unit with anterior neck coil. The patient was injected through the external jugular intravenous with 0.1 mmol/kg (16 mL) of Gd-DTPA. Immediately after the injection, the patient complained of burning left-sided neck pain which lasted approximately 10 minutes. After the postcontrast short TR axial and coronal images were obtained, the patient noticed that the left side of his neck was enlarging. The nursing staff noted that the IV was infiltrated and it was discontinued.

The precontrast MR scans showed the expected signal characteristics of extravasated fluid in the inferior aspect of the left neck; that is, this area was isointense to muscle on the T1-weighted images and hyperintense on the T2-weighted scans (Fig. 1). After injection of 16 mL of Gd-DTPA, the short TR images of this region developed a markedly hypointense signal when compared to muscle. A

border of surrounding hyperintensity in the adjacent tissues was also identified.

Discussion

Gadolinium contains seven unpaired electrons, resulting in a surrounding dipole 658 times stronger than the dipole associated with protons (1). This produces a dipole-dipole interaction which shortens both T1 and T2 relaxation equally (4). For most normal tissues, T1 is approximately 400 to 700 milliseconds (a relaxation rate of about 2 sec^{-1}) and T2 is approximately 70 to 200 milliseconds (a relaxation rate of about 10 sec^{-1}). At the concentrations achieved for the recommended whole body dose, Gd-DTPA will contribute approximately 1 to 3 sec^{-1} to the relaxation rate for tissues in which it accumulates, reducing T1 by as much as a factor of 2. Thus tissues rich in Gd-DTPA appear hyperintense on short TR images. This degree of relaxation produces a proportionately smaller change in the T2, so there will be only a small change on long TR images. However, if Gd-DTPA accumulates at higher concentrations, it can appreciably shorten the T2 as well as T1 relaxations, appearing as a reduction in signal intensity on both T1- and T2-weighted images. In vivo experiments have confirmed that if the local concentration of Gd-DTPA reaches or exceeds 36 mmol/L, the T2 is reduced enough to cause the signal intensity on T1-weighted images to fall to 10% of its maximum value (2). Undiluted Gd-DTPA has a concentration of 500 mmol/L. At this level, T2 relaxation is so short that there is no discernible signal on a T1-weighted image even when the image is windowed to maximize the signal of water.

This reversal in the expected hyperintense appearance of contrast-enhanced tissues has been reported in two clinical situations. Yousem et al observed an occasional paradoxical signal de-

Received February 25, 1992; accepted and revision requested March 27; revision received on May 12 and accepted May 20.

¹ Radiology Department, Baylor College of Medicine, One Baylor Plaza, Houston, Texas 77030. Address reprint requests to David A. Carrier.

² Otsuka Electronics, Inc, 2555 Midpoint Drive, Fort Collins, CO 80525.

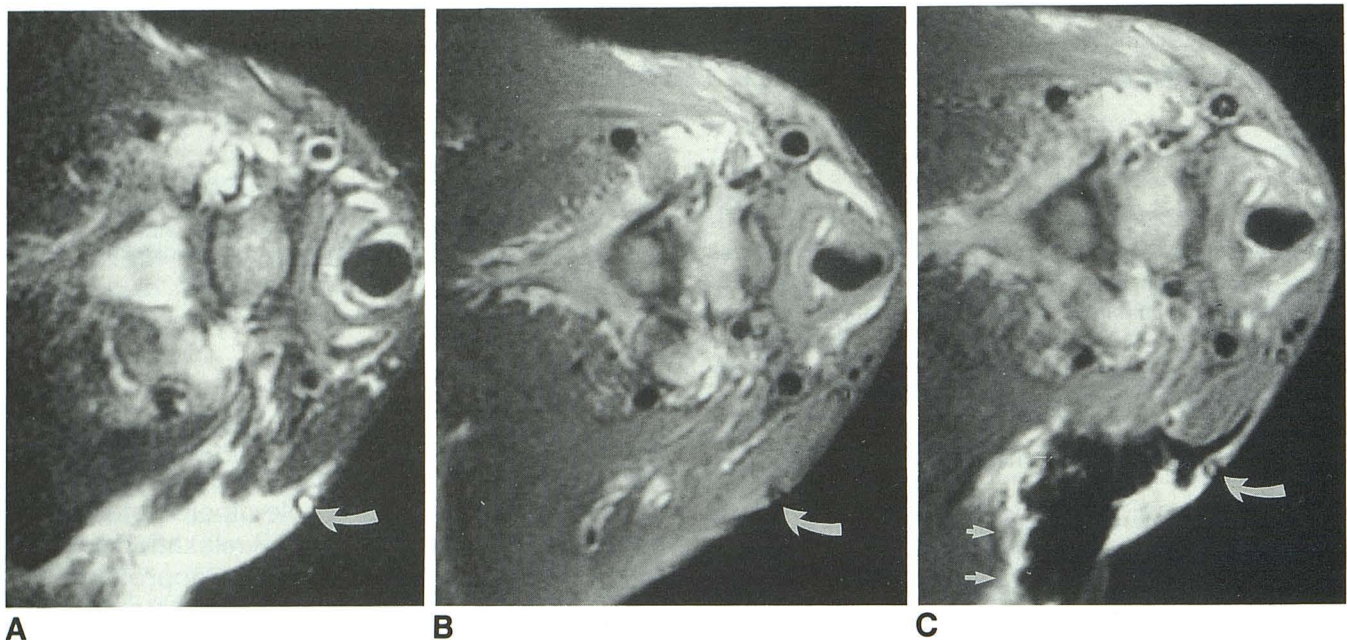


Fig. 1. Axial MR scans of the infrahyoid neck show an intravenous catheter in the external jugular vein (*curved arrows*). The long TR scan (A) shows a diffuse zone of hyperintense signal in the left neck, beneath the intravenous catheter. This area is isointense with the adjacent muscles on the short TR scan (B). After Gd-DTPA, the short TR scan (C) shows marked hypointensity in this area with surrounding areas of markedly "enhanced" hyperintense signal (*small arrows*).

crease in parasellar lesions on short TR images obtained after the administration of gadolinium. They attributed this to the opposing effect of T2 shortening (3). Elster et al also observed this phenomenon in the bladder, where the dependent layer of concentrated Gd-DTPA exhibited markedly hypointense signal (2).

The present report agrees with these clinical studies. It illustrates that a large zone of signal void can be produced on short TR images if Gd-DTPA is injected through an infiltrated intravenous catheter (Fig. 1). The surrounding border of hyperintensity probably represents the more commonly observed increased signal, ie, "en-

hancement," in areas that contain the usually encountered lower levels of Gd-DTPA.

References

1. Gore JC. Contrast agents and relaxation effects. In: Atlas SW, ed. *Magnetic resonance imaging of the brain and spine*. New York: Raven, 1990:69-80
2. Elster AD, Sobol WT, Hinsin WH. Pseudolayering of Gd-DTPA in the urinary bladder. *Radiology* 1990;174:379-381
3. Yousem DM, Ihmeidan I, Quencer RM, Atlas SW. Paradoxically decreased signal intensity on post contrast short-TR MR imaging. *AJNR* 1991;12:875-880
4. Bottomley PA, Foster TH, Arquersinger RE, Pfeifer LM. A review of normal fissure hydrogen NMR relaxation times and relaxation mechanisms from 1-100 Hz dependence on tissue type, NMR frequency, temperature, excision and age. *Med Phys* 1984;11:425-448