

# Generic Contrast Agents

Our portfolio is growing to serve you better. Now you have a *choice*.



FRESENIUS  
KABI

[VIEW CATALOG](#)

# AJNR

## **Sturge-Weber syndrome: cranial MR imaging with Gd-DTPA.**

R A Benedikt, D C Brown, R Walker, V N Ghaed, M Mitchell and C A Geyer

*AJNR Am J Neuroradiol* 1993, 14 (2) 409-415

<http://www.ajnr.org/content/14/2/409>

This information is current as of May 5, 2025.

# Sturge-Weber Syndrome: Cranial MR Imaging with Gd-DTPA

Richard A. Benedikt,<sup>1,2,5</sup> Douglas C. Brown,<sup>1,2</sup> Robert Walker,<sup>3</sup> Victor N. Ghaed,<sup>1</sup> Michael Mitchell,<sup>4</sup> and Carl A. Geyer<sup>1,2</sup>

**PURPOSE:** To study the role of Gd-DTPA in cranial MR of patients with Sturge-Weber syndrome.

**METHODS AND MATERIALS:** Seven patients with Sturge-Weber syndrome, ages 3 months to 36 years, were evaluated with unenhanced and contrast-enhanced (Gd-DTPA) MR imaging. Correlation was made to cranial CT in five patients. **RESULTS:** MR findings included (in decreasing frequency): pial angiomas, cerebral atrophy, decrease in cortical veins, enlargement of deep veins, enlargement of choroid plexus, and parenchymal calcification. Contrast MR imaging was essential in diagnosis in four cases in which cranial CT, unenhanced MR, or angiography was normal or demonstrated nonspecific abnormalities. Pial angiomas with adjacent cerebral atrophy were the only consistent radiographic abnormalities. **CONCLUSION:** In all patients, contrast MR demonstrated the radiographic spectrum of central nervous system abnormalities in Sturge-Weber syndrome to a greater degree than unenhanced MR or CT and may represent the method of diagnosis in these patients. Demonstration of the pial angioma on contrast MR should be considered the most important criterion for the radiographic diagnosis of Sturge-Weber syndrome.

**Index terms:** Phakomatoses; Contrast media, paramagnetic

AJNR 14:409-415, Mar/Apr 1993

Sturge-Weber syndrome (SWS, encephalotrigeminal angiomas) has been characterized clinically by facial nevus flammeus (port wine stain) and a spectrum of central nervous system (CNS) manifestations to include seizure disorder, mental retardation, dementia, hemianopsia, glaucoma, hemiparesis, and hemiatrophy (1-3). Plain film, angiographic, and pneumoencephalographic

findings included bone/sinus hypertrophy, parenchymal atrophy and calcification, and abnormal venous drainage (4-6). Cranial computed tomography (CT) replaced these imaging modalities, largely due to the increased sensitivity and earlier detection of parenchymal calcification. Gyriform contrast enhancement on CT was described, but the etiology remained unclear (7-9). Unenhanced magnetic resonance (MR) has been shown to be more sensitive than CT in detecting CNS abnormalities, with exception of parenchymal calcification (10-12). Description of contrast-enhanced MR imaging in patients with SWS are limited (13, 14), with these authors hypothesizing gyriform enhancement to represent visualization of pial angiomas. We reviewed seven patients with a spectrum of radiographic and clinical findings to determine the relative importance in diagnosis and provide recommendations for the imaging of pediatric and adult patients with suspected SWS.

## Subjects and Methods

Seven patients presented for a cranial MR scan during a 2-year period (known diagnosis of SWS in three patients). All scans were performed on a 1.5-T Signa (General Electric, Milwaukee, WI). Noncontrast scans included axial T1-weighted (T1W) (650/20/1) (TR/TE/excitations), and axial

Received June 17, 1991; revision requested August 26; final revision received March 11, 1992 and accepted March 16.

The opinions or assertions contained herein are the private views of the authors and are not to be construed as official or as reflecting the views of the Department of the Army, Department of Defense, or the Uniformed Services University of the Health Sciences.

Presented in part at the 1990 and 1991 American Society of Neuroradiology meetings in Los Angeles, CA and Washington, DC.

<sup>1</sup> Department of Radiology, Walter Reed Army Medical Center, 6900 Georgia Avenue, Washington, DC 20307-5001.

<sup>2</sup> Department of Nuclear Medicine and Radiology, Uniformed Services University of the Health Sciences, Bethesda, MD 20814.

<sup>3</sup> Department of Radiology, Albany Medical Center Hospital, Albany, NY 12208.

<sup>4</sup> Section of Pediatric Neurology, Walter Reed Army Medical Center, Washington, DC 20307.

<sup>5</sup> Present address: Department of Radiology, Brooke Army Medical Center, Fort Sam Houston, TX 78234. Address reprint requests to Richard A. Benedikt, MD.

AJNR 14:409-415, Mar/Apr 1993 0195-6108/93/1402-0409

© American Society of Neuroradiology



T2-weighted (T2W) (2500–2800/30–80/1) images. Gradient recalled-echo techniques (100/25/2/25°) were performed in two patients. Contrast-enhanced T1W coronal and axial images were obtained immediately following the bolus intravenous administration of Gd-DTPA (Magnevist, Berlex Laboratories, Cedar Knolls, NJ; 0.1 mmol/kg). Cranial CT scans were available for correlation in five patients: noncontrast only in case 2, and both contrast and noncontrast studies in cases 1, 3, 5, and 7.

The diagnosis of SWS was made by demonstrating pial enhancement on contrast MR adjacent to atrophy in the appropriate clinical setting (ie, seizures, facial nevus, and/or ocular findings).

## Results

Clinical data is summarized in Table 1 and imaging findings are summarized in Tables 2 and 3. All CNS manifestations in our patients were supratentorial, unilateral in six patients and bilateral in one patient. Figures 1 through 4 are

representative images from our patient population and demonstrate the spectrum of radiographic findings in patients with SWS.

## Discussion

### Clinical Features

The clinical diagnosis of SWS has classically been established by the combination of seizure disorder, affecting 75%–90% of patients (1, 15), and the presence of facial nevus (16, 17), affecting approximately 90% of patients. In three of our patients, the clinical presentation was atypical; one patient presented with a seizure disorder and no facial nevus (case 2), a second patient, a 36-year-old man, presented with a facial nevus and psychosis as the sole CNS manifestation (case 7), and a third patient (case 6) was being clinically followed for a subacute infarct. Review of the literature shows neither documentation of

TABLE 1: Clinical data

Case No.	Age/Sex	Seizure Disorder/Type	Side and Location of Facial Nevus	Optic Abnormality	Intelligence	Diagnosis SWS Prior to Study
1	3 mo/F	Yes/generalized	Bilateral V1, V2, V3	None	*	No
2	10 mo/M	Yes/generalized	None	None	*	No
3	8 yr/F	Yes/generalized	Left V1	None	Moderate mr	Yes
4	16 yr/M	Yes/generalized	Left V1	None	Mild mr	Yes
5	20 yr/M	Yes/partial	Right V1	Small left peripheral hemianopsia	Normal	Yes
6	23 yr/M	Yes/partial	Right V2	Small left peripheral hemianopsia	Normal	No
7	36 yr/M	None	Right V1, V2	Mild glaucoma	Normal	No

Note.—\* = Not assessed secondary to age; mr = mental retardation.

TABLE 2: Imaging findings: vascular

Case No.	Pial Angiomatosis; Location	Decrease in Cortical Veins	Enlarged Deep/Subependymal Veins	Choroid Plexus Enlargement/Pattern of Enhancement
1	Bilateral and diffuse, except left frontal lobe	Yes/bilateral	No	Bilateral/ring
2	Left cerebral hemisphere, except occipital lobe	Yes/left	No	None
3	Left cerebral hemisphere, most marked in parietal-occipital region	Yes/left	Yes	Left/ring
4	Left cerebral hemisphere, most marked in posterior parietal region	Yes/left	Yes	Left/uniform
5	Right posterior parietal-occipital lobes	Yes/right	Yes	Right/uniform
6	Right posterior parietal-occipital lobe	No	Yes	Right/uniform
7	Right posterior parietal lobe	Yes/right	Yes	None



TABLE 3: Imaging findings: nonvascular

Case No.	Location of Atrophy Degree	Parenchymal Calcification (CT/T2W/GRE)	Bone Hypertrophy
1	Bilateral cerebral hemispheres (least left frontal lobe)/severe	No/No/No	None
2	Left frontal, temporal, parietal lobes/moderate	No/No/*	None
3	Left cerebral hemisphere (most marked in parietal occipital region)/moderate severe	Yes/Yes/*	Moderate
4	Left cerebral hemisphere (most marked in posterior parietal region)/mild	*/Yes/*	None
5	Right posterior parietal-occipital lobes/mild-moderate	Yes/Yes/Yes	Mild
6	Right posterior parietal-occipital lobes/mild	*/No/No	None
7	Right posterior parietal lobe/mild	No/No/No	None

Note.—\* = not performed.



Fig. 1. Photomicrograph of single gyrus from patient affected with Sturge-Weber syndrome with superficial pial angioma (black arrows). (Autopsy specimen courtesy of J. Smirniotopoulos, MD, Armed Forces Institute of Pathology.)

psychosis as clinical presentation nor an older patient at time of diagnosis. In these three cases in particular, contrast MR depiction of the enhancing pial angioma was essential in establishing the diagnosis of SWS. Our literature review provided no consensus regarding clinical or radiologic diagnosis of SWS and some authors described cases without all typical features as "SWS variants" or "incomplete SWS" (16, 18). We propose that these patients should be described as SWS with atypical features and that the contrast

MR depiction of the pial angioma is the essential feature of the diagnosis.

Although some reports have proposed poor prognosis in patients with SWS (1, 6), retrospective study of over 100 patients over 45 years demonstrated normal intelligence in approximately 50% of patients (15). Prognosis was worsened in patients with bihemispheric involvement and presence of seizure disorder, particularly early onset. The findings with our patients, which include older patients with mild symptoms and a college student, support that prognosis may be good and that the patients may present later in life.

SWS has been described to have an equal sex predilection (1). However, of our seven patients, five were male. In addition, pooling of data from six major papers on SWS over the last 40 years reveals a significant male predominance (104 male, 68 female) (4, 5, 11, 13, 15, 17).

### Imaging Features

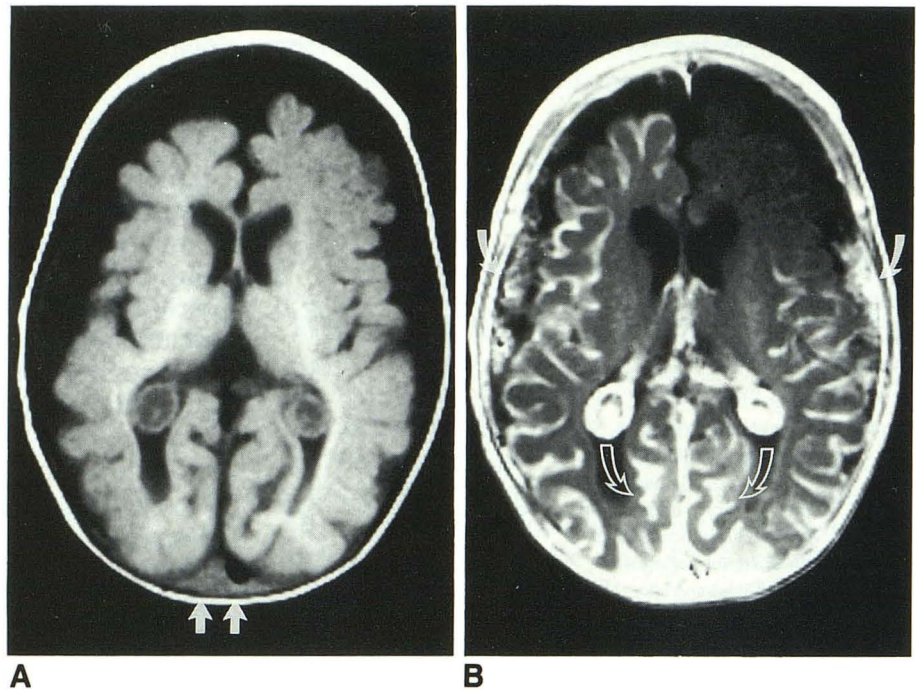
Four CNS vascular abnormalities have been described in patients with SWS: pial or leptomeningeal angiomatosis, absence or decrease in cortical veins, prominence of deep venous system, and choroid plexus enlargement (angiomatous malformation) (4, 10, 11, 13). It is the demonstration of these abnormalities, particularly the pial angioma, that makes contrast MR so essential in establishing the diagnosis of SWS (Figs. 2A, 2B, 3D and 4E).

The pial angioma has always been clearly demonstrated on pathologic examination (1, 5, 19). However, prior to enhanced MR, visualization of the angioma has been difficult. Gyriform enhancement on CT has been attributed to cortical enhancement due to seizures or hypoxia (7–9). Recent reports have attributed enhancement on MR to visualization of the pial angioma (13, 14). We have observed that, in all of our patients, there was an apparent decrease in cerebrospinal fluid spaces adjacent to the angiomatosis following contrast administration which we feel proves that the enhancement is on the surface of the brain (within the angioma) and not within the cortex (Figs. 2B and 3C). Although pathologic reports describe the angioma to measure only 150  $\mu$ m (1), the angioma was readily visible on contrast MR, measuring up to 2–3 mm. The angioma is likely much larger in vivo than on biopsy specimens or postmortem. Pial enhancement in the angioma correlated well with the



Fig. 2. Case 1. A, Noncontrast axial T1W MR image reveals bilateral atrophy (right greater than left) with bilateral choroid plexus enlargement. Note partial sagittal sinus thrombosis confirmed with prior contrast CT with classic "delta sign" (white arrows).

B, Contrast axial T1W MR image at same level reveals bilateral diffuse pial enhancement of angioma (right greater than left) corresponding to areas of atrophy with ring enhancement of the choroid plexus. Note enhancement fills calcarine fissure (open arrows) bilaterally indicating extraaxial location of pial enhancement. Bilateral enlarged dural veins demonstrate enhancement (solid arrows).



presence of atrophy, although it was more extensive. We consider demonstration of the pial angioma on contrast MR essential in establishing the diagnosis of SWS.

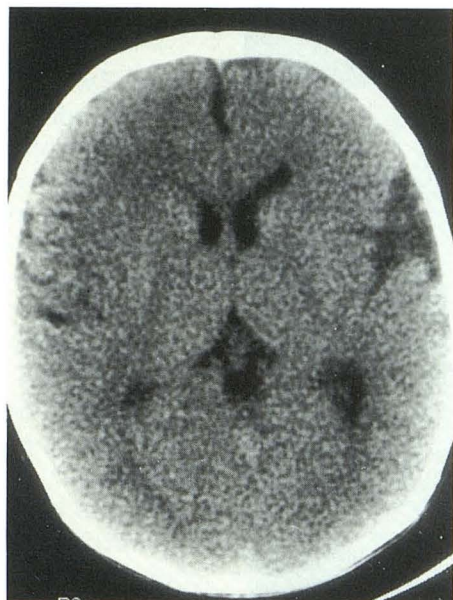Bentson et al (4) analyzed cerebral blood flow patterns in 15 patients with SWS, and concluded that leptomeningeal angiomas represented the essential pathologic feature and lack of cortical veins (thrombosis vs agenesis) was the primary venous abnormality, although their relationship was not determined or proposed. We noted absent or decreased cortical veins on T2W axial scans in the effected hemisphere in all but one of our patients, although in two patients this finding was subtle. Bentson et al (4) also noted increased deep medullary veins as the collateral pathway between cortical and deep veins and a decrease in filling of the sagittal sinus following intraarterial injection on affected side. One of our patients, case 1, had thrombosis of sagittal sinus by both CT and MR. One possible explanation of this finding is markedly decreased flow into sagittal sinus secondary to bilateral SWS with subsequent stasis of blood and eventual thrombosis. The thrombosis appeared as a classic "delta sign" on enhanced CT, probably chronic given recanalization of the left side of the sinus on MR (Fig. 2A).

Prominence of deep medullary or subependymal veins, likely secondary to abnormalities in cortical venous drainage, has been described in CT, MR, and angiography literature (4, 12, 13).

Enlargement of the deep or subependymal veins were noted in five of our patients as areas of signal-void on unenhanced images. The deep veins were not present in our infant patients (cases 1 and 2), which may represent a function of duration of disease. We feel that the enlarged deep veins represent collateral drainage which becomes necessary in the developing brain. The deep veins were more prominent on enhanced scans in all patients, a finding observed previously (13). Enlarged deep veins were most prominent in cases 5, 6, and 7. These patients were the oldest in our series, of normal intelligence, and demonstrated the least amount of pial angiomas.

In one patient, case 5, contrast CT 10 years previous to our evaluation demonstrated diffuse pial enhancement and no marked enlargement of the deep venous system. Clinically, the patient had poorly controlled seizures at that time (Figs. 4A and 4B). Ten years later, contrast MR demonstrated only localized pial angiomas with striking prominence in the deep venous system (Figs. 4C and 4D). Clinically, the patient had well-controlled seizures, stable homonymous hemianopsia, and was attending college full-time. In this case, the enhancing pial angioma clearly regressed over time as the deep veins became prominent. We feel that prominent deep veins and leptomeningeal angiomas develop as a consequence of absent or hypoplastic cortical veins rather than a distinct abnormality. The





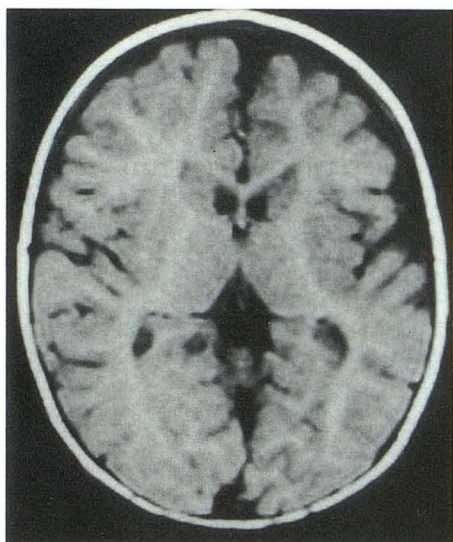
A

Fig. 3. Case 2. A, Noncontrast CT demonstrates asymmetric prominence of left sylvian fissure (indicating atrophy) without evidence of calcification.

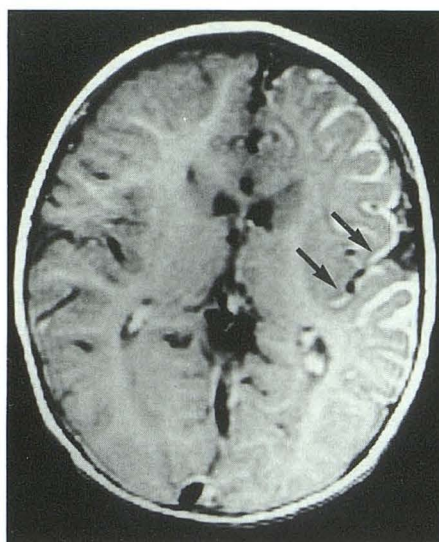
B, Noncontrast axial T1W MR image confirms left cerebral atrophy.

C, Contrast axial T1W MR image demonstrates diffuse hemispheric pial enhancement within angioma. Note sylvian fissure filled with enhancing pial angioma (*black arrows*).

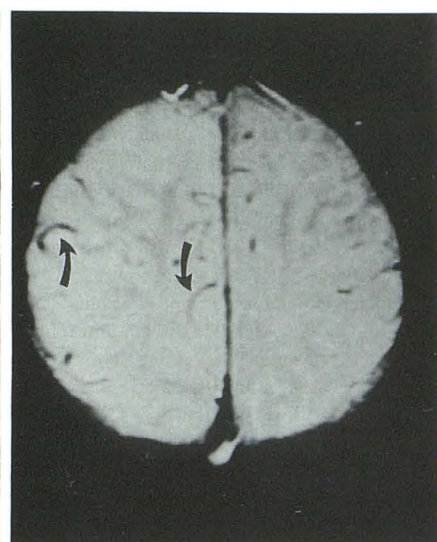
D, Noncontrast axial proton MR image demonstrates normal cortical veins in unaffected hemisphere (*curved arrows*) with asymmetric decrease in the affected left hemisphere.



B



C



D

development of enlarged deep veins may lead to a better collateral circulation and preservation of cortical function as well as regression of the pial angioma. The etiology of the abnormal cortical veins is not clear but has been postulated to be secondary to either aplasia or thrombosis during development (4).

Enlarged choroid plexus, ipsilateral to the pial angiomatosis, has been described in several reports and had described as hemangioma, angiomatous malformation, or hyperplasia (7, 11). We feel that this enlargement represents an additional sequelae of abnormal venous drainage with engorgement of the choroid secondary to collateral venous flow.

In only two patients (cases 3 and 5) was CT, performed with and without contrast, considered diagnostic of SWS. Gyriiform enhancement likely in the pial angioma was clearly visible in these cases. Only one patient (case 5) had "tram-track" cortical calcification of SWS seen as signal-voids on spin-echo MR images and confirmed by CT. Atypical punctate cortical calcification was noted on CT, T2W, or gradient recalled-echo images in two patients (cases 3 and 4). Calcification is thought to occur secondary to hypoxia and ischemic injury (4); however, the presence of calcification is not essential in establishing the diagnosis of SWS. Two patients (cases 1 and 6) had enhancing pial angioma on MR that was not



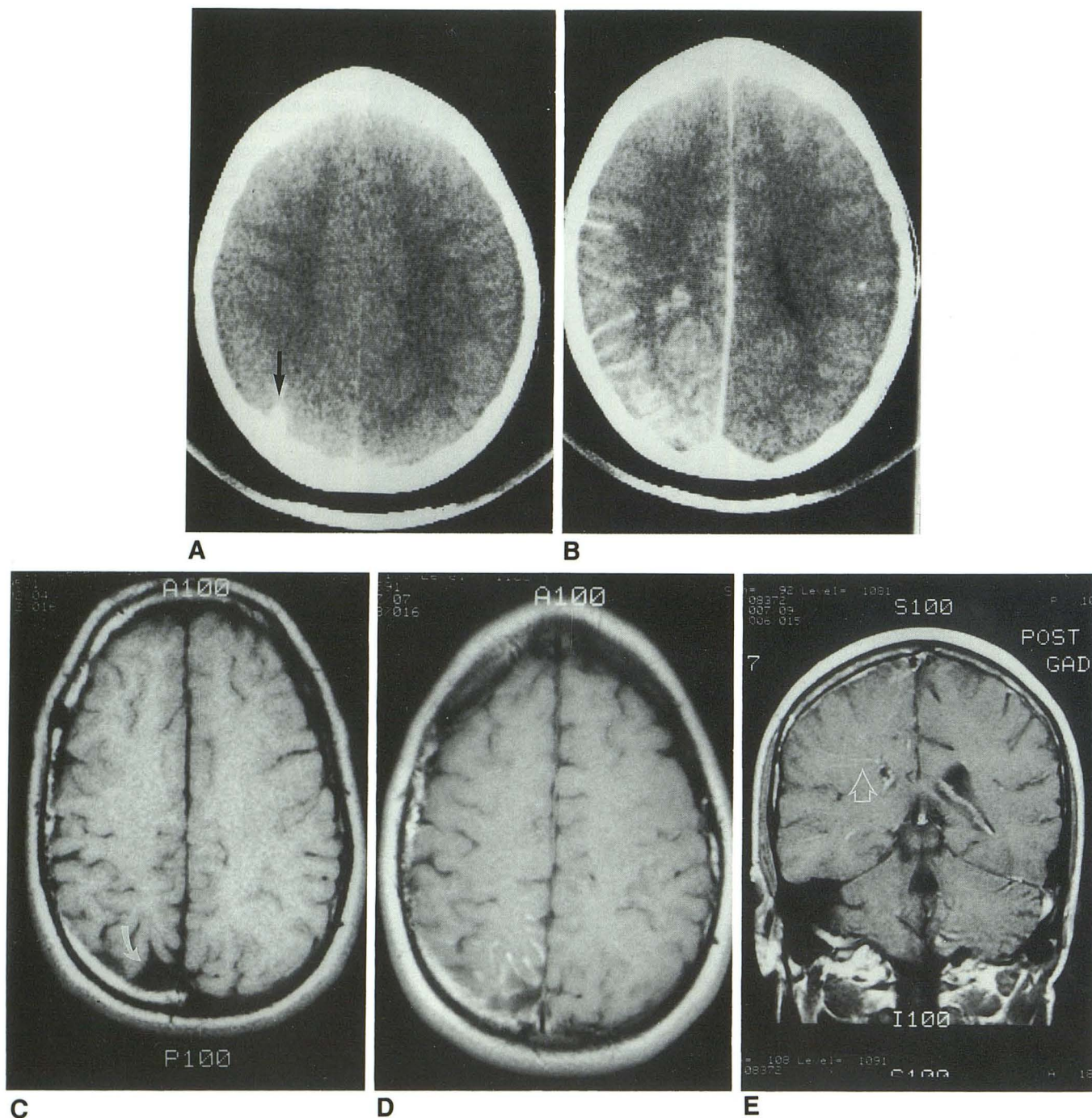


Fig. 4. Case 5. A, Noncontrast CT with focus of calcification in right parietal lobe (*arrow*) without significant atrophy. B, Contrast CT with diffuse pial enhancement in right hemisphere within angioma. C, Noncontrast axial T1W MR image (10 years following CT) demonstrating mild right parietal atrophy (*curved white arrow*). D, Contrast axial T1W MR image demonstrating enhancement adjacent to areas of atrophy. Note marked regression of pial angioma as compared to previous contrast CT. E, Contrast coronal T1W MR image demonstrating enhancement within deep veins (*open arrow*) of involved hemisphere.

demonstrated on enhanced CT. In one of these patients (case 6), the finding of atrophy and enlargement of the deep venous system on contrast CT initially suggested the diagnosis of SWS that was confirmed by demonstrating the pial

angioma on enhanced MR. Clearly, although CT may show findings consistent with SWS, contrast MR with its ability to demonstrate the pial angioma is the only study that need be performed to establish the diagnosis.



## Conclusion

SWS is more common in males (1.5/1) and diagnosis may be delayed in patients with mild symptoms.

Contrast-enhanced MR may demonstrate all vascular abnormalities seen in SWS. Because of its sensitivity in the demonstration of the enhancing pial angioma on the surface of the atrophic brain in SWS, contrast MR is the most useful study in the radiologic diagnosis of SWS. Contrast MR may provide diagnosis despite normal or nonspecific findings on noncontrast MR, CT, or angiography.

Contrast MR also supports the theory that the pial angioma and deep veins are collateral pathways made necessary because of absence of the cortical veins. Vascular abnormalities are not static over time and may be related to the age at which the patient is imaged. Enlargement of deep veins may allow regression of the pial angioma with increasing prominence of the deep veins, which may be associated with a better prognosis and later presentation.

## References

- Alexander GL. Sturge-Weber syndrome. In: Vinken B, Bruyn GW, eds. *Handbook of clinical neurology*. Vol 14. Amsterdam: North Holland, 1972:223-240
- Sturge WA. A case of partial epilepsy apparently due to a lesion of one of the vaso-motor centers of the brain. *Trans Clin Soc London* 1879;12:162-167
- Weber FP. Right-sided hemi-hypertrophy resulting from right-sided congenital spastic hemiplegia, a morbid condition of the left side of the brain, revealed by radiograms. *J Neurol Psychopathol* 1922;3:134-139
- Bentson JR, Wilson GH, Newton TH. Cerebral venous drainage pattern of the Sturge-Weber syndrome. *Radiology* 1971;101:111-118
- DiChiro G, Lindgren E. Radiographic findings in 14 cases of Sturge-Weber syndrome. *Acta Radiol* 1951;35:387-399
- Probst FP. Vascular morphology and angiographic flow patterns in Sturge-Weber angiomas: facts, thoughts, and suggestions. *Neuroradiology* 1980;20:73-78
- Barkovich AJ. Phakomatoses. In: Barkovich AJ, ed. *Pediatric neuroimaging*. Contemporary Neuroimaging, vol 1. New York: Raven Press, 1990:123-147
- Enzmann DR, Hayward RW, Norman D, Dunn RP. Cranial computed tomographic scan appearance of Sturge-Weber disease: unusual presentation. *Radiology* 1977;122:721-724
- Deleted in proof.
- Chamberlain MC, Press GA, Hesselink JR. MR imaging and CT in three cases of Sturge-Weber syndrome: prospective comparison. *AJNR* 1989;10:491-496
- Stimac GK, Solomon MA, Newton TH. CT and MR of angiomatous malformations of choroid plexus in patients with Sturge-Weber disease. *AJNR* 1986;7:623-627
- Wasenko JJ, Rosenbloom SA, Duchesneau PM, Lanzieri CF, Weinstein MA. The Sturge-Weber syndrome: comparison of MR and CT characteristics. *AJNR* 1990;11:131-134
- Elster AD, Chen MYM. MR imaging of Sturge-Weber syndrome: role of gadopentetate dimeglumine and gradient-echo techniques. *AJNR* 1990;11:685-689
- Lipski S, Brunelle F, Aicardi J, Hirsch JF, Lallemand D. Gd-DOTA-enhanced MR imaging in two cases of Sturge-Weber syndrome. *AJNR* 1990;11:690-692
- Bebin EM, Gomez MR. Prognosis in Sturge-Weber disease: comparison of unihemispheric and bihemispheric involvement. *J Child Neurol* 1988;3:181-184
- Gomez MR, Bebin EM. Sturge-Weber syndrome. In: Gomez MR, Ed. *Neurocutaneous diseases: a practical approach*. Boston: Butterworth, 1987:356-367
- Peterman AF, Hayles AB, Dockerty MB, Love JG. Encephalotrigeminal angiomatosis (Sturge-Weber disease): clinical study of thirty-five cases. *JAMA* 1958;167:2169-2176
- Poser CM, Taveras JM. Cerebral angiography in encephalo-trigeminal angiomatosis. *Radiology* 1957;68:327-336
- Wohlwill FJ, Yakovlev PL. Histopathology of meningofacial angiomatosis (Sturge-Weber's disease). *J Neuropathol Exp Neurol* 1957;16:341-364