

Generic Contrast Agents

Our portfolio is growing to serve you better. Now you have a *choice*.



FRESENIUS
KABI

[VIEW CATALOG](#)

AJNR

CNS complications in acute malaria: MR findings.

J M Millan, J M San Millan, M Muñoz, E Navas and R Lopez-Velez

AJNR Am J Neuroradiol 1993, 14 (2) 493-494

<http://www.ajnr.org/content/14/2/493>

This information is current as
of May 6, 2025.

CNS Complications in Acute Malaria: MR Findings

Jose M. Millan,^{1,2} Juan M. San Millan,¹ Maria Muñoz,¹ Enrique Navas,¹ and Rogelio Lopez-Velez¹

Summary: MR showed a small, acute hemorrhage adjacent to an area of infarction in the parieto-occipital lobe in a man with acute malaria.

Index terms: Brain, infection; Malaria

Central nervous system (CNS) complications occur in 2% of patients with acute malaria (1). These include cerebral edema, infarcts, and petechial hemorrhages (2, 3). In CNS complications of malaria, there have been few descriptions of computed tomography (CT) features (4, 5) and, to our knowledge, no magnetic resonance (MR) findings have been reported.

Case Report

A 71-year-old man was admitted to the hospital with a 7-day history of spiking fever, headache, and malaise. Progressive clouding of consciousness and aphasia had appeared 24 hours prior to admission. He had returned from Equatorial Guinea in West Africa 12 days earlier. Neurologic examination revealed a lethargic patient with an expressive aphasia. Admission CT of the brain did not reveal abnormalities. Blood smears were positive for 0.5%–1% parasitemia with trophozoites and gametocytes consistent with falciparum malaria. MR of the brain at 1.5 T performed 5 days after the onset of neurologic symptoms (Figs. 1A–1C) showed a small area of increased signal intensity on T1-weighted and T2-weighted images in subcortical white matter of the left parietal region compatible with a hemorrhagic lesion, and a large left posterior parieto-occipital hyperintense area on T2-weighted images consistent with infarction. Within 2 days of treatment with intravenous quinine, the patient's speech improved and his lethargy diminished. Follow-up MR obtained 24 days later (Figs. 1D and 1E) showed a decrease in size of the lesions.

Discussion

CNS complications of acute malaria occur in about 2% of patients, and these are usually cerebral. Rarely, transverse myelitis and polyneuritis can occur (6). *Plasmodium falciparum* is the usual parasite for these CNS complications. The occlu-

sion of the cerebral capillaries by the infected erythrocytes is the main pathologic mechanism implicated in the production of the neurologic symptoms (2, 3). Oo et al (3) also demonstrated widespread deposits of parasite antigens and IgG in capillary basement membranes. Consistently, small hemorrhages, infarcts, and edema can occur in the white matter of the brain.

Few CT observations have been reported in CNS complications of malaria. Looareesuwan et al (4) studied 10 cases with CT and found four with nonenhancing focal areas of altered density in the brain, two with cerebral edema, and four with normal scans. Pham-Hung et al (5) described an additional case of malaria with a temporal lobe ischemic infarction. MR in our case shows the cerebral vascular complications associated with this infectious disease.

In conclusion, CNS complications of malaria should be suspected in patients who have traveled in endemic areas and present with neurologic symptoms. MR is recommended in such cases because of its sensitivity in showing edema and small areas of hemorrhage. Early antimalarial therapy can lead to dramatic improvement of neurologic manifestations, as occurred in our case.

References

1. Jubelt B, Miller JR. Parasitic infections. In: Rowland LP, ed. *Merritt's textbook of neurology*. Philadelphia: Lee & Febiger, 1989:164–174
2. Aikawa M. Human cerebral malaria. *Am J Trop Med Hyg* 1988;39:3–10
3. Oo MM, Aikawa M, Than T, et al. Human cerebral malaria a pathological study. *J Neuropathol Exp Neurol* 1987;46:223–231
4. Looareesuwan S, Warrell DA, White NJ, et al. Do patients with cerebral malaria have cerebral edema? A computed tomography study. *Lancet* 1983;1:434–437
5. Pham-Hung G, Truffert A, Delvallée G, Michel G, Laporte JP, Duval G. Infarctus cérébral au cours d'un accès pernicieux palustre: intérêt diagnostique de la tomodensitométrie. *Ann Fr Anesth Reanim* 1990;9:185–187
6. Trenholme GM. Malaria. In: Vinken PJ, Bruyn GW, Klawans HL, eds. *Handbook of clinical neurology*. Revised series. Amsterdam: Elsevier North Holland, 1988:365–375

Received January 9, 1992; revision requested March 9; final revision received May 20 and accepted May 22.

¹ Department of Radiology, Ramon y Cajal University Hospital, 28034 Madrid, Spain

² Address reprint requests to Jose M. Millan, MD, Department of Radiology, Carr. Colmenar 9, Ramon y Cajal University Hospital, 28034 Madrid, Spain.

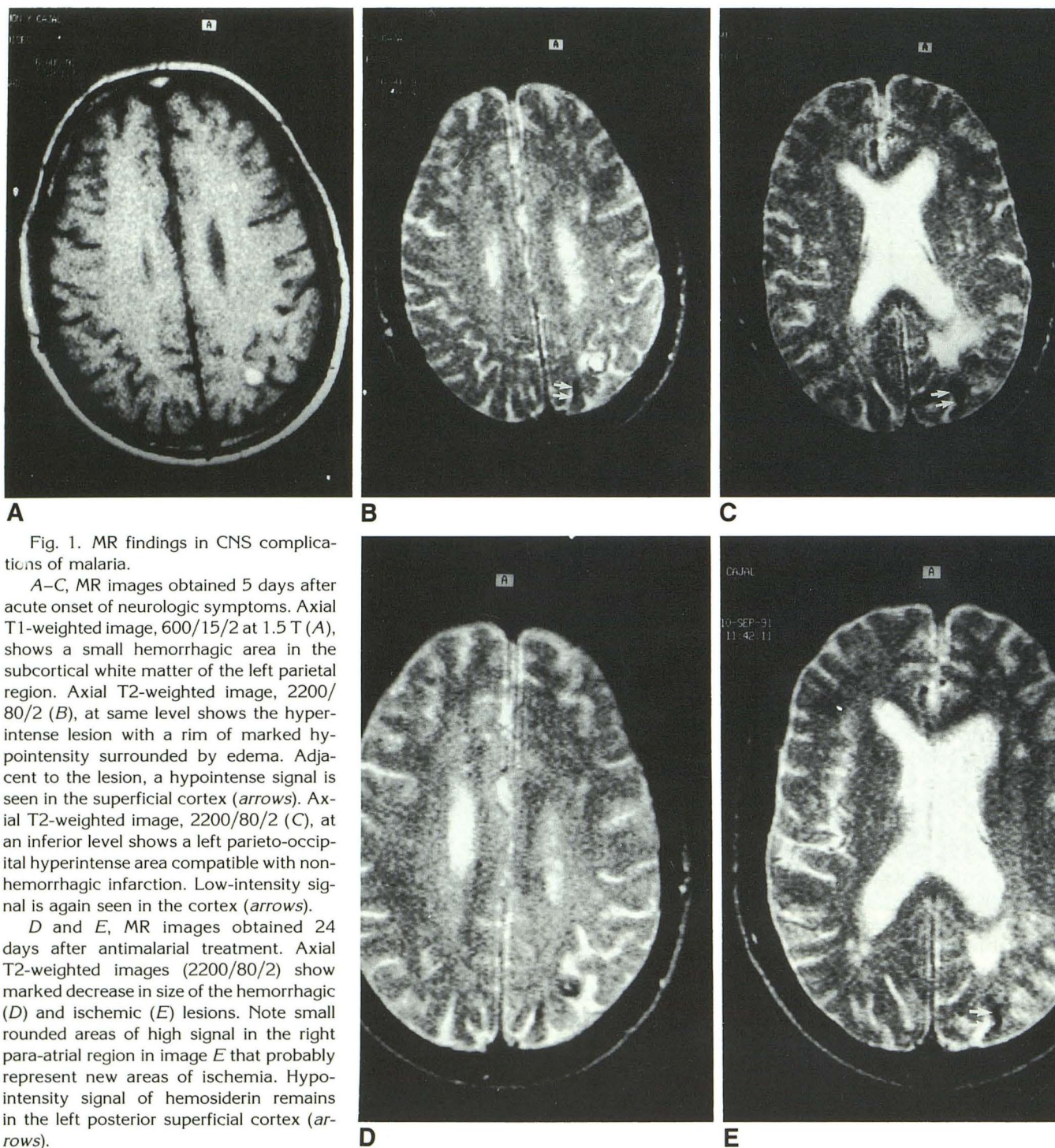


Fig. 1. MR findings in CNS complications of malaria.

A–C, MR images obtained 5 days after acute onset of neurologic symptoms. Axial T1-weighted image, 600/15/2 at 1.5 T (A), shows a small hemorrhagic area in the subcortical white matter of the left parietal region. Axial T2-weighted image, 2200/80/2 (B), at same level shows the hyperintense lesion with a rim of marked hypointensity surrounded by edema. Adjacent to the lesion, a hypointense signal is seen in the superficial cortex (arrows). Axial T2-weighted image, 2200/80/2 (C), at an inferior level shows a left parieto-occipital hyperintense area compatible with non-hemorrhagic infarction. Low-intensity signal is again seen in the cortex (arrows).

D and E, MR images obtained 24 days after antimalarial treatment. Axial T2-weighted images (2200/80/2) show marked decrease in size of the hemorrhagic (D) and ischemic (E) lesions. Note small rounded areas of high signal in the right para-atrial region in image E that probably represent new areas of ischemia. Hypointensity signal of hemosiderin remains in the left posterior superficial cortex (arrows).