AJNR

# Microcatheter retrieval device for intravascular foreign body removal.

T P Smith, V B Graves, V V Halbach, R T Higashida, K W Fraser, C F Dowd and G B Hieshima

*AJNR Am J Neuroradiol* 1993, 14 (4) 809-811
http://www.ajnr.org/content/14/4/809

# Microcatheter Retrieval Device for Intravascular Foreign Body Removal

Tony P. Smith,[1] Virgil B. Graves,[2] Van V. Halbach,[1] Randall T. Higashida,[1] Kenneth W. Fraser,[1] Christopher F. Dowd,[1] and Grant B. Hieshima[1]

**Summary: A microcatheter foreign body retrieval device is described and its first two clinical applications are presented. The device functions identically to larger loop snare retrievers. It permits access to small vessels and was successful in its first clinical applications.**

**Index terms: Catheters and catheterization; Foreign bodies**

Smaller catheter systems have become widely used for superselective catheterization both in the central nervous system and peripheral vasculature for angiography, embolization, chemotherapy, and other applications. Percutaneous foreign body retrieval devices are avalible in a variety of designs, but have thus far been limited to larger catheter systems (1–4). We describe a microcatheter system for endovascular foreign body retrieval and its first clinical applications.

## Instrumentation

The catheter for the snare is the same design already in wide use for microcatheterization (Target Therapeutics, San Jose, CA) (Fig. 1). It consists of a variable stiffness polypropylene and polyethylene shaft which tapers from 3 French to 2.2 French (Tracker 18) or 2.6 French to 2.0 French (Tracker 10). Through the catheter is placed either a 0.014-inch (Tracker 18) or a 0.010-inch (Tracker 10) stainless steel wire. The distal portion of the wire is curved back on itself and soldered to the distal platinum marker and fused to the catheter tip forming a loop snare (Fig. 2). A side arm adaptor is connected to the proximal catheter hub for constant flushing and the proximal end of the guidewire is fitted with a standard torque device. The snare is opened in the usual fashion by simply advancing the wire until the desired amount of wire loop forms distally. The loop can be rotated by using the torque device. The loop is closed by pulling back on the wire until the foreign body is tightly grasped. The catheter is then pulled to the level of the guiding catheter, where the entire complex, including the guiding catheter, is removed through an introducer sheath. The retrieval method is therefore identical to standard snare devices already available (5, 6).

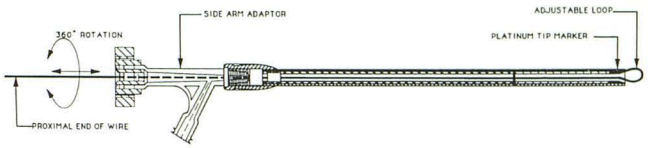


1

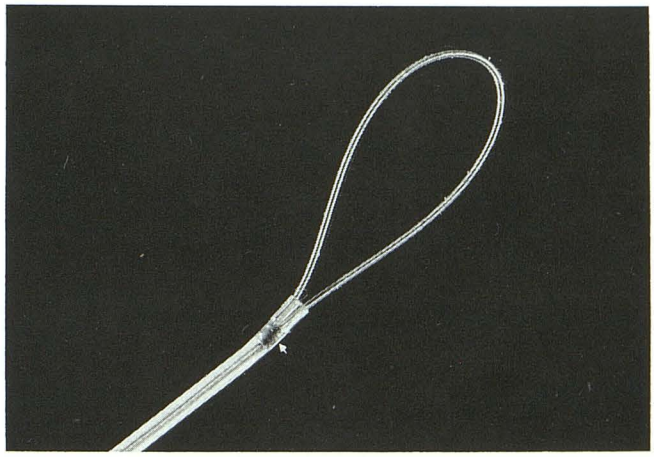

2

Fig. 1. Diagram of microcatheter retrieval system. Only a single wire is placed through the catheter so that the catheter size can be kept to a minimum. Guidewire is then looped upon itself distally and placed under the platinum marker. The snare is opened by advancing the guidewire and closed by retracting the wire. (Diagram courtesy of Target Therapeutics, San Jose, CA.)

Fig. 2. Distal end of the retriever demonstrating wire loop and its fixation under the platinum tip marker (*arrow*). Note that only a single guidewire is passed through the catheter (as visualized through the distal clear segment of the catheter).

## Case Reports

The first patient was a 21-year-old woman with the diagnosis of a left cerebellar hemispheric arteriovenous malformation fed mostly by branches of the left anterior inferior cerebellar

Received May 5, 1992; revision requested August 8; revision received August 27 and accepted October 21.

[1] Department of Radiology, University of California San Francisco, 505 Parnassus Avenue, San Francisco, CA 94143–0628. Address reprint requests to T.P. Smith.

[2] Department of Radiology, University of Wisconsin Medical School, E3/311, Clinical Science Center, 600 Highland Avenue, Madison, WI 53792–0001.

AJNR 14:809–811, Jul/Aug 1993 0195-6108/93/1404–0809 © American Society of Neuroradiology

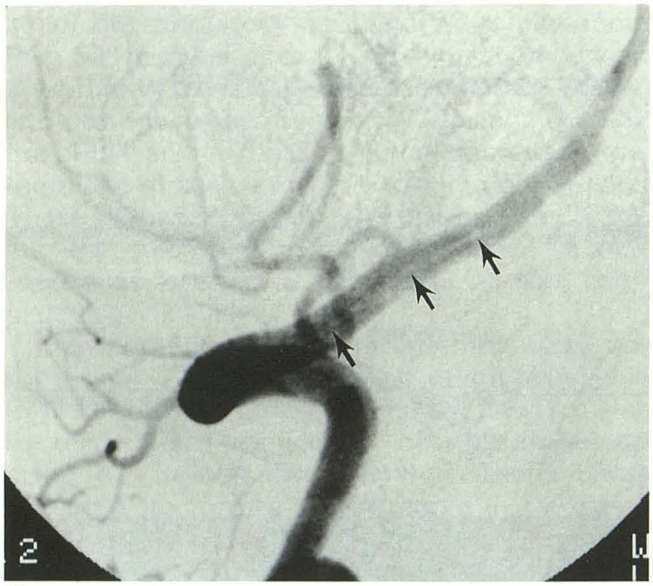

A

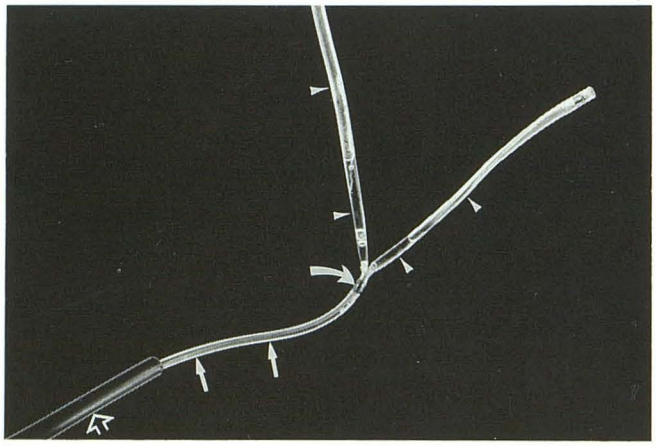

B

Fig. 3. Case 1.

*A*, Angiogram (lateral view) of the vertebral artery demonstrating catheter fragment within the vertebral artery (*arrows*).

*B*, Catheter fragment (*arrowheads*) after removal is still grasped by the snare. The microcatheter (*arrows*) has been advanced from the guiding catheter (*open arrow*) to visualize the microcatheter system better (distal tip marker is shown by *curved arrow*). When removing it from the body, the snare with the foreign body is pulled tight to the microcatheter, which is then pulled to the guiding catheter. The entire system, including the guiding catheter, is then removed from the body via an introducer sheath.

artery. Prior to surgical resection, the patient was to undergo embolization. During attempted embolization, the 3 French coaxial catheter system and 0.016 guidewire were completely broken and separated from the body of the catheter and guidewire (Fig. 3A). The most proximal portion of the guidewire fragment was located in the vertebral artery just beyond the first bend in that artery. The catheter is difficult to visualize, as it is radiolucent except for the distal tip marker that was located in the distal vertebral artery. Initially, a 5 French catheter with an 0.018-inch snare was passed into the left vertebral artery, where the radiopaque guidewire was easily grasped, but the catheter itself was beyond this point. The guidewire was easily removed via the right groin sheath. The 5 French snare was replaced into the left vertebral artery, but could not be advanced farther than the first vertebral artery bend. The new microcatheter snare then was placed through the 5 French guiding catheter and easily traversed the bend in the left vertebral artery. However, advancing the snare also caused the broken catheter to migrate distally, its tip finally resting in the basilar artery. Therefore, the snare was placed via the right vertebral artery to the level of the distal radiopaque tip, where the catheter fragment was easily grasped and removed via the left groin sheath (Fig. 3B). No sequela were noted from the retrieval.

The second patient was a 40-year-old woman with a transverse sinus dural fistula. During attempted embolization of the occipital arterial supply to the fistula, the 3 French microcatheter used for embolization was broken. The most distal portion of the catheter was located distally in the tortuous occipital artery and the most proximal portion of the catheter fragment was located in the external carotid artery. A Tracker 10 snare was advanced through the 7 French guiding catheter to the level of the proximal portion of the catheter fragment, where it was grasped and removed (Fig. 4). As with the first case, no sequelae were noted from the retrieval.

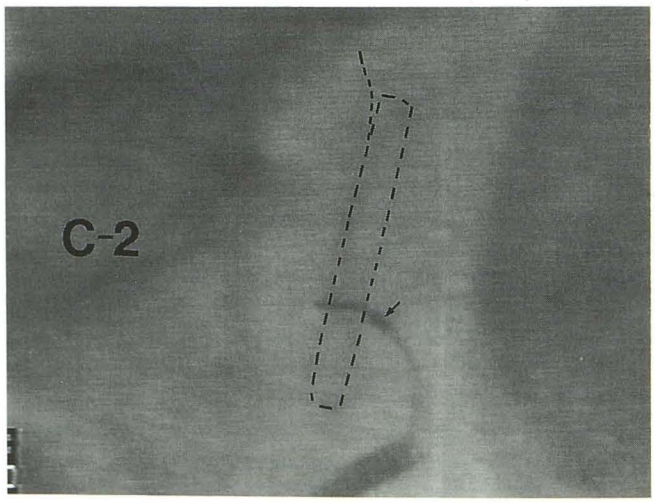


Fig. 4. Case 2. Fragment of broken 3 French catheter (highlighted) in the grasp of the microcatheter snare during removal. The *arrow* shows the platinum tip marker. C-2, body of second cervical vertebra.

## Discussion

With the increasing use of indwelling catheters and endovascular devices, more broken catheters, lost coils, and other foreign bodies must be removed. Although devices such as loop snares, baskets, and forceps have been quite successful, they have been limited to larger introducer systems with large lumens, even when snares were made from 0.018- and 0.014-inch wires. Removal of foreign bodies from small vessels, therefore, previously required repositioning of the foreign body to more accessible locations. This has been accomplished by a variety of means, even dragging the foreign body beside a small inflated balloon (7), obviously not a good measure, particularly when dealing with the central nervous system.

The endovascular retrieval device described here is provided as part of a catheter system. The catheter size itself is determined by the size of the snare, 3 French for the 0.016 snare and 2.6 French for the 0.010 snare. None of the objects is new to anyone familiar with microcatheter systems. The side arm adaptors, torque devices, wires, catheters, and distal markers are identical to those already widely used. The adaptor limits blood loss and allows constant infusion of heparinized saline, which theoretically serves to decrease thrombus formation. Infusion should also provide lubrication for easier opening and closing of the snare.

The objectives and mechanism for removing foreign bodies with the microcatheter device are similar to standard snaring techniques (6), except that a single wire is advanced to open the loop rather than dual wires. Since the wire is single through the catheter, rather than doubled as with the typical snare, catheter size can be kept to a minimum.

In our very limited experience, the snare did not open or close quite as easily as larger systems. In addition, not as much resistance was noted in grasping the foreign body as with larger snares. These factors are probably a reflection of both the smaller size and our tentativeness in the initial use of a smaller system.

Some precautions should be exercised when using the microcatheter system. Since the wire snare is part of the system and cannot be removed, the device must be navigated through the vasculature without a guidewire. It is probably best if a small portion of the wire loop is used to protect the vessels during catheter advancement. In addition, the loop can be rotated slightly to help with navigation. The loop can also be rotated to assist in grasping the foreign body. However, it is probably best not to rotate the loop greater than 180° in either direction to avoid possible entanglement or breakage of the wire loop. Thrombus formation around a foreign body is a well-known complication, and distal embolization is particularly dreaded in the central nervous system. Therefore, it is obviously best to remove the fragment as quickly as possible, but one must be careful not to cause vessel injury, induce spasm, or dislodge the foreign body to an even more difficult location for removal (which, despite careful technique, almost occurred in the first case). The first patient was already anticoagulated; the second patient was anticoagulated immediately after catheter separation, as we felt that this reduced the risk of possible thrombotic and embolic complications.

We have not mentioned in this communication the reasons for catheter breakage. That is obviously the foremost consideration in these cases. The retrieved catheters and wire fragment have been returned to the manufacturer for analysis and we have fully discussed any and all procedural changes to prevent other such incidences from occurring.

The new microcatheter retrieval device was very successful in its first two clinical applications. The snare was utilized in the vascular supply of the central nervous system in both of these cases. However, this system has wide applications, including peripheral small vessels and the coronary arteries. It certainly adds a needed device in the armamentarium of the interventionist for endovascular foreign body retrieval.

## References

1. Furui S, Yamauchi T, Makita K, et al. Intravascular foreign bodies: loop-snare retrieval system with a three-lumen catheter. *Radiology* 1992;182:283–284
2. Yedlicka JW Jr, Carlson JE, Hunter DW, Castaneda-Zuniga WR, Amplatz K. Nitinol gooseneck snare for removal of foreign bodies: experimental study and clinical evaluation. *Radiology* 1991;178:691–693
3. Travelli R, Cogbill TH. Retrieval of a 4-French diagnostic catheter fragment form the common carotid artery by using a stone basket. *AJR: Am J Roentgenol* 1991;156:1105–1106
4. Selby JB, Tegtmeyer CJ, Bittner GM. Experience with new retrieval forceps for foreign body removal in the vascular, urinary, and biliary systems. *Radiology* 1990;176:535–538
5. Fisher RG, Ferreyro R. Evaluation of current techniques for nonsurgical removal of intravascular iatrogenic foreign bodies. *AJR: Am J Roentgenol* 1978;130:541–548
6. Gerlock AJ, Mirfakhraee M. Retrieval of intravascular foreign bodies. *J Thorac Imaging* 1987;2:52–60
7. Ulfacker R, Lima S, Melichar AC. Intravascular foreign bodies: percutaneous retrieval. *Radiology* 1986;160:731–735