

Generic Contrast Agents

Our portfolio is growing to serve you better. Now you have a *choice*.



FRESENIUS
KABI

[VIEW CATALOG](#)

AJNR

Interuncal distance measurements in healthy volunteers and in patients with Alzheimer disease.

B Early, P R Escalona, O B Boyko, P M Doraiswamy, D A Axelson, L Patterson, W M McDonald and K R Krishnan

AJNR Am J Neuroradiol 1993, 14 (4) 907-910

<http://www.ajnr.org/content/14/4/907>

This information is current as
of May 11, 2025.

Interuncal Distance Measurements in Healthy Volunteers and in Patients with Alzheimer Disease

Bridget Early,¹ P. Rodrigo Escalona,¹ Orest B. Boyko,² P. Murali Doraiswamy,¹ Dave A. Axelson,¹ Linda Patterson,¹ William M. McDonald,¹ and K. Ranga Rama Krishnan^{1,3}

PURPOSE: To evaluate further the clinical utility of the interuncal distance (IUD) measured from axial MR scans as a reflection of hippocampal atrophy. **METHODS:** The IUD measured from the axial MR scans of 17 healthy control subjects was correlated with the volume of the amygdala hippocampal complex obtained from coronal MR images. The IUD was also measured on axial MR scans in 12 patients with possible or probable Alzheimer disease. **RESULTS:** The correlation between the total amygdala hippocampal volume and the IUD was insignificant for control subjects ($r = -0.38$, $P = .13$). When analysis of covariance was performed with the IUD as the dependent variable and age and diagnosis as the independent variables, overall R^2 was 0.25. Age ($F = 5.02$, $df = 1$, $P = .034$), but not diagnosis ($F = 0.02$, $df = 2$, $P = .88$), had a significant effect. **CONCLUSIONS:** The IUD has no significant correlation with the amygdala hippocampal volume. The IUD appears to be a better measure of overall brain volume, which changes with age. In our patient population diagnosed with mild to moderate Alzheimer disease, the IUD measurement was not found to be useful in distinguishing their scans from those of the volunteers.

Index terms: Dementia; Degenerative brain disease; Hippocampus; Brain, atrophy; Brain, measurements; Age and aging

AJNR 14:907-910, Jul/Aug 1993

In a recent report, Dahlbeck et al (1) suggested the use of an interuncal distance measurement from transaxial magnetic resonance (MR) images to distinguish patients with Alzheimer disease. They suggested an increased interuncal distance to be reflective of hippocampal formation atrophy associated with Alzheimer disease.

Doraiswamy et al (2) measured interuncal distance on transaxial MR images of 75 healthy volunteers, aged 21 to 82, and found a significant age effect, with elderly subjects having a progressively increased interuncal distance.

To evaluate the validity of interuncal distance as an indirect measure of the hippocampal formation size and potential atrophy, we compared the interuncal distance on axial MR scans with the hippocampal amygdala complex volume ob-

tained using stereology (3) in a group of healthy volunteers. To evaluate further the utility of the interuncal distance in the diagnosis of Alzheimer disease, we studied this measure in healthy control subjects and in patients with possible or probable Alzheimer disease.

Materials and Methods

Subjects

For the volume-interuncal distance correlation, the subjects were 17 healthy volunteers of which nine were women, with an age range of 26 to 78 years (mean age of 49 ± 19 years). They were without significant neurologic or psychiatric illness. For the interuncal distance study, and additional 12 patients, of which seven were women, with the diagnosis of possible or probable Alzheimer disease, based on NINCDS-ADRDA criteria (4), were studied. Age range was 56 to 86 (mean age of 73 ± 9 years). The interuncal distance in the control groups and in the group of patients with Alzheimer disease was compared. Mini-Mental State Exam (MMSE) scores for the group of Alzheimer disease patients ranged from 13 to 25 (mean of 20 ± 4).

Received March 2, 1992; accepted after revision November 5.

¹ Departments of Psychiatry and ² Radiology, Duke University Medical Center, Durham, NC.

³ Address reprint requests to K. Ranga Krishnan, MD, Box 3215, Duke University Medical Center, Durham, NC 27710.

AJNR 14:907-910, Jul/Aug 1993 0195-6108/93/1404-0907

© American Society of Neuroradiology

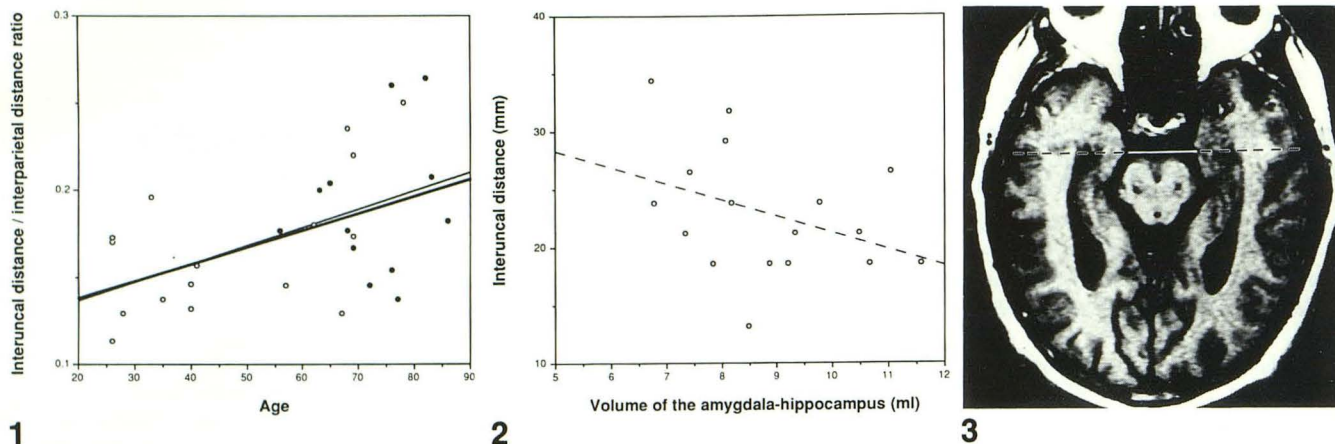


Fig. 1. Illustration of interuncal and interparietal distance measurement on axial section. Key: ○, — = control subjects ($R^2 = .26$); ●, — = patients with Alzheimer disease.

Fig. 2. The interuncal distance correlated with the amygdala/hippocampal volume in healthy control subjects. Key: ○, — = control subjects ($R^2 = .14$).

Fig. 3. The interuncal distance/interparietal distance ratio correlated with age in control subjects and in patients with Alzheimer disease.

MR Procedure

All patients and healthy volunteers had brain MR scans on a 1.5-T General Electric Signa System (Milwaukee, WI). They were positioned in a quadrature head coil with the canthomeatal line at 0 degrees from the vertical axis and the laser grid centered at the nasion. T1-weighted (500/20/0.75, TR/TE/excitations) and T2-weighted (2000–2500/30, 80) spin-echo 5-mm thick axial sections with a 2.5-mm intersection gap were obtained parallel to the canthomeatal line using flow compensation. Coronal images were obtained of all healthy volunteers and patients. These images were graphically prescribed from a midsagittal localizer section and obtained perpendicular to the bicommissural line; they were 5 mm thick and contiguous. All coronal images were acquired with a T1-weighted pulse sequence (500/20).

Volume and Distance Measurements

The volume of the amygdala-hippocampal complex was obtained on the coronal images based on a systematic sampling of the structure of interest (3). No attempt was made to separate the amygdala from the hippocampus inasmuch as their anatomic distinction on the scans is arbitrary and subject to considerable variability. The uncus, cornu ammonis, dentate gyrus fimbria, and subiculum were included. The parahippocampal gyrus was excluded by defining the most medial edge of the medial temporal gray as the point of separation. The anterior limit was the first section in which the amygdala was noted; the posterior limit was the point at which the gyrus fasciolaris and the upward curving of the fimbria were noted. The amygdala-hippocampal volumes were obtained by two raters, interrater reliability estimated, and the average data between the two raters used for subsequent analysis.

The interuncal distance was measured on the T1-weighted (500/20) transaxial section at the level of the suprasellar cistern. A measurement of the interparietal distance was also obtained on the same section by measuring between the outer edges of the parietal lobes through the interuncal line (Fig. 1). Measurements were made with a computer-generated transparent scale calibrated to 1.0 mm and were made blind to the subject's age, sex, and diagnosis. One rater measured all the interuncal distances, a second rater measured the interuncal distances on 10 randomly selected subjects, and an interrater reliability estimate was obtained. All subsequent analyses were done using the interuncal distance as measured by the first rater. As a control for brain size, these analyses were also done using the ratio of the interuncal distance to the interparietal distance. All measurements were corrected to real brain size by a magnification factor of 2.65. These measurements were used to analyze the relationship between the interuncal distance and the amygdala-hippocampal volume.

Results

The interclass coefficient between the two raters of the amygdala-hippocampal complex volume was .86 and .90 for the right and left amygdala-hippocampal volumes, respectively. The interclass correlation coefficient between the two raters for the interuncal distance measurements was .94; that for the interparietal distance was .81.

Total amygdala-hippocampal volume was not significantly correlated with the interuncal distance in control subjects ($r = -.38$, $P = .13$) (Fig. 2). The correlation between interuncal distance and interparietal distance was $r = .26$, $P = .31$.

for the control subjects; and $r = .02$, $P = .94$ for the Alzheimer disease patients. The MMSE scores of the Alzheimer disease patient group was not correlated with the interuncal distance ($r = -.26$, $P = .42$). MMSE was not correlated with the ratio of the interuncal/interparietal distance ($r = -.31$, $P = .32$).

Analysis of covariance was performed with the interuncal distance as the dependent variable, and age and diagnostic category as independent variables. Age had a significant effect ($F = 5.02$, $df = 1$, $P = .034$), but diagnosis did not ($F = 0.02$, $df = 1$, $P = .88$). Analysis of covariance was also performed with the interuncal/interparietal distance ratio as the dependent variable. Age had a significant effect ($F = 5.37$, $df = 1$, $P = .029$), but the diagnosis remained insignificant ($F = 0.01$, $df = 2$, $P = .93$) (see Fig. 3).

Discussion

Recent investigations have focused on MR imaging of the temporal lobe and the hippocampal formation, including anatomic (5–8), volumetric (9–13), and pathologic (13–23) studies. Interest has emerged concerning the interuncal measurement on axial MR scans as a possible reflection of hippocampal atrophy (1) and its correlation with age (2).

In the present study, the interuncal distance was insignificantly correlated with the amygdala-hippocampal volume. There are a number of possible explanations for this. The uncus is primarily occupied by the amygdaloid complex and it is possible that if the amygdala, the uncus portion of the hippocampus, and the uncus could be reliably distinguished from the rest of the hippocampus on MR images, a stronger correlation would be found. It is more likely that the interuncal distance is a better indicator of overall cranial size and of volume loss of the brain. Thus, the generalized brain atrophy, which occurs with normal aging, probably accounts for the strong correlation of interuncal distance with age. When controlling for age in our study, there was no significant correlation with any diagnostic category. Nor was there a significant correlation between the degree of dementia as assessed by MMSE scores and the interuncal distance in this group of Alzheimer disease patients.

Alzheimer disease is characterized by increased atrophy, particularly of the hippocampal formation, but the degree of atrophy in other than end-stage disease may overlap with normal age-re-

lated atrophy, at least within the limits discernible by present MR imaging. Because many of the interuncal distance values reported by Dahlbeck et al (1) for their Alzheimer disease patient group are much higher than those seen in our Alzheimer disease group, it is possible that they were studying a more advanced stage of the disease.

In conclusion, our study suggests that the interuncal distance measurement may not be useful for diagnosis in early Alzheimer disease. Furthermore, the interuncal distance did not correlate with the amygdala-hippocampal volume in our study, suggesting that it is not a specific marker of hippocampal atrophy.

References

1. Dahlbeck SW, McCluney KW, Yeakley JW, Fenstermacher MJ, Bonmati C, Van Horn G. The interuncal distance: a new MR measurement for the hippocampal atrophy of Alzheimer disease. *AJNR: Am J Neuroradiol* 1991;12:931–932
2. Doraiswamy PM, McDonald WM, Patterson LJ, et al. The interuncal distance as a measure of hippocampal atrophy: normative data on axial MR imaging. *AJNR: Am J Neuroradiol* 1993;14:141–143
3. Krishnan KR, Husain MM, Doraiswamy PM, et al. In vivo stereological assessment of caudate volume in man: effect of normal aging. *Life Sci* 1990;47:1325–1329
4. McKhann G, Drachman D, Folstein M, Katzman R, Price D, Stadlan EM. Clinical diagnosis of Alzheimer's disease: report of the NINCDS-ADRDA Work Group. *Neurology* 1984;34:939–944
5. Naidich TP, Daniels DL, Haughton VM, et al. Hippocampal formation and related structures of the limbic lobe: anatomic-MR correlation. I. Surface features and coronal sections. *Radiology* 1987;162:747–754
6. Naidich TP, Daniels DL, Haughton VM, et al. Hippocampal formation and related structures of the limbic lobe: anatomic-MR correlation. II. Sagittal sections. *Radiology* 1987;162:755–761
7. Bronen RA, Cheung G. MRI of the normal hippocampus. *Magn Reson Imaging* 1991;9:487–500
8. Bronen RA, Cheung G. Relationship of hippocampus and amygdala to coronal MRI landmarks. *Magn Reson Imaging* 1991;9:449–457
9. Jack CR, Gehring DG, Sharbough FW, et al. Temporal lobe volume measurements from MR images: accuracy and left-right asymmetry in normal persons. *J Comput Assist Tomogr* 1988;12:21–29
10. Jack CR, Twomey CK, Zinsmeister AR, Sharbough FW, Petersen RC, Cascino GD. Anterior temporal lobes and hippocampal formations: normative volumetric measurements from MR images in young adults. *Radiology* 1989;172:549–554
11. Jack CR, Sharbough FW, Twomey CK, et al. Temporal lobe seizures: lateralization with MR volume measurements of the hippocampal formation. *Radiology* 1990;175:423–429
12. Lencz T, McCarthy G, Bronen R, et al. The hippocampus in temporal lobe epilepsy: correlation of presurgical MRI volumetrics with post-surgical cell counts. *Epilepsia* 1990;31:667–668
13. Ashtari M, Barr WB, Schaul N, Boyerts B. Three-dimensional fast low-angle shot imaging and computerized volume measurement of the hippocampus in patients with chronic epilepsy of the temporal lobe. *AJNR: Am J Neuroradiol* 1991;12:941–947
14. Maertens PM, Machen BC, Williams JP, et al. Magnetic resonance imaging of mesial temporal sclerosis. *J Comput Assist Tomogr* 1987;11:136–139

15. Kuzniecky R, de la Sayette V, Ethier R, et al. Magnetic resonance imaging in temporal lobe epilepsy: pathologic correlations. *Ann Neurol* 1987;22:341-347
16. Heinz ER, Heinz TR, Radtke R, et al. Efficacy of MR versus CT in epilepsy. *AJNR: Am J Neuroradiol* 1988;9:1123-1128
17. Triulzi F, Franceschi M, Fazio F, Del Maschio A. Nonrefractory temporal lobe epilepsy: 1.5 T MR imaging. *Radiology* 1988;166:181-185
18. Press GA, Amaral DG, Squire LR. Hippocampal abnormalities in amnesic patients revealed by high resolution magnetic resonance imaging. *Nature* 1989;341:54-57
19. Brooks BS, King DW, El Gammal T, et al. MR imaging in patients with intractable complex partial epileptic seizures. *AJNR: Am J Neuroradiol* 1990;11:93-99
20. Squire LR, Amaral DG, Press GA. Magnetic resonance imaging of the hippocampal formation and mammillary nuclei distinguish medial temporal lobe and diencephalic amnesia. *J Neurosci* 1990;10:3106-3117
21. Jackson GD, Berkovic SF, Tress B, et al. Hippocampal sclerosis can be reliably detected by magnetic resonance imaging. *Neurology* 1990;40:1869-1875
22. Bronen RA, Cheung G, Charles JT, et al. Imaging findings in hippocampal sclerosis; correlation with pathology. *AJNR: Am J Neuroradiol* 1991;12:933-940
23. Bronen RA, Cheung G. MRI of the temporal lobe: normal variations, with special reference toward epilepsy. *Magn Reson Imaging* 1991;9:501-507