This information is current as of October 11, 2024.

MR angiographic demonstration of an intracranial aneurysm not seen on conventional angiography.

J T Curnes, M E Shogry, D C Clark and H J Elsner

AJNR Am J Neuroradiol 1993, 14 (4) 971-973
http://www.ajnr.org/content/14/4/971

MR Angiographic Demonstration of an Intracranial Aneurysm Not Seen on Conventional Angiography

John T. Curnes,[1] Mark E. C. Shogry,[1] David C. Clark,[1] and Henry J. Elsner[2]

Summary: A patient with documented subarachnoid hemorrhage underwent conventional angiography, which was negative. MR angiography performed immediately after the conventional angiogram demonstrated a 4-mm anterior communicating artery aneurysm. This finding was confirmed 1 week later with repeat angiography, and the aneurysm was clipped surgically.

Index terms: Magnetic resonance angiography (MRA); Aneurysm, magnetic resonance; Subarachnoid space, hemorrhage

In patients with documented subarachnoid hemorrhage, the "negative angiogram" occurs in up to 20% of cases (1). In addition to repeat angiography at 7 to 10 days, we have recommended magnetic resonance (MR) evaluation to detect occult pituitary apoplexy (2) or dural arteriovenous fistulas (3). We now report a case of an aneurysm documented by MR angiography

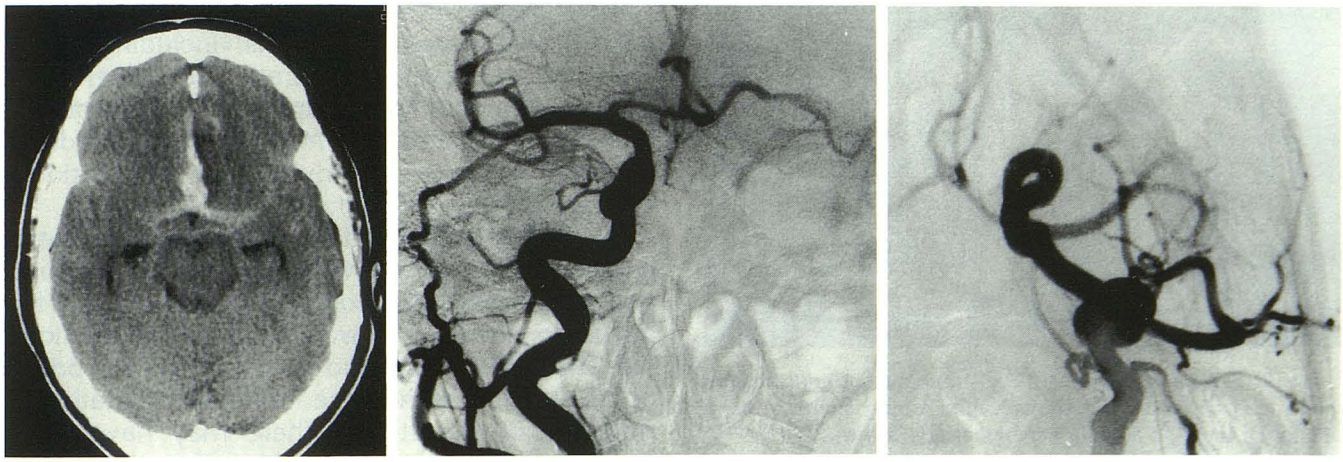

A B C

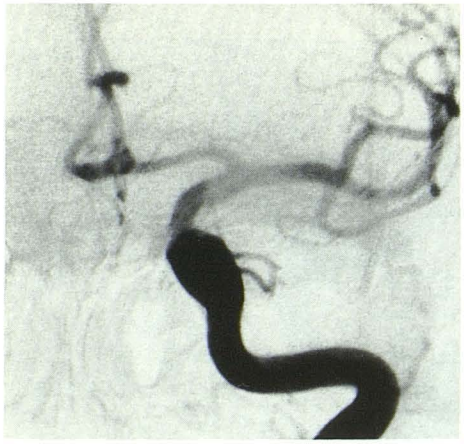

D

Fig. 1. *A*, Noncontrast computed tomography scan. Blood is present in the basilar cisterns, and a focal clot is seen in the anterior interhemispheric fissure.

B, Anteroposterior right common carotid artery angiogram with left cross-compression fails to reveal an anterior communicating artery aneurysm.

C, Left common carotid artery base view and *D*, oblique view, show splaying of the anterior cerebral arteries, but no aneurysm.

Received July 14, 1992; accepted August 21.

[1] Greensboro Radiology Associates, Box 13005, Greensboro, NC 27415. Address reprint requests to John T. Curnes.

[2] Guilford Neurosurgical Associates, 1200 N. Elm St., Greensboro, NC 27401.

AJNR 14:971–973, Jul/Aug 1993 0195-6108/93/1404–0971 © American Society of Neuroradiology

(MRA) immediately following a negative angiogram.

Case Report

A 58-year-old woman presented with sudden onset of the "worst headache of her life." Computed tomography scan showed subarachnoid blood with a focal clot in the interhemispheric fissure (Fig. 1A). Four-vessel angiography was performed, with special attention to the anterior communicating artery, using cross-compression on each carotid, and multiple oblique projections, including base views (Fig. 1B–1D). No aneurysm was seen. MRA performed within 1 hour of the angiogram showed a 4-mm aneurysm at the junction of the right anterior cerebral with the anterior communicating artery (Fig. 2). MRA was performed with a 1.5-T magnet (GE Signa, Milwaukee, WI) using a 3-D phase contrast technique, 23/7.3/20° (TR/TE/flip angle) with a velocity-encoding value of 30 cm/second. Sixty-four images were obtained in a slab 60-mm thick, using a matrix of 256 × 128 with 1.0 signals averaged. Acquisition time was 12:35. Eighteen projection images were obtained. The clot in the interhemispheric fissure was isointense, but splayed the A_2 segments of the distal anterior cerebral artery.

Repeat angiography 7 days later confirmed the MRA findings (Fig. 3). Retrospective analysis of the first angiogram failed to reveal the aneurysm. Surgery confirmed the aneurysm in the expected location, and the patient made a good recovery.

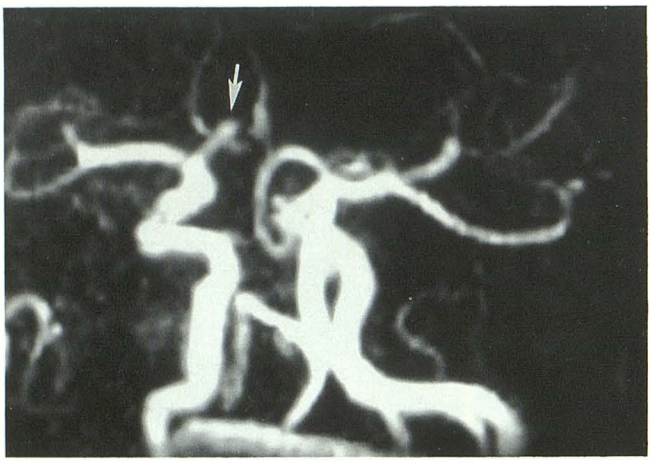

Fig. 2. 3-D phase contrast MRA (10° right posterior oblique) shows a 4-mm anterior communicating artery aneurysm at its junction of the right anterior cerebral artery (*arrow*).

Discussion

MRA holds great promise for evaluation of patients with vascular lesions, including aneurysms (4). However, comparative studies emphasize conventional angiography as the gold standard. In this case report, MRA was able to demonstrate an aneurysm invisible at conventional angiography.

We can only speculate on the reason the initial angiogram did not show the aneurysm. We may not have chosen the exact projection optimal for its demonstration. However, similar projections did show it the second time. At some point, contrast volume and time limitations dictate termination of the study. There may have been

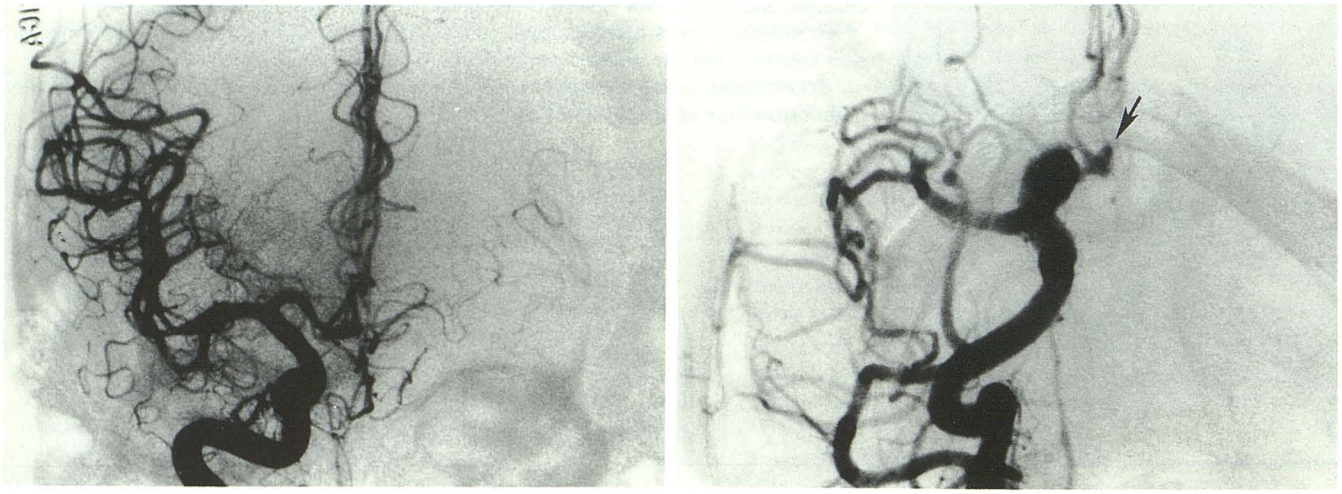

A B

Fig. 3. *A*, Right internal carotid artery anteroposterior angiogram performed 7 days later still shows no aneurysm. *B*, Right common carotid artery base view confirms anterior communicating artery aneurysm (*arrow*).

altered circulation within the aneurysm, either slow flow or clot, which prevented contrast opacification but changed (lysed) prior to MRA. Vital signs, including blood pressure, remained stable throughout conventional angiography and MR imaging. There may have been some alteration in hemodynamics within the aneurysm between the angiogram and MRA. Although it is unlikely that a clot lysed, a rise in blood pressure may have increased flow into the aneurysm, allowing detection on MRA.

A recent article by Owen (5) found MRA significantly more sensitive than conventional angiography in the detection of distal runoff vessels in patients with peripheral vascular disease. The ability of MRA to image flowing blood directly instead of relying on the temporal opacification of vessels by contrast from upstream injection removes the multiple variables of altered hemodynamics, injection rates and volumes, and filming projections.

Conventional angiography remains the technique of choice in initial evaluation of subarachnoid hemorrhage. MRA is limited in the detection of small (less than 3 mm) aneurysms and giant aneurysms with slow flow (4). A negative MR and MRA in the presence of subarachnoid hemorrhage should not preclude angiography; similarly, it is apparent that the MR and MRA evaluation of the patient whose angiogram is negative may reveal angiographically occult lesions.

References

1. Drayer BP. Diseases of the cerebral vascular system. In: Heinz ER, ed. *The clinical neurosciences.* Vol 4. New York: Churchill Livingston, 1984:336
2. Ostrov SG, Quencer RM, Hoffman JD, Davis PC, Hasso AN, David NJ. Hemorrhage within pituitary adenomas: how often associated with pituitary apoplexy syndrome? *AJNR: Am J Neuroradiol* 1989;10:503–510
3. DeMarco JK, Dillon WP, Halbach VV, Tsuruda JS. Dural arteriovenous fistulas: evaluation with MR imaging. *Radiology* 1990;175:193–199
4. Ross JS, Masaryk TJ, Modic MT, et al. Intracranial aneurysm: evaluation by MR angiography. *AJNR: Am J Neuroradiol* 1990; 11:449–455
5. Owen RS, Carpenter JP, Baum RA, et al. Magnetic resonance imaging of angiographically occult runoff vessels in peripheral arterial occlusive disease. *N Engl J Med* 1992;326:1577–1581