

Are your MRI contrast agents cost-effective?
Learn more about generic Gadolinium-Based Contrast Agents.



AJNR

Posttraumatic rhinolith.

J R Meyer and D J Quint

AJNR Am J Neuroradiol 1993, 14 (5) 1181-1182
<http://www.ajnr.org/content/14/5/1181>

This information is current as
of May 6, 2024.

Posttraumatic Rhinolith

Joel R. Meyer¹ and Douglas J. Quint²

Summary: Rhinolith, calcified concretion of a nidus within the nasal cavity, is a possible diagnosis for certain patients with densely mineralized lesions that appear benign and without bone destruction.

Index terms: Nose, computed tomography; Nasal cavity

Rhinolithiasis (nasal stones) results from calcification of an endogenous or exogenous nidus within the nasal cavity (1, 2). It is an unusual entity associated with any long-standing nasal obstruction. We report a case of a rhinolith diagnosed with computed tomography (CT), presumably related to prior trauma.

Case Report

A 67-year-old man with a history of traumatic nasal fracture 45 years before admission presented with chronic nasal obstruction of at least 8 to 10 years' duration. Physical examination was remarkable for deviation of the nose to the right with associated septal cartilage deviation to the right. In addition, a hard, slightly mobile mass was noted in the right middle meatus.

Sinus CT scan (Fig 1) demonstrated deviation of the anterior nasal septum to the right with a densely calcified mass in the right nasal cavity, which extended into the right middle meatus. A small amount of abnormal soft tissue and a small right inferior turbinate were seen in association with the mass, but no frank bone destruction was identified.

A functional septorhinoplasty was performed, and a rhinolith was removed from the right nasal cavity. Mucosal biopsies of the nasal septum were unremarkable.

Discussion

Rhinoliths are calcified concretions secondary to complete or partial incrustation of an exogenous or endogenous nidus within the nasal cavity (1). Rhinoliths have been classified as true or false

depending on whether a foreign body or endogenous material acts as a nidus (1, 2). Exogenous objects causing false rhinoliths include a variety of foreign bodies such as cherry pits, stones, pebbles, sand, fruits, peas, cloth, buttons, needles, seeds, beans, paper, parasites, wood, glass, or anything else that could pass through the anterior or posterior nares. Endogenous agents causing true rhinoliths include clotted blood, bacteria, leukocytes, bone fragments, or teeth (1, 2).

Common to both types of rhinoliths is the presence of nasal obstruction, which allows air currents to dry and concentrate the secretions associated with the nidus to the point where they precipitate and cause incrustation around the foreign body (1).

Patients typically present with symptoms of unilateral nasal obstruction often associated with a foul-smelling discharge. Diagnosis is typically accomplished by rhinoscopy, though, as in our case, the exact origin of the nasal cavity mass is often obscure. Sinusitis is considered a rare complication of rhinolithiasis and can make the diagnosis more difficult. In one report by Hunt et al, the diagnosis of a rhinolith was delayed 10 years, during which time the patient had sought medical care 40 to 50 times (3).

Although not observed in our case, rhinoliths may be associated with local pressure erosion on nearby bone. Therefore, the imaging modality of choice is CT, because subtle bone erosions easily can be missed by magnetic resonance.

In our patient, sinus CT was obtained to evaluate further an intranasal mass. The presence of homogeneous, smooth mineralization within a nasal cavity mass that appears nonaggressive (no associated bone destruction) is atypical for other partially calcified malignant masses, including

Received June 26, 1992; revision requested September 27, received October 14, and accepted November 11.

¹ Department of Radiology, Northwestern Memorial Hospital, Chicago, IL 60611.

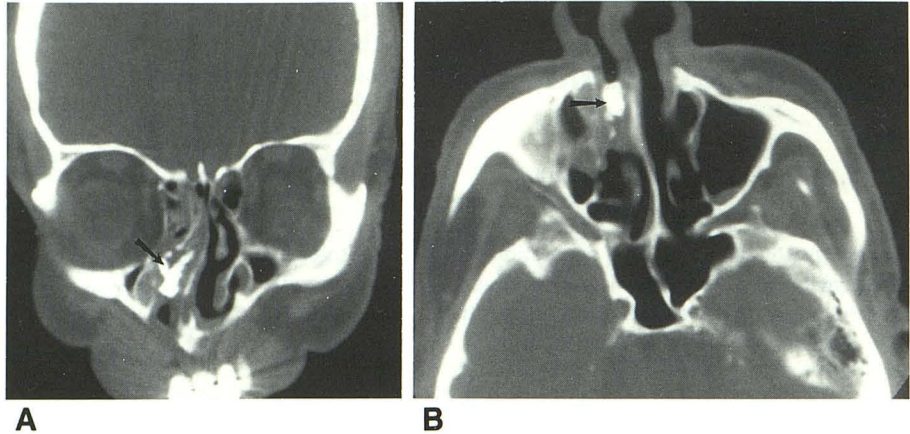
² Department of Radiology, University of Michigan Hospitals, Ann Arbor, MI 48109-0030.

Address reprint requests to Joel R. Meyer, MD, Department of Radiology, Olson Pavilion, Suite 3535, 710 North Fairbanks Ct, Chicago, IL 60611.

AJNR 14:1181-1182, Sep/Oct 1993 0195-6108/93/1405-1181 © American Society of Neuroradiology

Fig. 1. Nasal cavity rhinolith.

Coronal (A) and axial (B) sinus CT scans demonstrate a homogenous, high-attenuation rhinolith (arrows) within the right nasal cavity without associated bone destruction.



chondrosarcoma, osteosarcoma, or squamous cell carcinoma. The appearance of this lesion was also considered atypical for benign nasal cavity mass lesions, including nasal glioma, septal dermoid, and enchondroma.

In summary, in patients with a history of nasal trauma or in patients at risk for passing foreign bodies into the nasal cavity (eg, small children and institutionalized patients), the finding of a benign-appearing densely mineralized nasal cav-

ity lesion without associated bone destruction should suggest a diagnosis of rhinolith.

References

1. Harbin W, Weber AL. Rhinoliths. *Ann Otol Rhinol Laryngol* 1979;88:578-579
2. Abdel-Latif SM, Abdel-Hady S, Moustafa HM. Crystallographic study of rhinoliths. *J Laryngol Otol* 1979;93:1205-1209
3. Hunt WL, Cotton BP, Joseph DJ. Rhinoliths. Report of a case undiagnosed for ten years. *Arch Otolaryngol* 1966;83:256-259