AJNR

This information is current as of April 18, 2024.

Cystic acoustic schwannomas: MR characteristics.

E T Tali, W T Yuh, H D Nguyen, G Feng, T M Koci, J R Jinkins, R A Robinson and A N Hasso

AJNR Am J Neuroradiol 1993, 14 (5) 1241-1247
http://www.ajnr.org/content/14/5/1241

Cystic Acoustic Schwannomas: MR Characteristics

E. Turgut Tali,[1] William T. C. Yuh,[1] Hoang D. Nguyen,[1] Gao Feng,[1] Timothy M. Koci,[2] J. Randy Jinkins,[3] Robert A. Robinson,[4] and Anton N. Hasso[5]

PURPOSE: To evaluate the spectrum of MR characteristics of cystic acoustic schwannoma and to investigate its incidence. **METHODS:** We retrospectively reviewed the MR findings and clinical records of 16 patients with cystic acoustic schwannomas. In addition, the MR examinations of 411 consecutive patients referred for clinical suspicion of acoustic schwannomas were reviewed retrospectively to assess the incidence of acoustic schwannomas with cystic lesions arising from the internal auditory canal. **RESULTS:** Of the 16 acoustic schwannomas with MR evidence of intramural cysts, 11 tumors had single small cysts, and five had multiple intramural cysts of variable size. Intramural cysts in 11 of the 16 tumors exhibited higher signal intensity than that of cerebrospinal fluid; the remainder were isointense to cerebrospinal fluid on both T1- and T2-weighted images. All intramural cysts showed circumferential enhancement after contrast administration. Nine of the 16 cystic acoustic schwannomas also had MR evidence of extramural/arachnoid cysts. Six of the extramural/arachnoid cysts had epicenters away from the dural interface, and the other three cysts were broadly based against the dura. The incidence of cystic acoustic schwannomas was 11.3% and association with extramural/arachnoid cysts 7.5%. **CONCLUSION:** Our series suggests that cystic changes in acoustic schwannomas and the association with extramural/arachnoid cysts are not as rare as previously reported by other diagnostic methods. The high signal intensity of intramural cysts is probably related to necrotic material, blood, or colloid-rich fluid. The difference in the MR characteristics of extramural/arachnoid cysts associated with acoustic schwannomas and those of typical arachnoid cysts not associated with neoplasia may be related to higher protein and/or colloid contents secreted by the tumor. Most extramural/arachnoid cysts had epicenters between the tumor and brain, suggesting that the most likely mechanism of formation is peritumoral adhesions. It creates a pseudoduplication caused by the trapping of fluid between the leptomeninges and the mass, resulting in an acquired type of arachnoid cyst.

Index terms: Schwannoma; Temporal bone, neoplasms; Temporal bone, magnetic resonance; Ear, neoplasms; Ear, magnetic resonance

AJNR 14:1241–1247, Sep/Oct 1993

Acoustic schwannomas account for approximately 8% to 10% of primary intracranial tumors and 80% of cerebellopontine angle tumors (1, 2). These tumors may undergo cystic changes, frequently as microcysts, caused by degenerative changes within the tumors (3). Occasionally, these areas may coalesce to form larger cysts (4). Only a few cases of cystic acoustic schwannomas have been reported (3–9). In some instances, extramural/arachnoid cysts also may be associated with acoustic schwannomas (4); one study reported an incidence of 5% (3). However, the incidence of cystic acoustic schwannomas and their association with extramural/arachnoid cysts have not been documented. Our purpose was to investigate the spectrum of magnetic resonance

Received August 6, 1992; revision requested September 30, received October 16, and accepted November 3.

[1] Department of Radiology, The University of Iowa, College of Medicine, Iowa City, IA 52242. Address reprint requests to William T. C. Yuh, Department of Radiology, The University of Iowa Hospitals and Clinics, 200 Hawkins Dr, Iowa City, IA 52242.

[2] Department of Radiology, Harbor-University of California at Los Angeles, Torrance, CA 90509.

[3] Department of Radiology, University of Texas at San Antonio, San Antonio, TX 78284.

[4] Department of Pathology, The University of Iowa College of Medicine, Iowa City, IA 52242.

[5] Department of Radiology, Loma Linda University, Loma Linda, CA 92354.

AJNR 14:1241–1247, Sep/Oct 1993 0195-6108/93/1405–1241
© American Society of Neuroradiology

TABLE 1: MR of cystic acoustic schwannomas

No	Solid Component				Intramural Cyst				Extramural/Arachnoid Cyst				
	Size (mm)	T1[a]	T2[a]	Gd	Size (mm)	T1[b]	T2[b]	Gd[c]	Size (mm)	T1[b]	T2[b]	Gd[c]	EP
1	20 × 18 × 15	↓	↑	+	3 × 3 × 3 3 × 3 × 3 3 × 3 × 3	↑	↑	+	49 × 55 × 40	↑	↑	−	+
2	18 × 15 × 15	Iso	↑	+	3 × 3 ×3 22 × 22 × 22	↑	↑	+	50 × 20 × 25	↑	↑	−	+
3	37 × 37 × 37	Iso	↑	+	15 × 15 × 15 10 × 10 × 10 10 × 10 × 10	↑	↑	+	19 × 12 × 20	↑	↑	−	−
4	10 × 16 × 16	Iso	↑	+	3 × 3 × 3	↑	↑	+	50 × 38 × 20	↑	↑	−	+
5	30 × 10 × 20	↓	↑	+	11 × 11 × 11 3 × 3 × 3	↑	↑	+	20 × 10 × 20	↑	↑	−	−
6	23 × 30 × 24	↓	↑	+	5 × 5 × 5	↑	↑	+	33 × 35 × 30	↑	↑	−	+
7	20 × 18 × 25	↓	↑	+	29 × 9 × 9	↑	↑	+	25 × 20 × 30	↑	↑	−	+
8	30 × 31 × 40	Iso	↑	+	8 × 8 × 8 20 × 8 × 8	Iso	Iso	+	10 × 10 × 20	Iso	Iso	−	−
9	12 × 12 × 12	Iso	↑	+	10 × 10 × 10 8 × 8 × 8 5 × 5 × 5	↑	↑	+	25 × 25 × 25	↑	↑	−	+
10	25 × 31 × 25	Iso	↑	+	18 × 10 × 10	Iso	Iso	+					
11	48 × 40 × 45	↓	↑	+	20 × 20 × 20	Iso	Iso	+					
12	24 × 24 × 26	↓	↑	+	8 × 8 × 8	Iso	Iso	+					
13	15 × 19 × 20	↓	↑	+	6 × 6 × 6	↑	↑	+					
14	18 × 16 × 16	Iso	↑	+	3 × 3 × 3	Iso	Iso	+					
15	24 × 28 × 30	↓	↑	+	8 × 8 × 8	↑	↑	+					
16	8 × 12 × 8	Iso	↑	+	3 × 3 × 3	↑	↑	+					
F/U	17 × 23 × 15	Iso	↑	+	11 × 9 × 12	↑	↑	+					

Note.—Lesions smaller than 3 mm in diameter cannot be adequately measured. Therefore, they are not listed. EP = epicenter between the brain and the tumor; Iso = isointense; F/U = follow-up.

[a] The signal intensity compared with brain.

[b] The signal intensity compared with CSF.

[c] Peripheral enhancement.

(MR) characteristics and incidence of cystic acoustic schwannomas as well as their association with extramural/arachnoid cysts.

Materials and Methods

Sixteen patients with pathologically proved acoustic schwannoma and MR evidence of cyst formation were reviewed. There were eight men and eight women whose ages ranged from 26 to 82 years (median, 55 years). All 16 patients underwent both pre- and postcontrast MR studies including at least one T1-weighted (400–600/20–26/2 (repetition time/echo time/excitations)) and one T2-weighted (1500–2200/80–100) spin-echo pulse sequence with the section thickness ranging from 3 to 10 mm (10% gap in the higher-field unit). Immediately after the intravenous administration of 0.1 mmol/kg of gadopentetate dimeglumine (Magnevist; Berlex, Wayne, NJ), postcontrast axial and coronal MR images were obtained in both axial and coronal planes using identical T1-weighted imaging parameters. MR studies were performed with either a 0.5-T or 1.5-T superconductive unit. The MR examinations were retrospectively reviewed with special attention to the solid and cystic components of acoustic schwannomas, characteristics of cyst formation and location, and MR appearances, including signal intensity and contrast enhancement of both solid and cystic components. Patients' medical records also were reviewed with attention to clinical history, including initial symptoms such as hearing loss or vertigo, and, if available, surgical and pathologic findings, including the descriptions of the solid and cystic components and the fluid content of the cysts. An attempt was also made to correlate the operative and pathologic reports to the MR findings.

In addition, the MR examinations of 411 consecutive patients referred to the University of Iowa Hospitals and Clinics for clinical suspicion of acoustic schwannomas from 1986 to 1992 were retrospectively reviewed to determine the incidence of cystic acoustic schwannomas in this patient population.

Results

MR findings of the 16 cystic acoustic schwannomas are summarized in Table 1. All 16 tumors showed MR evidence of intramural cysts with

sizes ranging from 3 to 29 mm (Figs 1–4). Twelve tumors had small, solitary intramural cysts (Fig 1), and four had multiple intramural cysts of various sizes (Figs 2-4). Intramural cysts (68.8%) in 11 of 16 patients exhibited higher signal intensity than that of cerebrospinal fluid (CSF) on both T1- and T2-weighted images, whereas the remainder were isointense to CSF. All intramural cysts showed peripheral enhancement after intravenous contrast administration.

Nine of 16 tumors also had MR evidence of extramural/arachnoid cysts ranging in size from 10 to 55 mm (Figs 3 and 4). Six of nine cysts (67%) had little or no dural base with the epicenters directed away from the dura. These cysts were interposed between the tumor and cerebellum (Figs 3 and 4). The other three extramural/arachnoid cysts were based against the dura. The signal intensity of eight of the nine (89%) extramural/arachnoid cysts was higher than that of CSF on both T1- and T2-weighted images, whereas the remaining cyst had a signal intensity similar to that of CSF. The extramural/arachnoid cysts exhibited no peripheral contrast enhancement.

The solid tumoral component had a heterogeneous MR signal that was either isointense (eight of 16 tumors) or hypointense (eight of 16 tumors) to that of brain parenchyma on T1-weighted images and hyperintense (16 of 16 tumors) on T2-weighted images. All the solid components exhibited marked enhancement after intravenous contrast administration.

All 16 patients had surgical and pathologic confirmation of acoustic schwannoma. However, many surgical notes and pathologic reports were incomplete regarding the description of the cystic components and their fluid contents. Nevertheless, at surgery, seven patients were reported to have gross findings of extramural/arachnoid cysts containing either clear (three) or xanthochromic (four) fluid (Fig 3). The histopathologic records of five patients revealed evidence of intramural cysts (Figs 1, 2, and 5), whereas those of two patients revealed evidence of extramural/arachnoid cysts (Fig 4). Thirteen of 16 patients presented with gradual hearing loss, six with mildly impaired cerebellar function tests, and four with vertigo. One patient had ipsilateral seventh and fifth cranial nerve symptoms.

Based on the survey of 411 MR examinations performed at The University of Iowa Hospitals and Clinics to exclude the presence of acoustic schwannomas suspected on clinical grounds, 80 patients had acoustic schwannomas (19.5%). Of these, nine (11.3%) had intramural cystic components, and six of 80 (7.5%) had extramural/arachnoid cysts. Sixty-seven percent of cystic acoustic schwannomas had associated extramural/arachnoid cysts.

Discussion

Acoustic schwannomas are noncalcifying solid tumors that usually exhibit erosive enlargement of the internal auditory canal on plain films (5). Computed tomography (CT) shows these tumors to be isodense or hypodense to normal brain (5), and, after contrast administration, marked homogeneous enhancement is noted in 80% of the tumors (5, 10). CT cysternography is also helpful for anatomic delineation of the acoustic schwan-

Fig. 1. Acoustic schwannoma with pathologically proved solitary intramural cyst.

Postcontrast axial T1-weighted (*A*) (500/30) image shows a small left internal auditory canal mass with marked enhancement. A small intramural cyst with peripheral enhancement is also noted (*arrow*). Twenty-three-month follow-up postcontrast axial T1-weighted (*B*) (500/30) and T2-weighted (*C*) (3000/80) images show the growth of the acoustic schwannoma and enlargement of the intramural cyst (*B*). The intramural cyst exhibits higher signal intensity than that of CSF on the T2-weighted image (*C*) and marked peripheral enhancement on the postcontrast T1-weighted image (*B*).

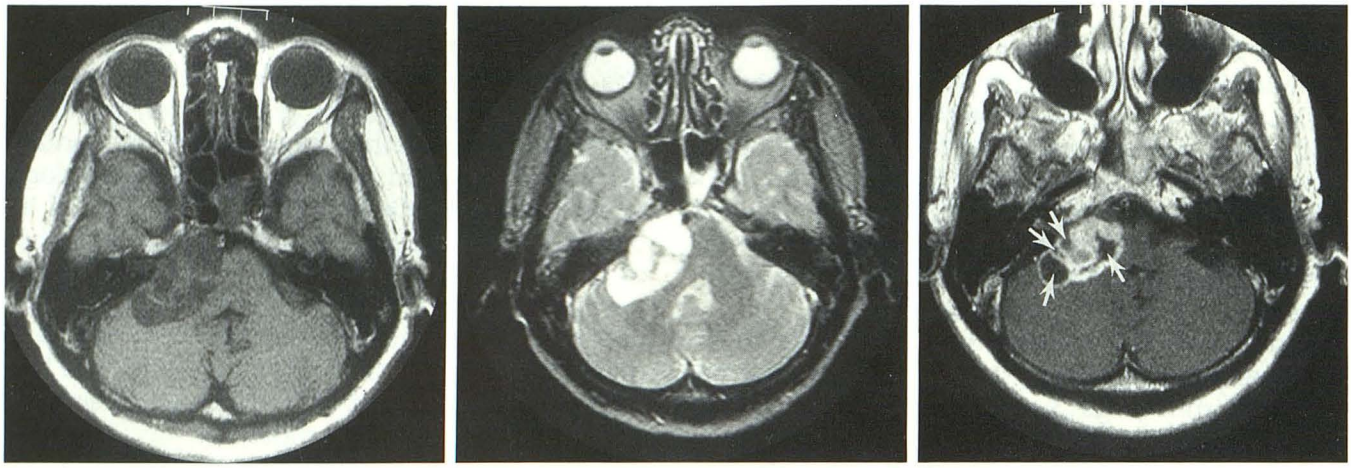

Fig. 2. Acoustic schwannoma with pathologically proved multiple intramural cysts.

Axial T1-weighted (*A*) (400/20), T2-weighted (*B*) (2000/100), and postcontrast T1-weighted (*C*) (400/20) images show a complex cystic mass in the right cerebellopontine angle and internal auditory canal. The solid component involves the entire internal auditory canal and part of the adjacent cerebellopontine angle and shows hypointensity to brain parenchyma on the T1-weighted image (*A*), mixed iso- and hyperintensity to brain parenchyma on T2-weighted imaging (*B*), and marked enhancement on the postcontrast T1-weighted image (*C*). Multiple intramural cysts are also noted (*A*) with higher signal intensity than that of CSF on both T1- (*A*) and T2-weighted images (*B*) and marked peripheral enhancement on the postcontrast T1-weighted image, (*C, arrows*).

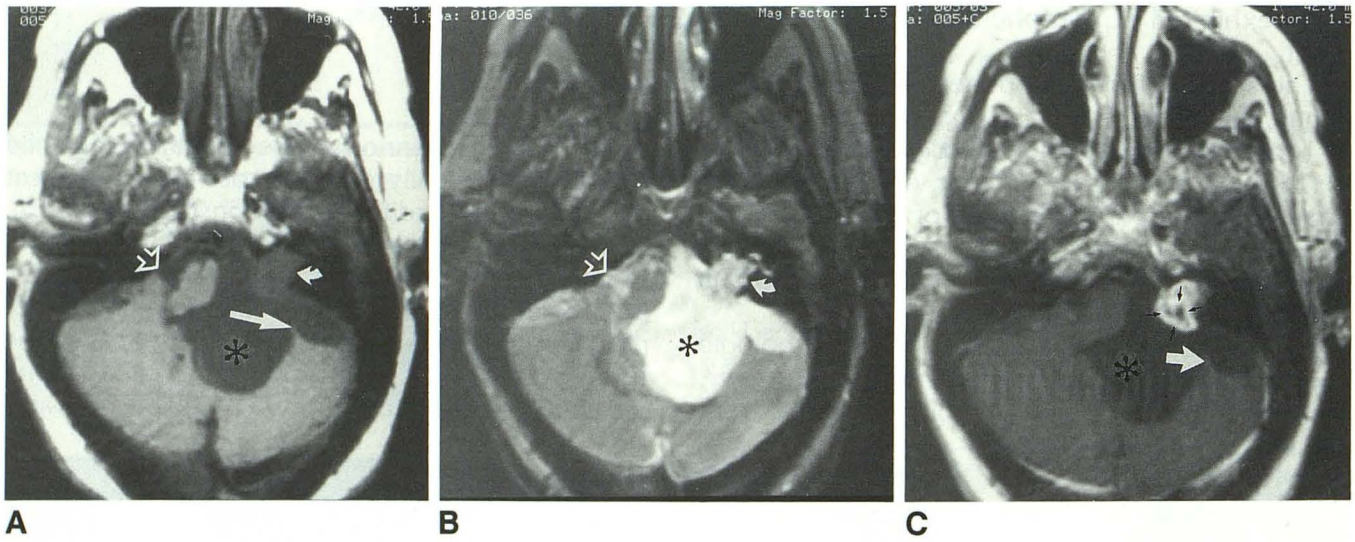

Fig. 3. Cystic acoustic schwannoma with surgically proved extramural/arachnoid cyst.

Axial T1-weighted (*A*) (350/15), T2-weighted (*B*) (2350/90), and postcontrast T1-weighted (*C*) (350/15) images show a large complex cystic mass of the left cerebellopontine angle and internal auditory canal. The solid component of the tumor is located mainly within the internal auditory canal and exhibits signal intensity lower than that of brain parenchyma on the T1-weighted image (*curved arrow*) and slightly higher than that of brain parenchyma but lower than that of CSF on the T2-weighted image (*curved arrow*). It also shows marked enhancement on the postcontrast T1-weighted image. An extramural/arachnoid cyst (*asterisk*) is noted between the mass and cerebellum. This cyst shows mild hyperintensity on the T1-weighted image relative to the CSF (*open arrow*), marked hyperintensity on the T2-weighted image relative to the CSF (*open arrow*), and no peripheral enhancement on the postcontrast T1-weighted image. It indents the brainstem and cerebellum to the right with sharp angles (*A* and *C, large arrows*) instead of displacing or compressing the parenchyma, as seen with typical arachnoid cysts. Note the small intramural cysts that show signal intensity higher than that of CSF on both T1- and T2-weighted images and also show postcontrast peripheral enhancement (*C, small arrows*).

noma (10). Recently, MR has proved to be superior to CT in the imaging of the posterior fossa and cerebellopontine angle, especially for internal auditory canal lesions, because of the lack of bone artifacts and direct multiplanar imaging capability. Acoustic schwannomas typically demonstrate high signal on T2-weighted MR images when compared with normal brain parenchyma

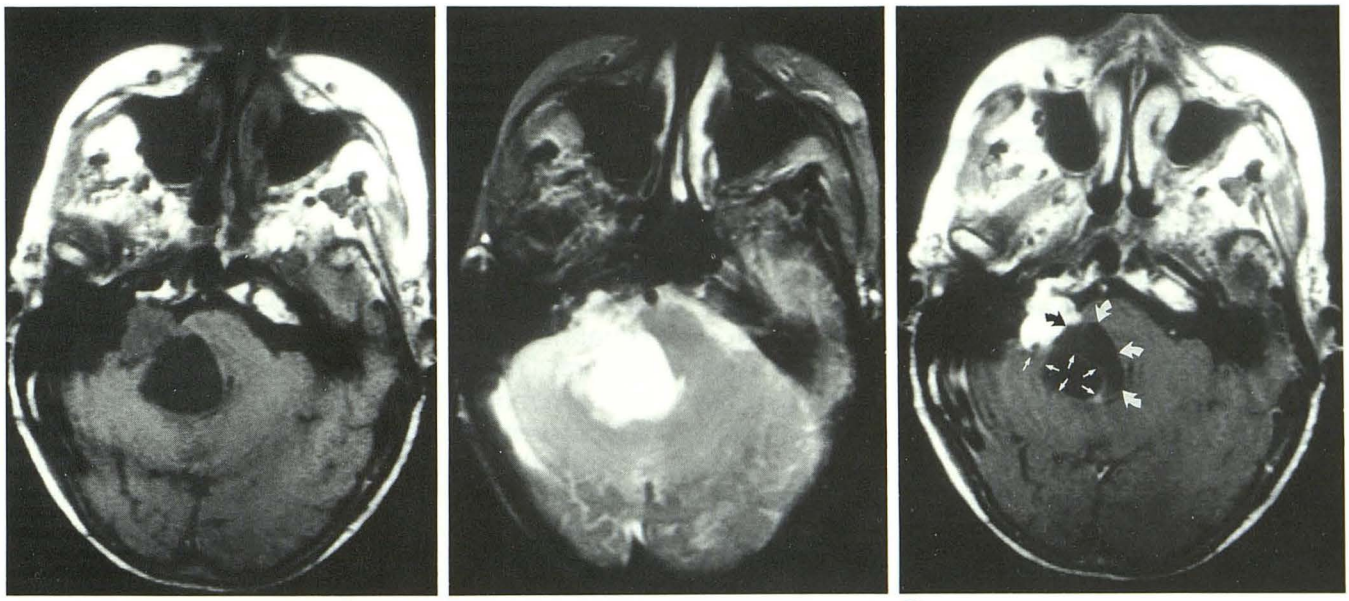

Fig. 4. Cystic acoustic schwannoma with pathologically proved extramural/arachnoid cyst.

Axial T1-weighted (*A*) (533/20), T2-weighted (*B*) (2350/90), and postcontrast T1-weighted (*C*) (533/20) images show a large complex cystic mass of the right cerebellopontine angle and internal auditory canal. The solid component of the tumor is located mainly within the internal auditory canal and exhibits signal intensity lower than that of brain parenchyma on the T1-weighted image and slightly higher than that of brain parenchyma but lower than that of CSF on the T2-weighted image, and marked enhancement on the postcontrast T1-weighted image. The nature of the cystic component (intramural or extramural) cannot be determined based on the precontrast studies (*A* and *B*). However, on the postcontrast study (*C*), an extramural/arachnoid cyst (*curved arrows*) is noted between the mass and the pons and cerebellum. This cyst shows mild hyperintensity on the T1-weighted image relative to the CSF, marked hyperintensity on the T2-weighted image relative to the CSF, and no peripheral enhancement on the postcontrast T1-weighted image. It indents the brain stem and cerebellum and displaces them to the left. In addition, there are multiple intramural cysts seen on the postcontrast image (*C, small arrows*), which show signal intensity higher than that of CSF on both T1- and T2-weighted images, and postcontrast peripheral enhancement.

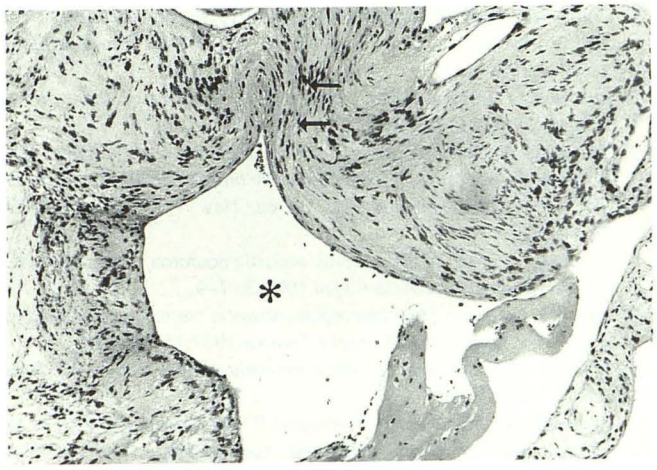

Fig. 5. Histologic section of cystic acoustic schwannoma.

Histologic section shows multiple intramural, irregularly shaped parenchymal cysts (*asterisk*) surrounded by neural tumor tissue. The tumor shows characteristics of a schwannoma as evidenced by spindle cells in a loose myxoid background. Note the focal parallel arrangement of nuclei and nuclear palisading (*arrows*) (hematoxylin and eosin, magnification ×300).

(11, 12). After paramagnetic contrast administration, they typically display marked and consistent early enhancement on T1-weighted images lasting 45 to 60 minutes (11, 12).

Occasionally, cystic changes within the tumor and extramural/arachnoid cysts may be associated with acoustic schwannomas. The incidence of cystic acoustic schwannomas is not documented. Hypothetically, cystic changes of acoustic schwannomas are thought to be related to necrosis within tumors (3). They are frequently microcystic but may coalesce to form larger cysts (macrocysts) (Figs. 1–3). As seen in our patients, the cysts varied in size, and enlargement was noted in one case in which there was a follow-up study (Fig 2). The high signal intensity of these intramural cysts on both T1- and T2-weighted images is probably related to tumoral necrotic material, blood by-products (observed in five cases), or colloid-rich fluid (observed in seven cases) (Figs 2 and 3). Peripheral enhancement surrounding the intramural cysts after contrast

administration may be related to the enhancement of the enveloping tumor tissue and/or inflammatory reaction to the fluid content of the cyst (Figs 2 and 3).

The MR signal characteristics of extramural/arachnoid cysts were similar to those of intramural cysts. Typically, the signal intensity of the arachnoid cyst is equal to that of CSF on both T1- and T2-weighted images, and the cysts show no peripheral enhancement after intravenous contrast administration. However, the extramural/arachnoid cysts in our study were morphologically different and exhibited different MR characteristics from those of typical arachnoid cysts.

The more usual central nervous system arachnoid cyst is thought to be a congenital anomaly of the developing subarachnoid space occurring in early intrauterine life. Typically, arachnoid cysts evolve from the splitting and/or duplication of the arachnoid membrane (13). These are benign lesions that characteristically are dural based and displace adjacent structures, thereby occasionally causing symptoms. More than half of the extramural/arachnoid cysts in our study were narrow based, with epicenters directed away from the dura, in contrast to the typical arachnoid cyst, which is usually broadly based against the dura. These atypical cysts appear to be sandwiched between the acoustic schwannoma and the dura or posterior fossa structures (Figs 4 and 5). They also may cause focal indentation of the brain parenchyma with sharp angles instead of displacing or compressing the parenchyma, as seen with typical arachnoid cysts.

Although the etiology of such extramural/arachnoid cysts is unknown, the mechanism may be similar to that described for the arachnoid cyst formation associated with meningiomas (14). These cysts may arise from the elevation and deformation of the leptomeninges by the enlarging tumors, which cause adhesions between the leptomeninges surrounding the tumor and the posterior fossa structures. This process creates a pseudoduplication of the arachnoid by trapping or pinching together two layers of arachnoid folds (4). Most of the extramural arachnoid cysts in our study had epicenters away from the dura and were sandwiched between the tumor and the brain, lending support for this mechanism. Another alternative mechanism is leakage of hemorrhagic debris from the tumor into the surrounding tissue, causing adjacent adhesions and forming a secondary extramural/arachnoid cyst.

The MR characteristics of the extramural/arachnoid cysts associated with cystic acoustic schwannomas are different from those of typical arachnoid cysts. The signal intensity of the extramural/arachnoid cysts is slightly higher than that of CSF on both T1- and T2-weighted images (Figs 4 and 5). This may be related to the colloid-rich content of the cystic component that was detected at surgery in seven of our patients. The growth of extramural cysts with colloid-rich fluid is unknown and may be related to three possible factors: 1) secretions from the tumor cells; 2) rich proteinaceous fluid trapped inside the cysts, which osmotically attracts water from the CSF through the arachnoid membrane; and 3) the cyst fluid being supplied by a tuft of choroid plexus protruding through the foramen of Luschka and trapped inside the cyst (7, 14).

In summary, the high signal intensity of intramural cysts is probably related to necrotic material, blood by-products, or colloid-rich fluid. The difference in the MR characteristics of extramural/arachnoid cysts associated with acoustic schwannomas and those of the typical arachnoid cyst may reflect a different mechanism of formation: higher colloid contents actively and passively secreted by the tumor. The most likely mechanism of extramural/arachnoid cyst formation is reactive peritumoral adhesions, resulting in an acquired type of extramural/arachnoid cyst.

References

1. Curati WL, Graif M, Kingsley DPE, King T, Scholtz CL, Steiner RE. MRI in acoustic neuroma: a review of 35 patients. *Neuroradiology* 1986;28:208–214
2. Russell DS, Rubinstein LJ. *Pathology of tumors of the nervous system*. 5th ed. Baltimore: Williams & Wilkins, 1989
3. Hasso AN. Acoustic schwannoma with arachnoid cyst. In: Hasso AN, Shakudo M, Chadrycki E, eds. *MRI of the brain III: neoplastic diseases. The Raven MRI teaching file*. 1st ed. New York: Raven, 1989: 102–103
4. Drapkin AJ, Rose WS. Multicystic acoustic neuroma. Case report and differential diagnosis. *Acta Radiol* 1989;30:7–9
5. Patel PJ, Kolawole TM. Case report: acoustic neuroma presenting as a cyst with fluid level. *J Comput Tomogr* 1987;11:383–384
6. Prakash GS. Multicystic acoustic neuroma (letter, comment). *Acta Radiol* 1990;31:112
7. Krassanakis K, Sourtsis E, Karvounis P. Unusual appearance of an acoustic neuroma on computed tomography. *Neuroradiology* 1981;21:51–53
8. Kuhn JR, Neely JG, Pollay M. Cystic cerebellar schwannoma. *Otolaryngol Head Neck Surg* 1985;93:570–572
9. Goodman RR, Torres RAA, McMurty JG III. Acoustic schwannoma and epidermoid cyst occurring as a single cerebellopontine angle mass. *Neurosurgery* 1991;28:433–436
10. Kingsley DPE, Thorton A, Furneaux C, King TT. Transmural passage of subarachnoid metrizamide into a cystic acoustic schwannoma of

the cerebellopontine angle: a diagnostic dilemma. *Neuroradiology* 1984;26:319–321

11. Stack JP, Ramsden RT, Antoun NM, Lye RH, Isherwood I, Jenkins JPR. Magnetic resonance imaging of acoustic neuromas: the role of gadolinium-DTPA. *Br J Radiol* 1988;61:800–805
12. Scroth W, Grodd L, Guhl L, Grauer M, Kiose U, Niendorf HP. Magnetic resonance imaging in small lesions of the central nervous system. Improvement by gadolinium DTPA. *Acta Radiol* 1987;28:667–672
13. Rengachary SS, Watanabe I. Ultrastructure and pathogenesis of intracranial arachnoid cysts. *J Neuropathol Exp Neurol* 1981;40: 61–83
14. Rengachary S, Batnitzky S, Kepes JJ, Morantz RA, O'Boynick P, Watanabe I. Cystic lesions associated with intracranial meningiomas. *Neurosurgery* 1979;4:107–114