

Generic Contrast Agents

Our portfolio is growing to serve you better. Now you have a *choice*.



[VIEW CATALOG](#)

AJNR

CT after intracranial intraarterial thrombolysis for acute stroke.

S L Wildenhain, C A Jungreis, J Barr, J Mathis, L Wechsler and J A Horton

AJNR Am J Neuroradiol 1994, 15 (3) 487-492

<http://www.ajnr.org/content/15/3/487>

This information is current as of May 8, 2025.

CT after Intracranial Intraarterial Thrombolysis for Acute Stroke

Sarah L. Wildenhain, Charles A. Jungreis, John Barr, John Mathis, Lawrence Wechsler, and Joseph A. Horton

PURPOSE: To determine the incidence, appearance, and clinical significance of lesions mimicking intraparenchymal hemorrhages on CT in patients treated with intracranial intraarterial thrombolysis for acute strokes. **METHODS:** Ten cases of acute stroke treated with direct intraarterial urokinase infusion were retrospectively reviewed. Clinical and radiographic findings before and after therapy were all evaluated. **RESULTS:** Six (60%) of the 10 patients showed areas of increased attenuation on CT shortly after thrombolytic therapy. The lesions were associated with clinical deterioration in two cases (20%); in these two cases the lesions persisted on CT for several days. The lesions were asymptomatic in two (20%) cases; the lesions cleared on CT within 24 hours in those two patients. In two (20%) patients, immediate clinical improvement was evident despite the radiodense areas. These lesions also cleared within 24 hours. CT Hounsfield unit measurements of four of the lesions revealed very high Hounsfield units in two lesions, only one of which was a symptomatic lesion. MR in two cases revealed residua of hemorrhage. **CONCLUSION:** Intraparenchymal areas of increased attenuation may be seen on the CT scans of patients after intraarterial thrombolysis. The density is often at least partially attributable to contrast extravasation. The lesions should not necessarily be interpreted as hemorrhage alone, especially in the absence of clinical deterioration. Rapid clearing may be a positive prognostic sign.

Index terms: Thrombolysis; Cerebral hemorrhage; Brain, computed tomography; Interventional neuroradiology, complications of

AJNR Am J Neuroradiol 15:487-492, Mar 1994

Direct local intraarterial urokinase thrombolysis for the treatment of acute stroke is being applied as a first-line therapy at some institutions (1-6) because the outcome of angiographically proved middle cerebral artery occlusion is poor with the traditional conservative management (1). Animal models of early reperfusion of occluded intracranial vessels have shown promising clinical improvements and reduction of infarct size (1, 7). Similar encouraging results have also been obtained by researchers in human stroke patients (4-6, 8-11). In addition to the obvious ischemic ramifications of a stroke, the stroke patient has an increased risk of potentially devastating intra-

cranial hemorrhage as a consequence of the ischemic event. That risk is theoretically increased by thrombolytic therapy (12, 13) and has been a relative impediment to trials of thrombolytic therapy. In this context, we have observed several patients who showed lesions on computed tomography (CT) after thrombolysis that appeared to represent severe intracranial hemorrhage. These lesions, however, had Hounsfield unit (HU) measurements higher than could be accounted for by blood alone, and in most cases were not associated with clinical deterioration after thrombolysis. In fact, some patients improved clinically despite the areas of increased attenuation. This paradoxical observation inspired us to examine further our experience with stroke patients treated with intraarterial urokinase to try to determine the nature of the lesions and their impact.

Materials and Methods

Ten patients presenting with acute internal carotid artery or middle cerebral artery distribution strokes were treated with intraarterial urokinase. Treatment was initiated within 8 hours of ictus (Table 1). All patients had CT scans before

Received January 18, 1993; accepted pending revision April 15; revision received June 3.

From the Departments of Radiology (S.L.W., C.A.J., J.B., J.M., J.A.H.), Neurological Surgery (C.A.J., J.A.H.), and Neurology (L.W.), University of Pittsburgh Medical Center.

Address reprint requests to Charles A. Jungreis, MD, Department of Radiology, Presbyterian University Hospital, Room D132, 200 Lothrop St, Pittsburgh, PA 15213.

AJNR 15:487-492, Mar 1994 0195-6108/94/1503-0487

© American Society of Neuroradiology

TABLE 1: Ten cases of stroke treated by direct intraarterial thrombolysis

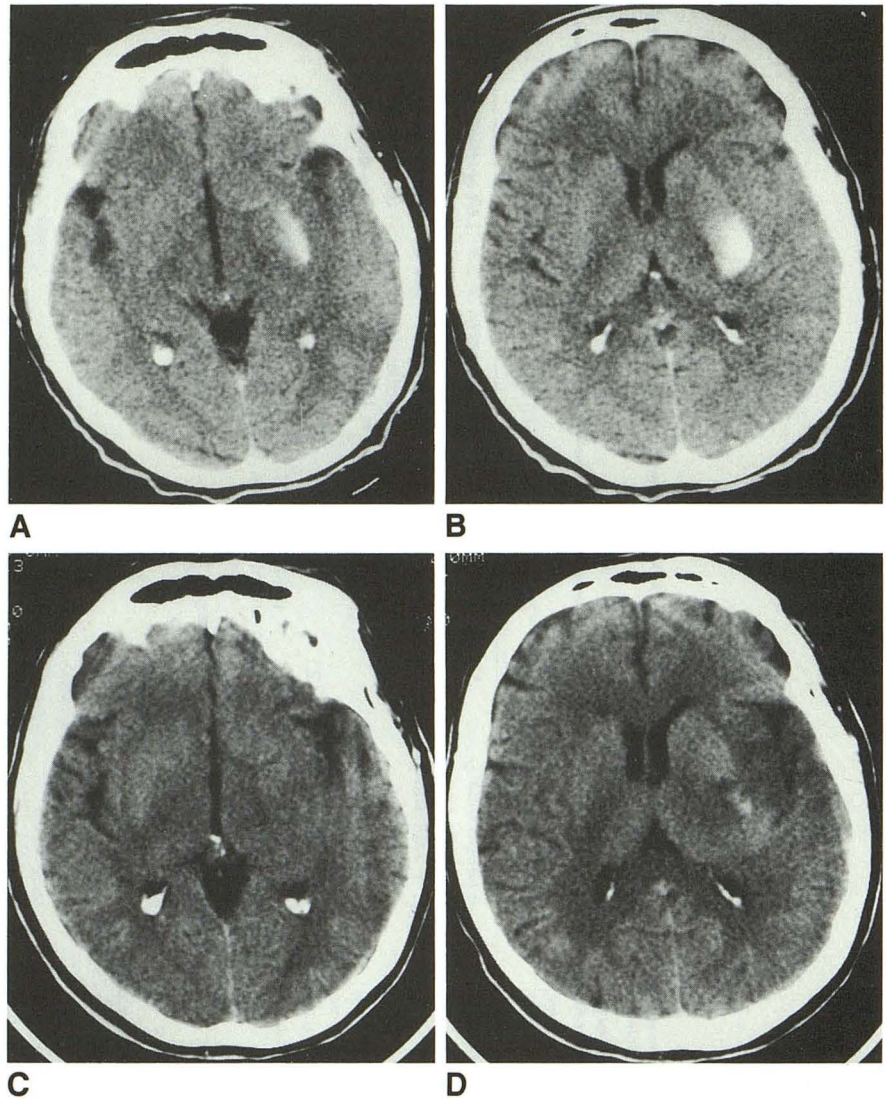
	Case in Order of Occurrence									
	1*	2	3	4	5	6	7	8	9	10
Age/sex	74/M	62/F	46/M	53/M	33/M	75/M	62/F	63/M	53/F	72/F
Delay of treatment after ic-tus (hours)	5	5¼	6½	3½	7½	7½	½	4	4	5½
Findings on angiogram	Left middle cerebral artery stenosis and occlusion	Left internal carotid artery origin stenosis and left middle cerebral artery occlusion	Right middle cerebral artery occlusion	Right middle cerebral artery occlusion	Saddle embolus left middle cerebral artery	Left internal carotid artery and middle cerebral artery occlusion	Left middle cerebral artery occlusion	Left middle cerebral artery occlusion	Right middle cerebral artery occlusion	Occluded left middle cerebral artery branches
Dose of urokinase (in thousands)	210	160	250	250	225	300	500	500	400	200
Clot lysis	Significant but rethrombosed	Near total	Main clot not lysed	Significant proximal but not branch clots	Complete, but slow flow persisted	Near total	Near total	Total	Near total	Total
Posttherapy CT density	No	Yes	Yes	No	No	Yes	No	Yes	Yes	Yes
Immediate clinical	No change	Slightly improved	No change	No change	Improved	Worse	Improved	Improved	Worse	Unchanged
Final clinical	Improved greatly (3 months)	Significantly improved (6 months)	Worse (multiple complications)	Improved (almost complete by 9 days)	Improved (normal by 18 days)	Slightly improved (by 16 days)	Improved (small residue by 7 days)	Improved	Moderately improved (by 16 days)	Improved, aphasia gone, paralysis re-mains

* Case previously reported by Jungreis (14).

TABLE 2: Patients with high-attenuation lesions on CT after urokinase thrombolysis

	Case					
	2	3	6	8	9	10
Postthrombolysis CT finding	Left basal ganglia + insula opacity with HU = 110-122	Dense right basal ganglia + uncus staining	4-cm left basal ganglia opacity + intraventricular hemorrhage, HU = 70s	Left basal ganglia opacity with lucency around it, HU = 30-40	Large parenchymal + subarachnoid opacities, HU = 184-170s	Left anterior cerebral artery region and parietal areas, HU = 50s-60s
Time of CT after urokinase (hours)	3	24	1	23	15	Immediate
Immediate clinical impact of urokinase	Improvement	Unchanged	Worsened	Improvement	Worsened	Unchanged
Time after detection for dense lesion to resolve by CT	22 hours	17 hours	9 days	24 hours	More than 4 days	16 hours
Magnetic resonance findings	Hemosiderin hemorrhagic infarct left middle cerebral artery	Subacute blood in caudate and anterior limb internal capsule				
Other comments		Subsequent complicated course, temporal lobectomy, had had prior balloon occlusion right internal carotid artery before stroke		If opacity occurred at time of urokinase it may have taken as long as 47 hours to resolve		

Fig. 1. Patient 2. Noncontrast axial CT. The images (A and B) obtained within 3 hours of thrombolytic therapy show an area of high attenuation (110 to 122 HU) in the left basal ganglia, the territory treated. A scan obtained 22 hours after thrombolytic therapy (C and D) shows dramatic resolution. There is some lucency presumably representing edema in the area. This patient had an excellent clinical outcome.



treatment. Contiguous axial sections were obtained from base to vertex. Section thickness was 3 mm in the posterior fossa and 10 mm in the supratentorial compartment. Thrombolytic therapy was not initiated in any patient with CT evidence of intracranial hemorrhage on presentation. All patients had posttreatment head CT scans within 24 hours of thrombolysis. Retrospectively, the data on the patients were reviewed including the presenting clinical deficits, the angiographic and CT findings, the time elapsed before therapeutic intervention, the dose of urokinase, the posttherapy imaging findings, and the clinical course (Table 1). No patients had died.

The therapeutic infusions were performed from a standard femoral angiographic approach via a microcatheter (Tracker-18, Target Therapeutics, Los Angeles, Calif) that was embedded into the clot (14). The urokinase (Abbokinase, Abbott Laboratories, North Chicago, Ill) was prepared in a concentration of 1000 U/mL. Urokinase injections were performed by hand and varied according to the fluoroscopic impression that the infusate was saturating

the region of interest without excessive reflux into nonoccluded branches. As fluoroscopic evidence of lysis occurred the microcatheter was advanced. The end point of treatment was either clinical improvement, angiographic cure, or when a total of 500 000 units of urokinase had been infused.

Results

Six patients (60%) had areas of increased attenuation on the posttreatment CT scans in the territory sustaining the ischemic event and thrombolytic therapy (Table 2). In two cases (cases 6 and 9) the appearance of the radiodense areas correlated with clinical deterioration, and in those, the lesions did not resolve until more than 4 days later. In two other cases (cases 2 and 8) there were lesions after treatment, but the patients were improved clinically (Fig 1). In these same two

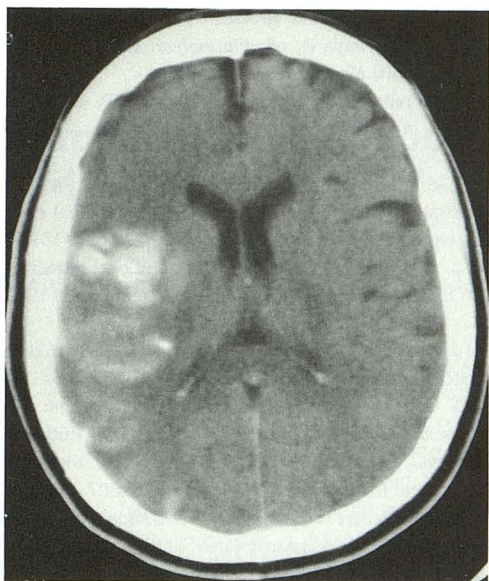


Fig. 2. Patient 9. Noncontrast axial CT. There is parenchymal and/or subarachnoid material of high attenuation (170 to 184 HU) in the treated territory of the right middle cerebral artery. The hounsfield units are too high to represent blood alone and are probably contrast mixed with blood. An initial decline in clinical status was followed by a significant clinical improvement.

cases, the lesions resolved on CT within 24 hours of their detection. In case 8 the first posttreatment CT was obtained 23 hours after thrombolysis at which time the radiodense lesion was first observed. On the follow-up scan at 48 hours, the density had resolved. Thus, it may have taken as long as 47 hours to resolve in case 8.

Hounsfield unit analysis in two cases (Cases 2 and 9) showed that the areas of increased attenuation measured 110 to 122 HU and 170 to 184 HU, respectively, values that are higher than would be expected for pure hemorrhages alone (Table 2). In case 2, the lesion was asymptomatic and cleared on CT within 24 hours. Case 9 had a severe symptomatic worsening at the time the lesion became apparent, and the lesion was not resolved after 4 days. In case 9, not only was high attenuation material present intraparenchymally, but it was also present in a pattern suggesting subarachnoid (or very superficial gyral) collections (Fig 2).

In case 6, areas of increased attenuation were also found in the ventricular system and were associated with clinical decline. The lesions did not clear until 9 days later.

In two cases (cases 2 and 3) magnetic resonance scans performed later suggested the presence of blood products in the area of the CT

lesions. One of these case (case 2) was one that had a clinical improvement.

Discussion

CT-detectable areas of increased attenuation suggesting parenchymal hemorrhage after local intraarterial thrombolysis developed in more than half the cases (60%) in this series. Other investigators have reported a somewhat lower frequency of hemorrhagic complications after intraarterial thrombolysis. Zeumer et al found hemorrhages in 14% (one of seven) of cases of vertebrobasilar lysis (6), del Zoppo et al had an incidence of 20% (4 of 20) hemorrhages (2), and Hacke et al had 9.3% hemorrhage (3). Levine and Brott suggest the incidence of postthrombolysis hemorrhage may be increased if the delay between ictus and therapy is greater than 3 hours (1), and other authors have found a similar time-related hemorrhage incidence (4, 15). It is apparent that most of our patients were not treated until after 4 hours. The two who were treated within 3.5 hours of ictus had no hemorrhagic complications. Other factors such as urokinase dose, patient age, infarct size, and degree of lysis may play a role in hemorrhagic complication incidence.

Intracranial hemorrhage has been a dread complication of thrombolytic therapy. Levine suggests that such complications have nearly a 50% mortality (1). Nevertheless, in almost all reported series of patients treated with thrombolysis there were CT findings suggesting hemorrhage, especially in the ipsilateral basal ganglia, in patients who were asymptomatic (1, 2, 4, 6, 8, 11, 12, 15). None of these authors record how quickly the lesions cleared. Such asymptomatic "hemorrhages" are of interest in that they refute the long standing dogma that hemorrhagic conversion is an extremely poor prognostic sign. Furthermore, the high HU values indicate that at least some of the density is contrast, and very rapid resorption is possible. The presence of blood products on magnetic resonance scans does indicate a component of hemorrhage. Probably the patients who suffered deterioration had frank intraparenchymal hemorrhages. However, many of the areas of high attenuation apparently represent contrast that has entered the because of a damaged blood-brain barrier. The extremely rapid clearance would support such a theory; it is most unusual for hemorrhage to clear so quickly.

In conclusion, we have observed intraparenchymal areas of high attenuation on CT immediately after intraarterial thrombolytic therapy for treatment of acute stroke that clear more rapidly than might be expected for a typical hemorrhagic infarct. Such densities are composed of contrast material (or contrast material plus blood) and do not invariably herald clinical deterioration. In fact, rapid clearance on CT may be a good prognostic sign. We recognize that this is only a small number of patients and that firm conclusions should be viewed with caution. Certainly, further study is warranted.

References

1. Levine SR, Brott TG. Thrombolytic therapy in cerebrovascular disorders. *Prog Cardiovasc Dis* 1992;34:235-262
2. Del Zoppo GJ, Ferbert A, Otis S, et al. Local intra-arterial fibrinolytic therapy in acute carotid territory stroke: a pilot study. *Stroke* 1988;19:307-313
3. Hacke W, Zeumer H, Ferbert A, Bruckmann H, Del Zoppo GJ. Intra-arterial thrombolytic therapy improves outcome in patients with acute vertebrobasilar occlusive disease. *Stroke* 1988;21:1216-1222
4. Mori E, Tabuchi M, Yoshida T, Yamadori A. Intracarotid urokinase with thromboembolic occlusion of the middle cerebral artery. *Stroke* 1988;19:802-812
5. Brott T. Thrombolysis and stroke in clinical practice: past, present and future. In: Sawaya R, ed. *Fibrinolysis and the central nervous system*. St. Louis: Mosby, 1990;189-197
6. Zeumer H, Freitag HJ, Grzyska U, Neuzig HP. Local intraarterial fibrinolysis in acute vertebrobasilar occlusion. *Neuroradiology* 1989;31:336-340
7. Benes V, Zambramski JM, Boston M, Puca A, Spetzler RF. Effect of intra-arterial fibrinolytic agents on autologous arterial emboli in the cerebral circulation of rabbits. *Stroke* 1990;21:1594-1599
8. Theron J, Courtheoux P, Alachkar F, et al. Local intraarterial fibrinolysis in the carotid territory. *AJNR Am J Neuroradiol* 1989;10:753-765
9. Sakurai J, Egashira T, Yamada Y, Nomura N. Lysis of middle-cerebral artery occlusion with alteplase. *Lancet* 1991;338:1206-1207
10. Frink FJ, Ostrach LH. Streptokinase in the treatment of an acute cerebral embolus-A case report. *Angiology* 1990;41:66-69
11. Del Zoppo GJ, Zeumer H, Harker L. Thrombolytic therapy in stroke: possibilities and hazards. *Stroke* 1986;17:575-607
12. Bruckmann H, Ferbert A. Putaminal hemorrhage after recanalization of an embolic MCA occlusion treated with tissue plasminogen activator. *Neuroradiology* 1989;31:95-97
13. Lyden PD, Madden MD, Clark WM, Sasse KC, Zivin JA. Incidence of cerebral hemorrhage after treatment with TPA or streptokinase following embolic stroke in rabbits. *Stroke* 1990;21:1589-1593
14. Jungreis CA, Wechsler LR, Horton JA. Intracranial thrombolysis via a catheter embedded in the clot. *Stroke* 1989;20:1578-1580
15. Sloan MA. Thrombolytic therapy in experimental focal cerebral ischemia. In: Sawaya R, ed. *Fibrinolysis and the central nervous system*. St. Louis: Mosby, 1990;177-188