

Are your **MRI contrast agents** cost-effective?

Learn more about generic **Gadolinium-Based Contrast Agents**.



FRESENIUS  
KABI

caring for life

# AJNR

## **Location of hand function in the sensorimotor cortex: MR and functional correlation.**

C Rumeau, N Tzourio, N Murayama, P Peretti-Viton, O Levrier, M Joliot, B Mazoyer and G Salamon

*AJNR Am J Neuroradiol* 1994, 15 (3) 567-572

<http://www.ajnr.org/content/15/3/567>

This information is current as of April 18, 2024.

# Location of Hand Function in the Sensorimotor Cortex: MR and Functional Correlation

C. Rumeau, N. Tzourio, N. Murayama, P. Peretti-Viton, O. Levrier, M. Joliot, B. Mazoyer, and G. Salamon

**PURPOSE:** To determine the location of hand function in the sensorimotor cortex using MR and positron emission tomography imaging studies. **METHODS:** Anatomic and physiological methods were used for this study. Anatomic study was based on the MR analysis of 22 subjects. The length of the sensorimotor cortex was measured in the axial and sagittal planes. Physiologic study was based on the positron emission tomography studies of 4 subjects. Each of the studies was correlated with MR. **RESULTS:** We found that the superior genu of the central sulcus corresponds to hand function in the sensorimotor cortex. This level may prove useful for any clinical correlations or for surgery. **CONCLUSIONS:** From this study, the hand function area in the sensorimotor cortex is easily understood with its characteristic shape in axial MR scan. The comparison of MR and positron emission tomography data clearly show anatomic correlations. This may be applied to the functional mapping of the pathologic studies in the sensorimotor cortex regions.

**Index terms:** Magnetic resonance, experimental; Positron emission tomography (positron emission tomography); Brain, magnetic resonance; Brain, anatomy

*AJNR Am J Neuroradiol* 15:567-572, Mar 1994

Magnetic resonance (MR) imaging is one of the most effective studies used to analyze the detailed configuration of the cerebral cortex. Single-photon emission computed tomography (SPECT) and positron emission tomography (PET) scan techniques, through determination of regional variations of the cerebral blood flow, allow assessment of cortical areas activated during the performance of specific sensorimotor activities. Anatomically, the sensorimotor area constitutes a rather easily identifiable structure located around the central sulcus, between the pre- and postcentral sulci. The precentral gyrus is limited by the precentral sulcus and the central sulcus. The postcentral gyrus is limited by the central sulcus and the postcentral sulcus. It displays a

small degree of individual variation. This restricted definition considers the sensorimotor area as limited to the precentral gyrus and postcentral gyrus. The present study analyzes both anatomic and functional points of view. The purpose of this study was to determine the location of hand function in the sensorimotor cortex by correlating MR and positron emission tomography imaging.

## Materials and Methods

### *Anatomic Study*

**MR Acquisitions.** Twenty-two healthy adult volunteers (19 to 51 years old) were examined in 0.5-T or 1.5-T MR scanners. All were right-handed and had no history of neurologic disease. To maintain strictly the orbitomeatal plane during the examination, the head was immobilized against a suitable head support with adhesive tape. MR scanning was performed in two steps. In the first step, the reference marks of the anterior and posterior commissures were identified by doing sagittal T1-weighted sequences centered on the midline. In the second step, 19 contiguous sagittal planes with a 7-mm-thick section and 16 contiguous axial and coronal planes with a 7-mm-thick section were obtained orthogonal to the sagittal plane. The MR scans were acquired as inversion recovery (2000/500/2 [repetition time/echo time/excitations]), inversion recovery time 21, with an image matrix size 256 × 256 mm.

---

Received November 17, 1992; accepted pending revision February 8, 1993; revision received April 14.

From the Department of Neuroradiology, Hospital La Timone, Marseilles, France (C. R., N. M., P. P.-V., O. L., G. S.); and the Service Hospitalier Frédéric Joliot et Groupe d'Imagerie Neurofonctionnelle, S. H. F. J., CEA, Orsay, and Hôpital R. Debre, CHU Bichat, Université Paris VII, Paris, France (N. T., M. J., B. M.)

Address reprint requests to Pr G. Salamon, CHU La Timone, Bd Jean Moulin, 13385 Marseille Cedex 5, France. Fax: (33) 91 85 83 17

*AJNR* 15:567-572, Mar 1994 0195-6108/94/1503-0567

© American Society of Neuroradiology

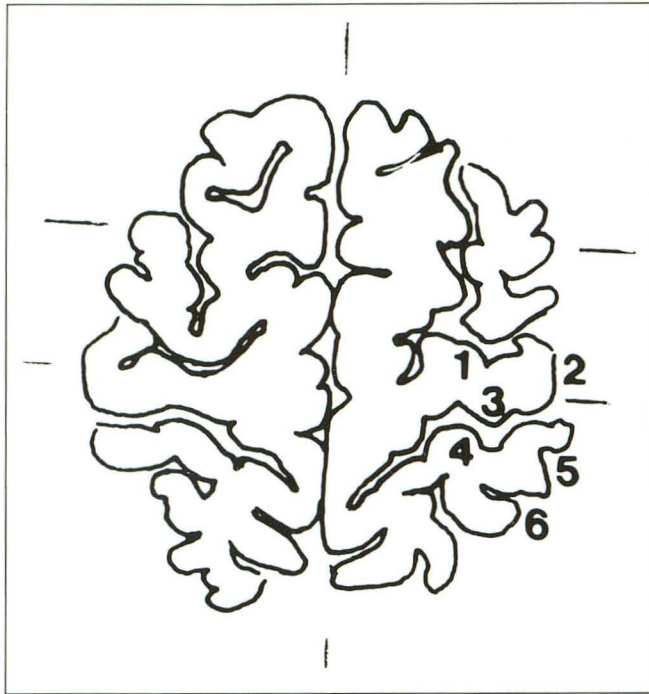
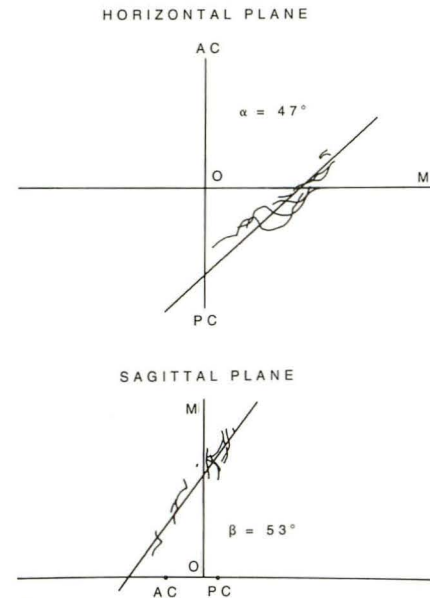


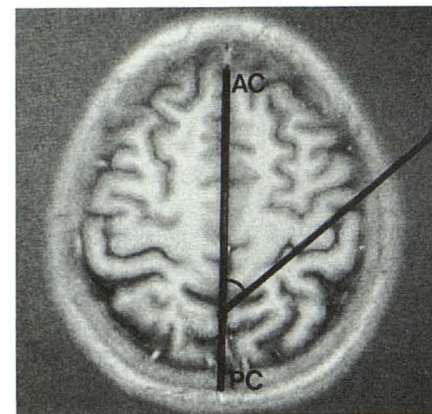
Fig. 1. Segmentation of the profiles of sensorimotor cortex in the axial plane. The length of each segment was measured in the whole series of transparent drawings. 1 indicates precentral sulcus; 2, superficial part of the precentral gyrus; 3, precentral gyrus (depth of the central sulcus); 4, postcentral gyrus (depth of the central sulcus); 5, superficial part of the postcentral gyrus; and 6, postcentral sulcus.

For every MR plane, identification of the sulci was determined by experienced neuroradiologists. All the structures identified were referenced according to the commissural plane.

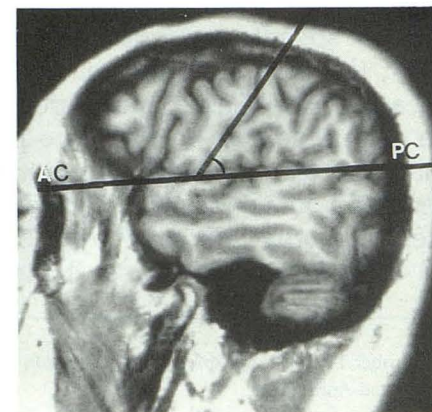
*Sensorimotor Cortex Morphologic Quantification.* As shown in Fig 1, the contours of the left sensorimotor cortex were divided into six segments: 1) precentral sulcus, 2) surface of precentral gyrus, 3) frontal slope of precentral gyrus, 4) parietal slope of postcentral gyrus, 5) surface of postcentral gyrus, and 6) postcentral sulcus. The widths of all the segments included in the whole series of sections for each subject were measured on enlarged pictures in the axial and sagittal planes using a Hewlett Packard 9830 A computer, connected to a Hewlett Packard 9864 A x-Y plotter. The widths obtained were checked against those of a brain directly measured by a curvometer that followed the surface of the brain. The total length of the sensorimotor cortex was calculated by summing up the lengths of the six segments included in either axial or sagittal sections. The motor cortex was defined as the sum of segments 1, 2, and 3 because it is necessary to take into account the deeper part of the motor cortex. Following this same reasoning, the sensory cortex was defined as the sum of segments 4, 5, and 6 to take into consideration both the superficial and the deeper part of the sensory cortex.



A



B



C

Fig. 2. The axis of the central sulcus in axial and sagittal planes in one case.

A, On the axial plane, the axis forms a frontal facing open angle of  $47^\circ$  with anterior commissure-posterior commissure (AC-PC). On the sagittal plane, this angle measures  $53^\circ$ , and is open toward the occipital pole. B, MR on axial plane showing the measurement of the angle. C, Angle measurement on sagittal MR.

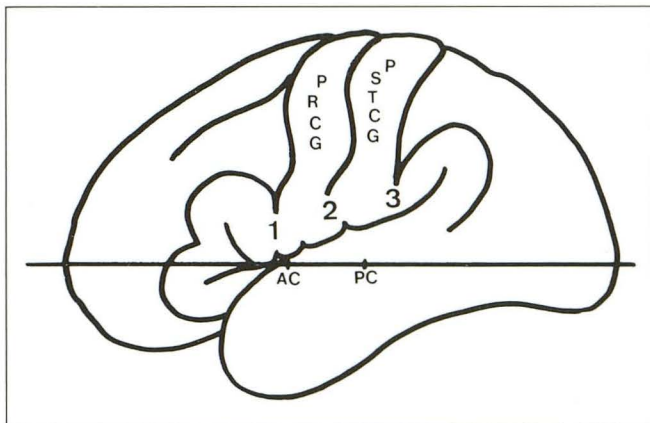


Fig. 3. The location of the opercular region and anterior commissure-posterior commissure line. 1 indicates frontal operculum; 2, Rolandic operculum; 3, parietal operculum; PRCG, precentral gyrus; PSTCG, postcentral gyrus; AC, anterior commissure; and PC, posterior commissure.

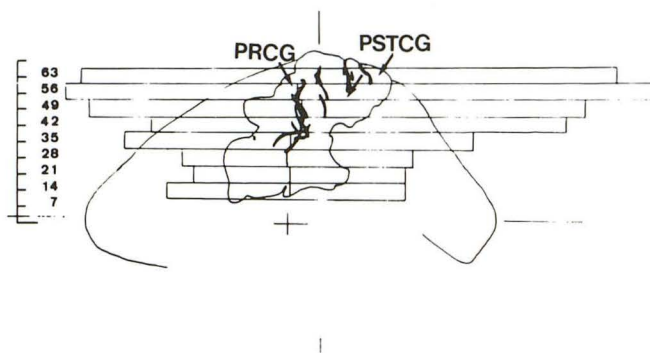


Fig. 4. Sagittal view of the brain showing the projection of sensorimotor area and central sulcus. The lengths of the profiles of the unfolded sensorimotor area are also shown to demonstrate that the unfolded sensorimotor cortex exceeds the anteroposterior length of the brain between +49 and +63 mm from anterior commissure-posterior commissure line.

#### Functional Study

A functional study was done on four healthy right-handed volunteers 21 to 28 years old. The axial MR and PET images were acquired on a plane parallel to the orbitomeatal line. The exact position of the head was systematically controlled during each MR or PET scan examination. The study was approved by the French Atomic Energy Ethics Committee and the Ethics Committee of the French National Institute and Medical Research.

**MR Acquisitions.** MR scan with T1-weighted sequences (650/30) was acquired parallel to the orbitomeatal plane with 3 mm thick.

**PET Acquisitions.** Regional cerebral blood flow images were acquired using the TTV03 time-of-flight PET system, which provides seven 9-mm-thick sections, 12 mm apart with a 7-mm in-plane resolution. Before blood flow studies a 100 Mevents "transmission" scan was obtained using a germanium-68 source rotating around the patients. This data set is used to correct the cerebral blood flow scan for

the autoattenuation of the 511 keV gamma rays in the subject's head. It is also used to reconstruct "transmission" images that are in fact equivalent to low contrast computed tomography (CT) scans and that were used to match the PET and the MR coordinate systems.

Cerebral blood flow experiments consisted of repeated intravenous bolus injections of 50 mCi of oxygen 15-labeled water (1, 2). For each injection, data were acquired in the time span of 2 minutes. For each subject the experimental protocol included six injections with a constant 20-minute delay between two injections. Subjects were kept with their eyes closed and their ears plugged; no order was given except to relax. Two conditions were alternated: "rest" and "vibration" of the fingers using a vibrator operating at 130 Hz (3). Vibration was started at least 30 seconds before the water-labeled injection and lasted 2 minutes. Subjects were told not to grasp the vibrator, but instead to let the experimenter gently maintain their fingerpads in contact with the vibrator. After each cerebral blood flow acquisition, data were read from a disk and a single scan (7 axial sections) was reconstructed that started at the arrival of the radioactivity in the brain (identified as the time of a sharp rise in the total number of counts registered by the tomograph) and that lasted for 80 seconds. Emission (cerebral blood flow) and transmission (attenuation) PET images were reconstructed using the same size, 128 × 128 with a 2-mm-square pixel size. Reconstruction was performed using a backprojection algorithm and a 5 mm<sup>-1</sup> cutoff frequency Hanning filter that translates in a 7-mm in-plane resolution at image center. Image processing was performed on Microvax II computers coupled to Ramtek 9465 graphic workstations.

**Image Analysis.** The image analysis procedure that was designed to use MR individual studies and to match anatomical (MR) and functional (PET) images has been described elsewhere (4, 5). Briefly, after conversion to the same format, PET and MR images were superimposed by aligning two sets of isodensity contours.

First, MR axial sections were converted to PET image size (128 × 128, 2 mm-square pixel size). The identification of section levels between the two modalities was checked using the PET transmission images and the corresponding MR sections and superimposing isodensity contours corresponding to the skin defined on MR and on transmission sections. Adequacy was visually checked and was found satisfactory in all cases. As a complementary check, these isodensity contours were also displayed on the cerebral blood flow images.

For each condition, cerebral blood flow sections were first normalized by dividing each section pixel value by the whole brain pixel mean value. This normalization procedure was used to remove global flow variations from one study to another. Activation detection was then completed using a difference image obtained by the subtraction of the normalized image at rest from the normalized image under vibration. To assess the relationship between the activation locus and the central sulcus, the central sulcus was drawn on the corresponding MR section, and then copied and registered onto the PET difference image.

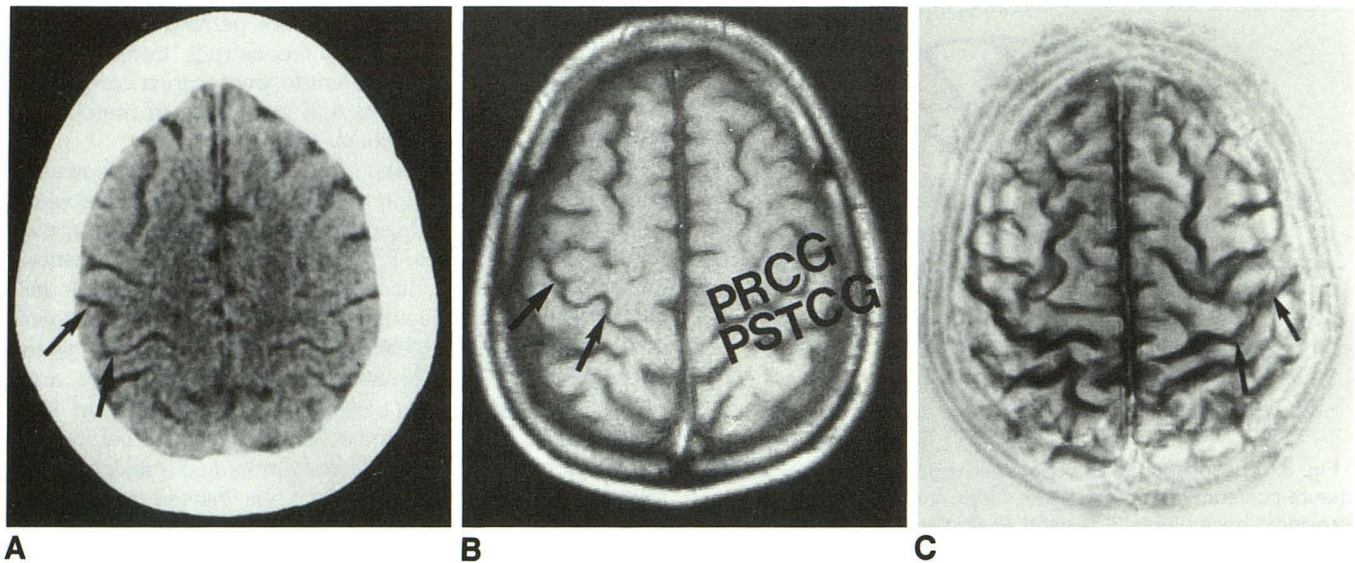


Fig. 5. Characteristic sigmoidal shape of the upper central genu. *A*, CT section. *Arrows* show on the right side central sulcus at this level. *B*, MR at the same level on T1-weighted image (*arrows* on right side). At left side, *PRCG* indicates precentral gyrus and *PSTCG*, postcentral gyrus. *C*, Surface image according to Katada's technique (19). *Arrows* on the left side on central sulcus at the hand level.

TABLE 1: Mean sensorimotor cortex length in axial MR sections (22 volunteers)

Level	Section Distance from Anterior Commissure-Posterior Commissure (mm)	Sensorimotor Cortex Length (mm)
11	+ 77	57
10	+ 70	157
9	+ 63	206
8	+ 56	219
7	+ 49	190
6	+ 42	152
5	+ 35	116
4	+ 28	109
3	+ 21	99
2	+ 14	81
1	+ 7	56

## Results

### Anatomic Results

The central sulcus projected on the axial plane formed a frontal-open angle whose mean value was  $50^{\circ} 65 \pm 4^{\circ} 11$ . Sagittally, the projection formed an occiput-open angle of  $48^{\circ} \pm 4^{\circ}$ . Thus, over the two planes sensorimotor cortex projects obliquely, forming similar angles (Fig 2).

Upwardly, the increment of the distances separating the frontal, rolandic, and parietal opercula from anterior commissure–posterior commissure reflected the ascending obliquity of the sylvian fissure. Most frequently, the frontal operculum was located at +7 mm from anterior commissure–posterior commissure, the rolandic opercu-

lum at +14 mm, and the parietal one from +21 mm to +35 mm (Fig 3). The projections of the opercular portion of central sulcus were quite constant. On the contrary, the projections of this sulcus in the paracentral lobule displayed wide dispersion.

The central sulcus, also described as the superior and the inferior genu (6), has two curves. The lower part of the sensorimotor cortex corresponded to the projection of the inferior genu, and the upper part to the superior genu. Figure 4 shows the homogeneity of the superior and inferior genu. The superior genu of the central sulcus appears on the higher CT and MR sections (Fig 5) as a sigmoidal-shaped structure, a characteristic that renders it easily identifiable.

Table 1 indicates the mean length of the SMC for each of the 7-mm-thick contiguous brain sections on the axial and sagittal planes for 22 subjects. On the sections done between +49 and +63 mm from the anterior commissure–posterior commissure reference planes, the mean lengths were the longest, attaining 219 mm.

At these levels, the unfolded sensorimotor cortex was 26% longer than the bicommissural axis. This feature was even more evident when the length of the unfolded sensorimotor cortex was referred to the section length at the same level (Fig 4).

Axially, as represented in the sections at +7 and +14 mm from the basal reference line, the cortex of the precentral gyrus was more predom-

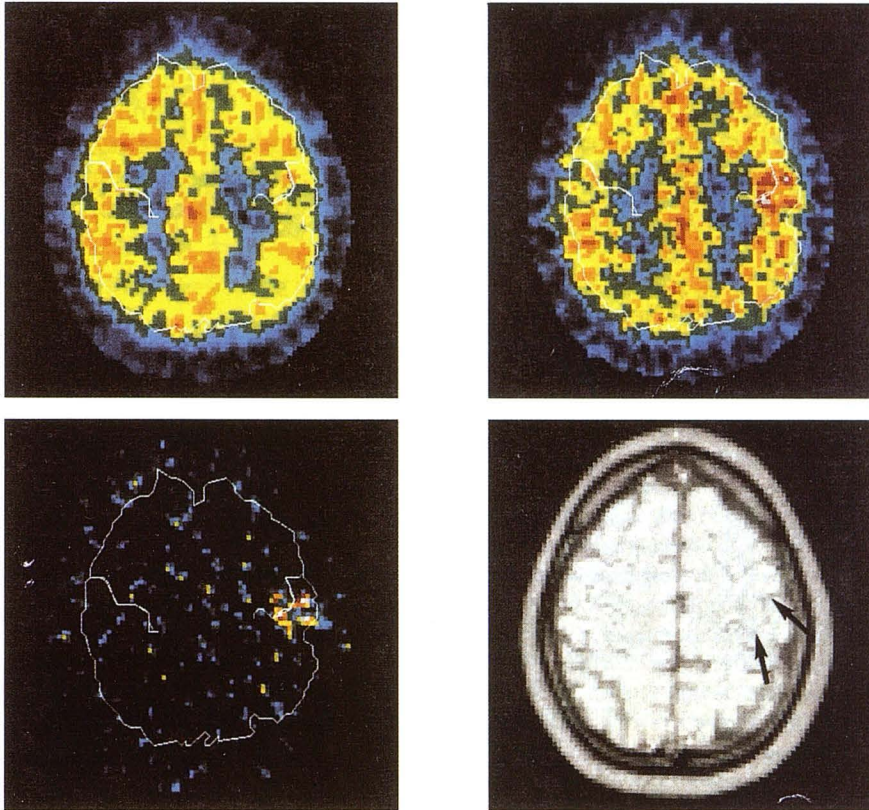


Fig. 6. Typical example of anatomico-functional location of the sensorimotor cortex.

*Upper left*, PET regional cerebral blood flow at rest.

*Upper right*, PET regional cerebral blood flow during hand vibration (right fingers) at the same level.

*Lower left*, individual difference image, vibration minus rest shows the activation spot and its relationship with RS as defined on the MR section.

*Lower right*, Corresponding 9-mm MR section at the same level as PET scan. Arrows point out the typical sigmoidal shape of the upper central flexure where the PET scan activation zone was observed.

inant than the cortex of the postcentral gyrus. This paradoxical condition is apparent only because it simply expressed the inclination of the section with respect to the sylvian fissure. In fact, if the lengths of the parietal and rolandic opercula are compared, a value of 3.01 mm is obtained, demonstrating a net predominance of the parietal operculum. This finding confirms a classic anatomic observation stressing the predominance of the postcentral gyrus at the operculum, in contrast to the predominance of the precentral gyrus at the paracentral lobule (6).

### Functional Results

The congruence of the functional images obtained with PET with the MR sections performed at the same level demonstrated a strict coincidence between the zone of increased blood flow resulting from the vibratory stimulation of the contralateral palm of the hand and the typical sigmoidal shape of the upper flexure of the central sulcus. This is well shown in Fig 6. This sharp correspondence of in vivo morphologic and functional results allowed us to establish that the sigmoidal image found in the upper genu of the central sulcus, appearing in both CT and MR axial

sections, represents the functional area of the hand.

### Discussion

It is clinically important to be able to recognize accurately the projection of the central sulcus. An understanding of the sensorimotor region is fundamental in studies of cortical hemiplegia and in the research of epilepsy. The ability to recognize the motor cortex is also important because this may affect presurgical planning and/or the embolization of lesions located in and around the motor region.

### Anatomic Aspect

The projection of cortical sulci has been greatly researched (7–9). The proposed proportional system of identification is a landmark in identifying the motor region and central sulcus in relation to the projection of a commissural system (7, 8). There are three lines of reference in this system: 1 axial line passing through the anterior and posterior commissures and 2 lines perpendicular to these points.

Numerous anatomic studies have been devoted to the length of the cortex of the motor region

and on the projection of the central sulcus (10). However, these studies are difficult to compare because the slopes of one measurement of numbers obtained on a cadaver and those obtained in vivo are different.

Recent publications (11, 12) have demonstrated the anatomic complexity of the cerebral sulci. Table 1 depicts the study of 22 cases in which the length of the sensorimotor cortex is measured at 11 different levels above the commissural line. It is surprising to note that the length of the sensorimotor area at the level of hand projection has a measurement of 22 cm. This size matches the image of the homunculus of Penfield and Rasmussen (13).

Over the external aspect of the hemisphere we have demonstrated the exact coincidence of "central genu" with the longest dimensions of the unfolded sensorimotor cortex, thus confirming a classic anatomic description (that considers the cortical indentation forming the genu as a localized increment of the cortical volume). In comparing the projection areas of the genu and the longest projections of the sensorimotor cortex with the functional projections of Penfield's homunculus on the external surface, we believe that the inferior genu corresponds to the projection area of the face and the upper genu to that of the hand.

### Functional Aspect

Numerous PET studies using 15-oxygen-labeled water bolus injections have dealt with hand sensory and motor activation. Fox's work in 1987 (3) gave for the first time the coordinates in the Talairach system of the projection site of the cutaneous vibration of the fingers pads in the opposite hemisphere cortex in 8 healthy volunteers. Using a similar approach, three other publications (14–16) described the activation foci projections from 4.8 to 6 cm above the anterior commissure-posterior commissure plane, which we have shown on our anatomic study to be the region of the longest mean length, corresponding to the central genu. The right-left and anteroposterior coordinates gave the sigmoidal shape at the projection site.

Three other PET studies gave the location of the hand activation projections but in a purely qualitative way (16–18). Our study, choosing the central genu for hand regions as the center of the PET section for vibration studies, confirmed in each subject the anatomofunctional correlation.

On the axial plane, the longest dimensions of the cortex correspond to the upper genu and is functionally related to the hand. The corresponding PET scan confirms our in vivo anatomical findings (Fig 6). The upper genu constitutes an important folding pattern of the sensorimotor cortex, representing the functional projection area of the hand.

### References

1. Herscovitch P, Markham J, Raichle ME. Brain blood flow with intravenous  $H_2^{15}O$ . *J Nucl Med* 1983;24:782–798
2. Raichle ME, Martin WRW, Herscovitch P, et al. Brain blood flow measured with intravenous  $H_2^{15}O$ . II: Implementation and validation. *J Nucl Med* 1983;24:790–798
3. Fox PT, Burton H, Raichle ME. Mapping human somatosensory cortex with positron emission tomography. *J Neurosurg* 1987;67:34–43
4. Salamon G, Tzourio N, Murayama N, Lévrier O, Orssaud C. Individual MRI mapping of the cerebral cortex for PET scan. *J Comput Assist Tomogr* 1993, in press
5. Petit L, Orssaud C, Tzourio N, Salamòn G, Mazoyer B, Berthoz A. PET study of voluntary saccadic eye movements in man: basal ganglia thalamo-cortical system and cingulate cortex involvement. *J Neurophysiol* 1993; in press
6. Dejerine J. *Anatomie des centres nerveux*. Tome 1. Paris: Masson, 1985
7. Talairach J, Szikla G. *Atlas d'anatomie stéréotaxique du télencéphale. Etudes anatomoradiologiques*. Paris: Masson, 1967.
8. Talairach J, Tournoux P. *Coplanar stereotaxic atlas of the human brain*. New York: Georg Thieme, 1988.
9. Schaltenbrand G, Bailey P. *Introduction to stereotaxis with an atlas of the human brain*. Stuttgart: Georg Thieme, 1959.
10. Ebeling U, Steinmetz H, Huang Y-X, Kahn T. Topography and identification of the inferior precentral sulcus in MR imaging. *AJR Am J Roentgenol* 1989;153:1051–1056
11. Duvernoy HM. *Le cerveau humain. Surface, coupes sériées tridimensionnelles et IRM*. Paris: Springer Verlag, 1992
12. Ono M, Kubik S, Abernathy CD. *Atlas of the cerebral sulci*. Stuttgart: Georg Thieme, 1990.
13. Penfield W, Rasmussen T. *The cerebral cortex in man. A clinical study of localization of function*. New York: Macmillan, 1952:56–61.
14. Chollet F, Dipiero V, Wise RSJ, Brooks DJ, Dolan RJ, Frackowiak RSJ. The functional anatomy of motor recovery after stroke in humans: a study with positron emission tomography. *Ann Neurol* 1991;29:63–71
15. Colebach JG, Deiber MP, Passingham RE, Friston KJ, Frackowiak RSJ. Regional cerebral blood flow during voluntary arm and hand movement in human subjects. *J Neurophysiol* 1991;65:1392–1401
16. Meyer E, Ferguson SG, Zatorre RJ, et al. Attention modulates somatosensory cerebral blood flow response to vibrotactile stimulation as measured with positron emission tomography. *Ann Neurol* 1991;29:440–443
17. Grafton ST, Woods RP, Mazziotta JC, Phelps ME. Somatotopic mapping of the primary motor cortex in humans: activations studies with cerebral blood flow and positron emission tomography. *J Neurophysiol* 1991;66:735–743
18. Grafton SG, Mazziotta JC, Woods RP, Phelps ME. Human functional anatomy of visually guided finger movements. *Brain* 1992;115:567–587
19. Katada K. MR imaging of brain surface structures: surface anatomy scanning (SAS). *Neuroradiology* 1990;32:439–448