

Generic Contrast Agents

Our portfolio is growing to serve you better. Now you have a *choice*.



FRESENIUS
KABI

[VIEW CATALOG](#)

AJNR

Correlation of pressure measurements with angiographic characteristics predisposing to hemorrhage and steal in cerebral arteriovenous malformations.

A M Norbash, M P Marks and B Lane

This information is current as
of May 9, 2025.

AJNR Am J Neuroradiol 1994, 15 (5) 809-813
<http://www.ajnr.org/content/15/5/809>

Correlation of Pressure Measurements with Angiographic Characteristics Predisposing to Hemorrhage and Steal in Cerebral Arteriovenous Malformations

Alexander M. Norbash, Michael P. Marks, and Barton Lane

PURPOSE: To determine whether there is a physiologic explanation for the predisposition of patients with certain angiographic characteristics to symptoms of hemorrhage and steal. **METHODS:** Superselective transcatheter feeding arterial pressure and mean arterial pressure measurements were obtained before embolotherapy in 32 patients with cerebral arteriovenous malformations. Pressures were correlated with previously described angioarchitectural characteristics predisposing to hemorrhage and steal. These included size of the arteriovenous malformation, feeding artery length, venous drainage pattern, and angiomatous change. **RESULTS:** The feeding arterial pressure and feeding arterial pressure/mean arterial pressure ratios were significantly decreased in patients with angiomatous change. Feeding arterial pressure and feeding arterial pressure/mean arterial pressure ratios progressively decreased as lesions went from peripheral, to mixed, to central venous drainage. A trend for lower feeding arterial pressure was also demonstrated with greater feeding pedicle length. A statistically significant correlation could not be demonstrated between feeding arterial pressure or feeding arterial pressure/mean arterial pressure ratios and size of the arteriovenous malformation, hemorrhage, or symptoms of steal. **CONCLUSIONS:** Feeding arterial pressure measurements help provide a physiologic basis for the relationship between certain angiographic characteristics and hemorrhage and steal symptoms in patients with arteriovenous malformation.

Index terms: Arteriovenous malformations, cerebral; Brain, pressure; Brain, hemorrhage; Arteries, flow dynamics; Angiography

AJNR Am J Neuroradiol 15:809–813, May 1994

The patient with an arteriovenous malformation may have a variety of symptoms; those associated with the most significant morbidity and mortality are caused by hemorrhage and steal (1–4). Various treatments have been used for arteriovenous malformations, including embolotherapy, radiation therapy, and surgery (5–12). All of these therapies have associated risks, and morphologic criteria have been proposed to help assess the risks of treatment in some cases (15,16). More recently, analysis of arteriovenous malformation architecture has been directed to-

ward identifying characteristics that may predispose a patient to hemorrhage or steal (17–22).

Previous analysis of untreated patients with arteriovenous malformation by our group has demonstrated increased risk of hemorrhage with central venous drainage, increased risk of hemorrhage with intranidus aneurysms, and decreased risk of hemorrhage with angiomatous change (18). Transcortical arterial recruitment by the arteriovenous malformation from adjoining vascular territories has been denoted *angiomatous change* (18). Steal symptoms are thought to occur when surrounding brain parenchyma is deprived of blood flow by the arteriovenous malformation. These symptoms have been shown to correlate positively with angiomatous change, increasing arteriovenous malformation size, and peripheral venous drainage (18).

Recent work has attempted to correlate intraoperative feeding arterial pressures with fre-

Received February 9, 1993; accepted pending revision April 26; revision received August 9.

From the Department of Radiology, Stanford University Medical Center, Stanford, Calif.

Address reprints requests to Michael P. Marks, MD, Department of Radiology, Stanford University Medical Center, Stanford, CA 94305–5105

AJNR 15:809–813, May 1994 0195-6108/94/1505–0809

© American Society of Neuroradiology

quency and severity of hemorrhage in arteriovenous malformations (23). These feeding arterial pressures, and by inference arteriovenous malformation nidus pressures, were found to be higher in patients who had bled and in patients with small arteriovenous malformations (≤ 3 cm). During the course of subselective angiographic catheterization and embolotherapy, transmural manometric evaluation of vascular branches may be performed (24,25). Our study was designed to provide a physiologic explanation for correlations previously shown by our group between elements of arteriovenous malformation angioarchitecture and bleeding or steal symptoms by evaluating transcatheter arteriovenous malformation feeding arterial pressures.

Subjects and Methods

Manometric data were collected during subselective angiography in 32 patients with cerebral arteriovenous malformations. Patients who had undergone prior treatment (embolization, surgery, or radiotherapy) were excluded from this study. In addition, patients with dural or spinal arteriovenous malformations were excluded. The study group consisted of 16 female and 16 male patients, 7 to 58 years of age (mean 33). Arteriovenous malformation locations included frontal ($n = 5$), parietal ($n = 11$), temporal ($n = 4$), occipital ($n = 5$), cerebellar ($n = 2$), corpus callosum ($n = 2$), and mesencephalic ($n = 3$).

Subselective catheterizations were performed in the initial eight patients with 2.2-F High-Flow microcatheters (Tracker, Target Therapeutics, Fremont, Calif). Catheterizations of the next 26 patients were performed with 1.8-F flow-directed microcatheters (Magic, Balt, Montmorency, France). Two patients were examined with both catheter types. The data were obtained before embolization in subselective locations, with the catheter positioned as close to the arteriovenous malformation nidus as possible. Pressure was measured in the most distal positions attainable. These sites were all arterial branches exclusively supplying the nidus without shared normal parenchymal branches arising distal to the measured positions. Where more than one juxtanal pedicle pressure measurement was obtained, a mean of the pedicle measurements was expressed. The pressures were each obtained without systolic-diastolic differences, because microcatheter luminal size dampens the systolic-diastolic wave-form (24,25). These mean values were expressed as the mean feeding arterial pressure. A simultaneous peripheral mean arterial pressure was determined with each feeding arterial pressure measurement using a brachial blood pressure cuff, and feeding arterial pressure/mean arterial pressure ratios were then calculated.

Pretreatment angiograms were evaluated for vascular characteristics, including venous drainage pattern (central, peripheral, or mixed), periventricular location, and angiomatous change.

Diameters were measured in three orthogonal planes, and the mean diameter and greatest diameter were determined for each arteriovenous malformation nidus. Magnification factors were corrected by cephalometric comparison measurements made with computed tomography or magnetic resonance studies of the head. The length of the feeding artery was approximated by measuring the distance from the center of the nidus to the basilar bifurcation and ipsilateral internal carotid bifurcation. A mean distance was determined for the three orthogonal measurements from each bifurcation; these values were labeled *carotid distance* and *basilar distance*. Statistical analysis correlating feeding arterial pressure and feeding arterial pressure/mean arterial pressure ratios with qualitative nominative variables was performed using χ^2 testing. Linear regression analysis and *t* tests were performed for continuous quantitative variables.

Results

Feeding arterial pressure measurements ranged from 21 to 69 mm Hg (mean, 43 ± 11 mm Hg). Feeding arterial pressure/mean arterial pressure ratios ranged from 0.25 to 0.79 (mean, 0.51 ± 0.13). Mean arteriovenous malformation diameters ranged from 1.77 to 6.55 cm (mean, 3.7). Basilar distances ranged from 1.66 to 8.25 cm (mean, 5.2); carotid distances ranged from 1.82 to 8.45 cm (mean, 3.7).

Eight of 32 arteriovenous malformations (25%) demonstrated angiomatous change. Feeding arterial pressures in patients with angiomatous change were significantly lower than those in patients without angiomatous change ($P = .008$). Patients with angiomatous change showed feeding arterial pressures from 21 to 43 mm Hg (mean, 34 ± 7 mm Hg), whereas those without angiomatous change had feeding arterial pressures from 32 to 69 mm Hg (mean, 44 ± 9 mm Hg). The feeding arterial pressure/mean arterial pressure ratios were also significantly lower in patients with angiomatous change ($P = .03$). Feeding arterial pressure/mean arterial pressure ratios ranged from 0.25 to 0.60 (mean, 0.42 ± 0.11) in patients with angiomatous change and from 0.35 to 0.79 (mean, 0.53 ± 0.11) in patients without angiomatous change.

Nine arteriovenous malformations (28%) demonstrated central venous drainage, 10 (32%) demonstrated peripheral venous drainage, and 13 (40%) demonstrated mixed venous drainage. Arteriovenous malformations with central, mixed, and peripheral venous drainages demonstrated progressively decreasing feeding arterial pressure and feeding arterial pressure/mean arterial pressure values as the drainage pattern moved from

central to peripheral (Table 1). This trend to decreasing arterial pressures from central to peripheral venous drainage was not statistically significant.

The major feeding artery distance was also correlated to the venous drainage pattern (Table). Arteriovenous malformations with central venous drainage had a significantly shorter approximated pedicle length than those with mixed or peripheral drainage ($P = .0004$). A trend to decreasing feeding arterial pressure was seen with increasing carotid artery to arteriovenous malformation distances (carotid distance) and basilar artery to arteriovenous malformation distances (basilar distance). This trend was not statistically significant (Fig 1, A and B).

No definite correlation could be found between arteriovenous malformation size and feeding arterial pressure or feeding arterial pressure/mean arterial pressure ratios. Feeding arterial pressure could not be correlated with the presence of nidus aneurysm because of the small number of arteriovenous malformations in the study group with nidus aneurysms (four of 32 arteriovenous malformations). Thirteen patients (40%) had a history of documented hemorrhage; 12 patients (38%) had steal symptoms. No direct statistical correlation was demonstrated between mean feeding arterial pressures or feeding arterial pressure/mean arterial pressure ratios in patients with documented hemorrhage or steal symptoms.

Discussion

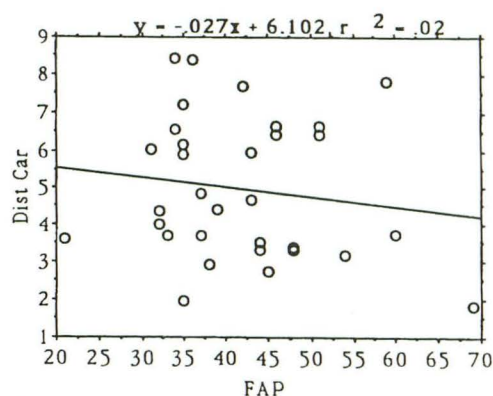
Angiomatous change is demonstrated angiographically when the arteriovenous malformation nidus is supplied by dilated cortical vessels, which then fill toward the arteriovenous malformation nidus in a retrograde fashion. This angiographic finding has been previously correlated positively with steal symptoms and negatively with hemorrhage (17,18). It has been postulated that these strong clinical correlations could be explained by

Correlation of feeding arterial pressure (FAP) and supply distance with venous drainage pattern

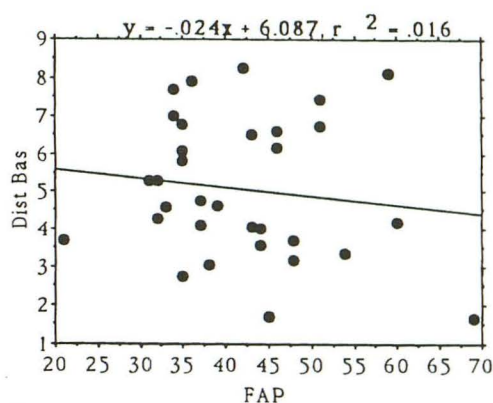
	Central	Mixed	Peripheral
FAP (mm Hg)	46 ± 12	41 ± 10	39 ± 6
FAP/mean arterial pressure	0.53 ± 0.14	0.50 ± 0.14	0.47 ± 0.09
Major Feeding Artery Distance ^a	3.2 ± 0.5	5.1 ± 0.42	6.4 ± 0.48

Values are the mean ± standard deviation.

^a The distance (cm) of the predominant arterial supply to the arteriovenous malformation (carotid or basilar), as determined with angiography.



A



B

Fig. 1. A, Relationship between the distance from the ipsilateral carotid artery to the arteriovenous malformation (y axis, Dist Car, cm) versus the feeding arterial pressure (x axis, feeding arterial pressure; mm Hg). A trend for lower feeding arterial pressure with greater distance of carotid artery to arteriovenous malformation is noted.

B, Relationship between the distance from the basilar artery to the arteriovenous malformation (y axis, Dist Bas, cm) versus the feeding arterial pressure (x axis, feeding arterial pressure, mm Hg). There is a trend to lower feeding arterial pressure with greater distance of basilar artery to arteriovenous malformation.

the fact that perfusion pressures to the arteriovenous malformation were lowered enough to lead to the development of transcortical collaterals (17). This decreased perfusion pressure to the nidus may not only decrease the risk of arteriovenous malformation rupture, but may also result in relative decreased perfusion to the surrounding parenchyma, resulting in steal symptoms. The finding in this report that feeding arterial pressure and feeding arterial pressure/mean arterial pressure were significantly lower in those patients with angiomatous change than in those without angiomatous change supports this hypothesis.

Elevated drainage pressures have been postulated to play a role in increasing the risk of arteriovenous malformation hemorrhage, possi-

bly causing increased intranidal pressure. This elevation may be caused by a central venous drainage pattern compared with a peripheral venous drainage pattern, stenotic or occlusive involvement of the venous drainage system, or a decreased number of draining veins (18,20,21). A central venous drainage pattern has previously been shown to correlate strongly with a history of hemorrhage (18,20); peripheral venous drainage has been shown to correlate significantly with steal symptoms (17). This study has shown a trend to peripheral venous draining arteriovenous malformations having lower feeding arterial pressure and feeding arterial pressure/mean arterial pressure ratios than central venous draining arteriovenous malformations. This finding may help explain the clinical relationships described between venous drainage pattern and hemorrhage, or steal.

One possible explanation for the relationship between central drainage and hemorrhage and the association of peripheral drainage and steal may be the length of arterial pedicles supplying the arteriovenous malformation. Central-draining legions are more likely to be fed by short pedicles. These short feeding branches will provide the arteriovenous malformation with higher perfusion pressures in a passive vascular system. A relationship between short pedicle length and central drainage was demonstrated by this study. Although our method of approximating feeding pedicle length is imperfect and tends especially to underestimate the length of tortuous pedicles, we showed a trend to greater feeding arterial pressures with shorter feeding arteries by direct pressure measurements.

Analysis of vascular risk factors is made more complicated by overlap of several variables, such as pedicle length, type of venous drainage, and arteriovenous malformation size. For example, a larger, centrally located arteriovenous malformation would also have a greater chance of partially occupying a more peripherally draining portion of the brain than a smaller, centrally located arteriovenous malformation. Therefore, the larger arteriovenous malformation is more likely to be classified as having mixed drainage. This mixed drainage would confer less risk of hemorrhage.

Arteriovenous malformation size may also affect pedicle length determination. A larger, centrally located arteriovenous malformation could add several centimeters of feeding artery length, measured as the distance traveled to the arteriovenous malformation center. The larger arterio-

venous malformation would, therefore, have a longer measured pedicle length, despite having some components of the nidus supplied by short feeding pedicles and, therefore, being partially exposed to higher feeding arterial pressures. This effect on measured pedicle length may in part explain why a relationship between decreased feeding arterial pressure and increasing arteriovenous malformation size could not be found. Arteriovenous malformation size has been shown to relate to steal symptoms (17); larger arteriovenous malformations have been shown to cause a significant decrease in perfusion to surrounding brain parenchyma (26,27). A larger arteriovenous malformation is likely to have significantly more shunting and lower feeding pressures by virtue of the fact that it may absorb greater feeding artery flow. A relationship between feeding arterial pressure and size has been reported using direct arterial puncture at the time of surgery (23).

In conclusion, we have demonstrated a significant decrease in feeding arterial pressure when angiomatous change is found. This provides a physiologic explanation for the positive correlation between angiomatous change and steal symptoms, and the negative correlation between angiomatous change and hemorrhage. Central-draining arteriovenous malformations and arteriovenous malformations with shorter feeding artery pedicles show a trend to greater feeding arterial pressure. The greater pressure seen with these variables may help explain why central venous drainage is more likely to be present in arteriovenous malformation patients who have bled. We were not, however, able to demonstrate a direct relationship between hemorrhage or steal symptoms and feeding arterial pressure. The steady-state feeding arterial pressure measurement is likely one of several variables controlling the risk of developing hemorrhage or steal.

References

1. Wilkins RH. Natural history of intracranial vascular malformations: a review. *Neurosurgery* 1985;16:421-430
2. Luessenhop AJ. Natural history of cerebral arteriovenous malformations In: Wilson CB, Stein BM, eds. *Intracranial arteriovenous malformations*. Baltimore: Williams & Wilkins, 1984:12-23
3. Fufts D, Kelly DL Jr. Natural history of arteriovenous malformations of the brain: a clinical study. *Neurosurgery* 1984;15:658-662
4. Graf CJ, Perret GE, Torner JC. Bleeding from cerebral arteriovenous malformations as part of their natural history. *J Neurosurg* 1983;58:331-337
5. Fox AJ, Pelz DM, Lee DH. Arteriovenous malformations of the brain: recent results of endovascular therapy. *Radiology* 1990;177:51-57

6. Purdy PD, Samson D, Batjer HH, Risser RC. Preoperative embolization of cerebral arteriovenous malformations with polyvinyl alcohol particles: experience in 51 adults. *AJNR Am J Neuroradiol* 1990;11:501-510
7. Marks MP, Lane B, Steinberg GK, et al. Endovascular treatment of cerebral arteriovenous malformations following radiosurgery. *AJNR Am J Neuroradiol* 1993;14:297-303
8. Spetzler RF, Martin NA, Carter LP, Flom RA, Raudzen, PA, Wilkinson E. Surgical management of large AVMs by staged embolization and operative excision. *J Neurosurg* 1987;67:17-28
9. Marks MP, DeLaPaz RL, Fabrikant JI, et al. Intracranial vascular malformations: Imaging of charged particle radiosurgery, I: results of therapy. *Radiology* 1988;168:447-455
10. Steinberg GK, Fabrikant JI, Marks MP, et al. Stereotactic heavy-charged-particle Bragg-peak radiation for intracranial arteriovenous malformation. *N Engl J Med* 1990;323:96-101
11. Lunsford LD, Kondziolka D, Flickinger JC, et al. Stereotactic radiosurgery for arteriovenous malformations of the brain. *J Neurosurg* 1991;75:512-524
12. Jafar JJ, Davis AJ, Berenstein A, Choi IS, Kupersmith MJ. The effect of embolization with N-butyl cyanoacrylate prior to surgical resection of cerebral arteriovenous malformations. *J Neurosurg* 1993;78:60-69
13. Kusske JA, Kelly WA. Embolization and reduction of the "steal" syndrome in cerebral arteriovenous malformations. *J Neurosurg* 1974;40:313-321
14. Dawson RC, Tarr RW, Hecht ST, et al. Treatment of arteriovenous malformations of the brain with combined embolization and stereotactic radiosurgery: results after 1 and 2 years. *AJNR Am J Neuroradiol* 1990;11:857-864
15. Luessenhop AJ, Gennarelli TA. Anatomical grading of supratentorial arteriovenous malformations for determining operability. *Neurosurgery* 1977;1:30-35
16. Spetzler RF, Martin NA. A proposed grading system for arteriovenous malformations. *J Neurosurg* 1986;65:476-483
17. Marks MP, Lane B, Steinberg G, Chang P. Vascular characteristics of intracerebral arteriovenous malformations in patients with clinical steal. *AJNR Am J Neuroradiol* 1991;12:489-496
18. Marks MP, Lane B, Steinberg GK, Chang PJ. Hemorrhage in intracerebral arteriovenous malformations: angiographic determinants. *Radiology* 1990;176:807-813
19. Lasjaunias P, Manelfe C, Terbrugge K, Ibor LL. Endovascular treatment of cerebral arteriovenous malformations. *Neurosurg Rev* 1986;9:265-275
20. Miyasaka Y, Yada K, Ohwada T, Kitahara T, Kurata A, Irikura K. An analysis of the venous drainage system as a factor in hemorrhage from arteriovenous malformations. *J Neurosurg* 1992;76:239-243
21. Vinuela F, Nombela L, Roach MR, Fox AJ, Pelz DM. Stenotic and occlusive disease of the venous drainage system of deep brain AVMs. *J Neurosurg* 1985;63:180-184
22. Marks MP, Lane B, Steinberg GK, Snipes GJ. Intranidal aneurysms in cerebral arteriovenous malformations: evaluation and endovascular treatment. *Radiology* 1992;183:355-360
23. Spetzler RF, Hargraves RQ, McCormick PW, Zabramski JM, Flom RA, Zimmerman RS. Relationship of perfusion pressure and size. *J Neurosurg* 1992;76:918-923
24. Jungreis CA, Horton JA. Pressure changes in the arterial feeder to a cerebral AVM as a guide to monitoring therapeutic embolization. *AJNR Am J Neuroradiol* 1989;10:1057-1060
25. Duckwiler G, Dion J, Vinuela F, Jabour B, Martin N, Benton J. Intravascular microcatheter pressure monitoring: experimental results and early clinical evaluation. *AJNR Am J Neuroradiol* 1990;11:169-175.
26. Marks MP, Lane B, Steinberg GK, Enzmann DR. Correlation of xenon-enhanced computed tomography and angiography in patients with intracerebral arteriovenous malformations and clinical symptoms of steal. In: Yonas H, ed. *Cerebral blood flow measurement with stable xenon-enhanced computed tomography*. New York: Raven Press, 1990:175-182
27. Marks MP, O'Donahue J, Fabricant JI, et al. Cerebral blood flow evaluation of arteriovenous malformations with stable xenon CT. *AJNR Am J Neuroradiol* 1988;9:1169-1175