AJNR

MR of neurocutaneous melanosis.

A J Barkovich, I J Frieden and M L Williams

AJNR Am J Neuroradiol 1994, 15 (5) 859-867
http://www.ajnr.org/content/15/5/859

This information is current as
of October 12, 2024.

MR of Neurocutaneous Melanosis

A. James Barkovich, Ilona J. Frieden, and Mary L. Williams

PURPOSE: To describe the MR findings of neurocutaneous melanosis in the brain and correlate these with the known pathology and proposed embryologic basis of this disorder. **METHODS:** The brain (seven patients) and spine (three patients) MR scans of seven patients with neurocutaneous melanosis were retrospectively reviewed. In two patients, findings were confirmed at surgery. The pattern of central nervous system involvement was also correlated with known pathologic studies regarding frequency and location of melanotic deposits. **RESULTS:** Five patients had regions of T1 shortening in the cerebellum; three of these also had T2 shortening. Five patients had regions of T1 shortening in the anterior temporal lobes. Other areas of involvement included the pia mater over the cerebellum (two patients), pons (one patient), medulla (one patient), and left parietal lobe (one patient). Only two lesions showed enhancement, edema, or necrosis; both were proved malignant melanomas at biopsy. No pial enhancement was detected. **CONCLUSION:** Neurocutaneous melanosis appears to involve the brain in specific locations that can be detected on MR imaging. Knowledge of these locations can aid in differentiating metastases, secondary to malignant degeneration of the large cutaneous nevi, from melanotic deposits that are a part of the disease. Identification of malignant degeneration of the melanotic deposits is difficult; at present, it depends on the identification of growth, edema, or necrosis of the deposits.

Index terms: Phakomatoses; Infants, diseases; Melanoma; Brain, magnetic resonance

AJNR Am J Neuroradiol 15:859–867, May 1994

Neurocutaneous melanosis is a rare congenital syndrome characterized by the development of congenital melanocytic nevi and benign or malignant melanotic tumors of the central nervous system (1–4). Several reports have described magnetic resonance (MR) findings of central nervous system disease in neurocutaneous melanosis (4–6). We have had the opportunity to review MR scans of seven patients with neurocutaneous melanosis. In this report, we describe the abnormal intracranial MR findings of those seven patients and attempt to relate these abnormalities to those described in the pathology literature and the presumed embryogenesis of the disorder.

Received April 16, 1993; accepted pending revision July 6; revision received August 12.

From the Departments of Neuroradiology (A.J.B.) and Pediatric Dermatology (I.J.F., M.L.W.), University of California, San Francisco.

Address reprint requests to A. James Barkovich, MD, Department of Radiology, University of California, 505 Parnassus Ave, San Francisco, CA 94143–0628.

AJNR 15:859–867, May 1994 0195-6108/94/1505–0859
© American Society of Neuroradiology

Patients and Methods

As part of our ongoing evaluation of infants with large congenital nevi (Fig 1), we found seven patients with MR findings of neurocutaneous melanosis. The patients ranged in age from 2 weeks to 15 years, with an average age of 2 years and a median age of 6 weeks (Table 1). All had multiple large cutaneous nevi; the majority of the nevi were on the trunk. Patients 1, 2, 3, 6, and 7 had no neurologic signs or symptoms and had normal neurologic findings at the time of their initial MR. Patient 5 presented with macrocephaly secondary to hydrocephalus at the age of 1 month. Patient 6 presented with a seizure at the age of 15 years. Computed tomography (not available) reportedly showed a hemorrhagic mass in the left frontoparietal region, which was resected surgically. MR scans, obtained only after surgery, showed findings of neurocutaneous melanosis. All patients had foci of T1 shortening within the brain on their MR studies, identical to the melanotic foci described in two case reports of pathologically proved neurocutaneous melanosis (4,6). One patient in this study was previously reported in a case report of neurocutaneous melanosis associated with the Dandy-Walker malformation (4).

MR studies were performed at 1.5 T in six patients and at 0.3 T in one. All patients had 3- to 5-mm (1-mm gap) sagittal spin-echo 400–616/10–25/1 (repetition time/echo

Fig. 1. Patient 1.

A, Large cutaneous melanotic nevus covering most of the back of the patient, with several satellite nevi superiorly.

B, Midline sagittal spin-echo 500/11 image shows abnormal high signal in the basis pontis (*open arrow*) and over the surface of the cerebellar vermis (*closed arrows*). The inferior vermian lobules are hypoplastic.

C, Parasagittal spin-echo 500/11 image shows the hypoplasia of the right cerebellar hemisphere, with the inferior portion of the hemisphere unformed (*arrows*). The hyperintensity of the basis pontis is again noted.

D, Axial spin-echo 600/15 image shows foci of short T1 (*large arrows*) in the anterior temporal lobes in the region of the amygdala bilaterally. Some T1 shortening is also seen in the superior vermian fissures (*small arrows*), corresponding to that seen in Fig 3A.

A

B C D

time/excitations) images. Six patients had 4- to 5-mm (1-mm gap) axial spin-echo 500–600/11–20 images, and six had axial 4- to 5-mm (2-mm gap) spin-echo 2800–3000/30–60, 80–120 images. Four patients had coronal 5-mm (1-mm gap) spin-echo 600–800/20–35 images. Four patients were imaged after intravenous infusion of 0.1 mg/kg gadopentetate dimeglumine. All had axial 3.5- to 5-mm spin-echo 500–600/12–20 images and coronal 4- to 5-mm spin-echo 600/12–20 images after administration of the contrast material. The acquisition matrix was 192–256 × 256 in all imaging sequences.

The spine was imaged in three patients. Two were imaged only before the infusion of intravenous gadopentetate dimeglumine. Sagittal 3-mm spin-echo 600/12 images were obtained in one patient, and sagittal 4-mm spin-echo 600/30 and 1500/30, 75 images were obtained in the other. One patient was imaged (sagittal 3-mm spin-echo 500/12) before and after the infusion of intravenous gadopentetate dimeglumine. The acquisition matrix was the same as that for the brain studies.

Follow-up exams were obtained in three patients. Patient 3, who was asymptomatic, was studied three times, at 7, 11, and 14 months of age. Patient 5 was studied sequentially, at 6-month intervals, after his initial study. No change was seen until he became symptomatic at 22 months of age and was found to have an enlarging left temporal mass (4). Patient 4 has had MR scans every 3 months over the 12 months since resection of his left hemispheric melanoma.

TABLE 1: Seven patients with neurocutaneous melanosis

Patient No.	Age	MR Findings
1	5 mo	Short T1 bilateral near amygdala, belly of pons, cerebellar fissures Cerebellar and pontine atrophy
2	6 wk	Areas of short T1, T2 near amygdala (L (8 mm) > R) R cerebellar dentate, bilateral cerebellar hemisphere (8 mm L inferomedial, 4 mm R inferomedial) Spine: normal
3	7 mo	Areas of short T1, T2 near amygdalae (L (3 mm), R (5 mm)) R medullary pyramid (3 mm) Spine: normal
4	15 y	Short T1 in R (2 × 2 mm) and L amygdalae Postsurgical changes in left frontoparietal region
5	1 mo	Short T1 in R (2 × 2 mm) and L (3 × 4 mm) amygdalae Short T1 in pia mater overlying cerebellum. Dandy-Walker malformation Short T1 (5 × 5 mm) in inferior L cerebellar hemisphere
6	1 mo	Short T1 in R (5 × 5 mm) and L (3 × 7 mm) cerebellar hemispheres
7	2 wk	Areas of short T1, T2 inferior L cerebellar hemisphere Spine: normal

Images were analyzed retrospectively by an experienced pediatric neuroradiologist (J.B.). Specifically, the images were analyzed for the size of the subarachnoid spaces, the presence of any regions of abnormal signal intensity within the brain or meninges, the presence of any masses or mass effects, and the presence of any malformative changes in the brain.

Results

Because MR findings compatible with neurocutaneous melanosis were a requirement for inclusion in this study, abnormalities were seen in all seven patients (Table 1). Five patients had areas of short T1 relaxation in the cerebellum or the pia mater over the cerebellum. In four, the foci of T1 shortening were within the cerebellar parenchyma (Fig 2A). One patient also had T2 shortening (Fig 2B). These foci ranged from 3 to 8 mm in size; none had associated mass effect or edema. Patient 5 had T1 shortening of the surface of the cerebellum (possibly pial or subpial) and a Dandy-Walker malformation in addition to the cerebellar parenchymal focus. Patient 1 had T1 shortening over the surface of the cerebellum and inferior cerebellar hypoplasia without definite parenchymal T1 shortening (Fig 1). Patients 1 and 5 had areas of short T1 in the temporal lobes, immediately anterior to the temporal horns of the lateral ventricles (Fig 1D), in the region of the amygdala, as did patients 3 (Fig 3A), 2, and 4 (Fig 4). Patient 1 had an additional large area of T1 shortening in the ventral pons (Fig 1B). Patient 3 had an area of T1 shortening involving the right medullary pyramid (Fig 3B). No apparent edema or mass effect resulted from any lesions other than those in patients 5 and 6 (Fig 5), who had surgically proved melanomas. No apparent enhancement of these regions of abnormal signal intensity was present in the four patients who received intravenous paramagnetic contrast material, other than in patients 5 and 6, who had melanomas.

Of the three patients who were followed with sequential exams, patients 3 and 4 showed no change over 11 and 16 months, respectively, whereas patient 5, as reported above, showed marked enlargement of the left temporal mass at 22 months of age (4) and has since died.

Images of the spine were completely normal in the three patients in whom they were obtained.

Discussion

Neurocutaneous melanosis was first described by Rokitansky, who reported a 14-year-old girl with a giant congenital melanocytic nevus and mental retardation, who developed late-onset hydrocephalus (7). Since that initial report, nearly 100 cases have been reported. Giant congenital nevi are themselves a relatively rare birthmark, occurring in approximately one in 20 000 to 50 000 live births (2). Their cause is not known, although they are thought to represent an error in morphogenesis of the embryonic neuroectoderm (2,3).

In 1972, Fox proposed the following criteria for diagnosing neurocutaneous melanosis: 1) unduly large or unusually numerous pigmented nevi in association with melanosis or melanoma of the pia-arachnoid; 2) no evidence of malignant change in any of the cutaneous lesions; and 3) no evidence of malignant melanoma in any organ apart from the meninges (2).

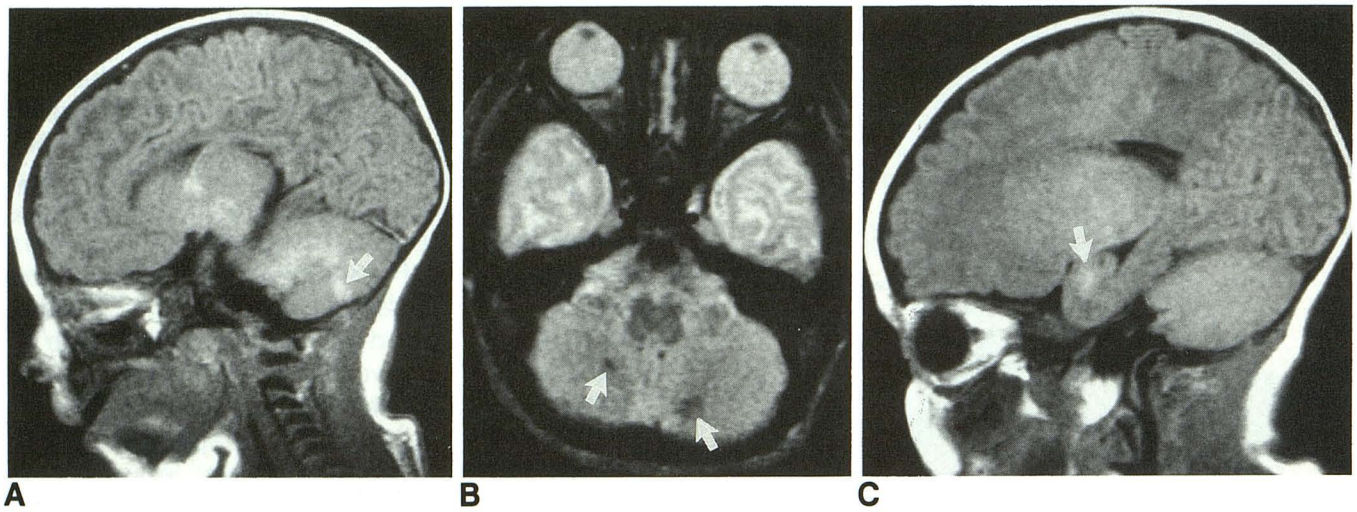

Fig. 2. Patient 2.

A, Parasagittal spin-echo 550/20 image shows T1 shortening (*arrow*) in the inferior left cerebellar hemisphere. The high signal intensity in the corpus medullare and the middle cerebellar peduncle were thought to represent early myelination.

B, Axial spin-echo 2800/100 image shows areas of short T2 (*arrows*) in both cerebellar hemispheres. The low signal intensity ventral to the medulla is an artifact from vascular and cerebrospinal fluid pulsations.

C, Parasagittal spin-echo 550/20 image shows T1 shortening (*arrow*) anterior to the right temporal horn of the lateral ventricle.

Fig. 3. Patient 3.

A, Parasagittal spin-echo 616/11 image shows focus of short T1 (*arrow*) in the anterior temporal lobe.

B, Axial spin-echo 600/16 image shows focus of short T1 (*arrow*) in the right ventral medulla.

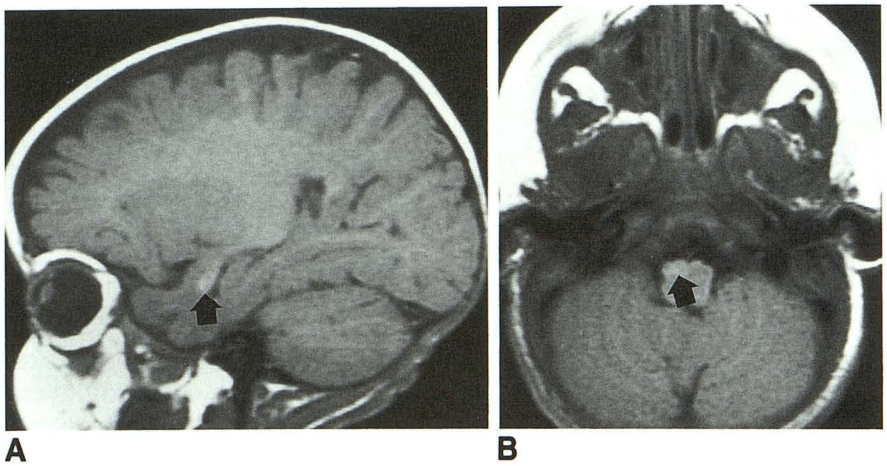

Kadonaga and Frieden (3) have recently proposed a revision of these criteria for diagnosis to define more accurately the population at risk: 1) large or multiple (three or more) congenital nevi in association with meningeal melanosis or central nervous system melanoma, where large is defined as equal to or greater than 20 cm in an adult, 9 cm in diameter on the scalp of an infant, or 6 cm or greater in diameter on the body; 2) no evidence of cutaneous melanoma, except in patients in whom the examined areas of the meningeal lesions are histologically benign; and 3) no evidence of meningeal melanoma, except in patients in whom examined areas of the skin are histologically benign. Those cases with histologic confirmation are considered definite; all other are considered provisional diagnoses. By this definition, all of the patients in this manuscript, other than patients 5 and 6, received provisional diagnoses of neurocutaneous melanosis.

The MR studies in our patient group all showed foci of T1, and sometimes T2, shortening in the brain parenchyma or meninges, characteristics that are compatible with deposits of melanin. Woodruff et al (8) and Atlas et al (9) described the MR characteristics of intracranial melanoma as showing significant T1 shortening and lesser T2 shortening compared with normal brain tissue. Moreover, Sebag et al (6) reported a patient with neurocutaneous melanosis and a surgically proved anterior temporal lobe melanoma that showed similar MR characteristics. The T1 and T2 shortening is presumably the result of the presence of stable free radicals in melanin (iden-

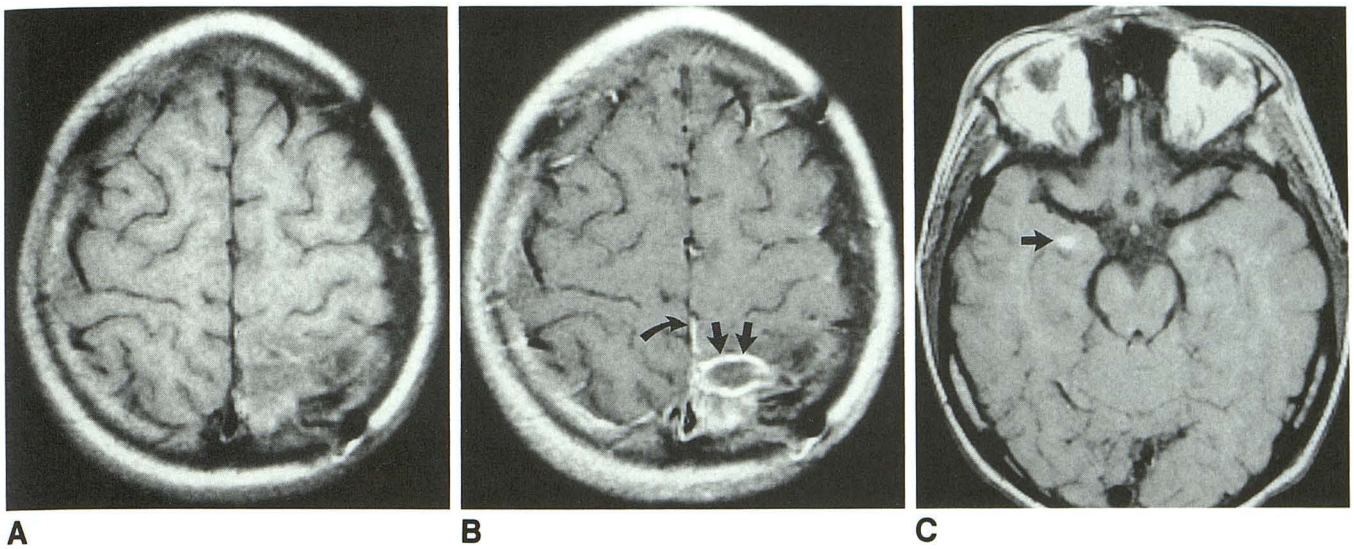

Fig. 4. Patient 4.

A, Noncontrast axial spin-echo 500/19 image at the site of previously resected melanoma shows only questionable T1 shortening of the meninges despite surgical finding of black meninges secondary to infiltration by melanocytes.

B, Postcontrast material administration axial spin-echo 500/19 image shows enhancement of the surgical cavity (*straight arrows*) and adjacent meninges (*curved arrow*). Unfortunately, it is not possible to differentiate enhancement from postoperative granulation tissue from enhancement secondary to meningeal melanoma.

C, Axial spin-echo 500/19 at the level of the temporal lobe shows the anterior temporal T1 shortening (*arrow*) that was commonly found in patients in this study. This finding strongly suggests that the melanoma in the parietal lobe is the result of neurocutaneous melanosis and not a metastasis from malignant degeneration of the patient's large cutaneous nevus. The area of high signal in the left uncus was not seen on other sequences and is, therefore, believed to be an artifact.

tified by electron spin resonance studies [10,11]). The unpaired electrons in free radicals interact with water protons via an electron-proton dipole-dipole interaction, with subsequent shortening of both T1 and T2 relaxation times (12,13).

The anterior temporal lobes and cerebellum appear to be the most common locations for melanocytic accumulation in neurocutaneous melanosis (1,3,6,14–17). In the anterior temporal lobe, the amygdala is particularly affected (1,4,14–16). Other common locations include the thalami, cerebellum, and base of the frontal lobe (1,3,6,14–17). Whether our group of patients did not have thalamic or frontal lesions, or MR is insensitive to lesions in those locations is not apparent from this study. Although the reason for melanocytic accumulation in these locations has not been fully elucidated, it seems reasonable to speculate that the melanocytes spread to these locations because they are close to the basilar meninges, which are known to contain an excessive number of melanocytes in neurocutaneous melanosis.

Pathologists may find an excess of benign melanotic cells within the basilar meninges of healthy patients at autopsy, as both melanocytes and the basilar pia-arachnoid derive from the neural crest (18–20). Patients with neurocutaneous melanosis, however, have orders of magnitude more melanocytes, which may be diffuse or nodular within the meninges (2,3). The reason for the abundance of melanocytes may be: 1) an abnormal migration of melanocyte precursors (21); 2) abnormal expression of melanin-producing genes within the leptomeningeal cells (22); or 3) a rapid proliferation of "normal" melanin-producing leptomeningeal cells.

Although the specific primordial cells from which melanin-containing cells derive have not been identified, Cramer has proposed that they develop from neural crest-derived nerve sheath precursor cells that migrate to the skin by way of the paraspinal ganglia and peripheral nerve sheaths (Fig 6) (23). The migration occurs along the autonomic nerves, sensory nerves, vascular structures, and adnexal structures, which may explain both the mode of migration of the melanin-containing cells into the nervous system and the presence of perivascular infiltrates from both benign congenital nevi and the central nervous system lesions of neurocutaneous melanosis (3,23). However, as the autonomic nerves, paraspinal ganglia, and peripheral nerve sheaths derive from the neural crest (24), an alternative

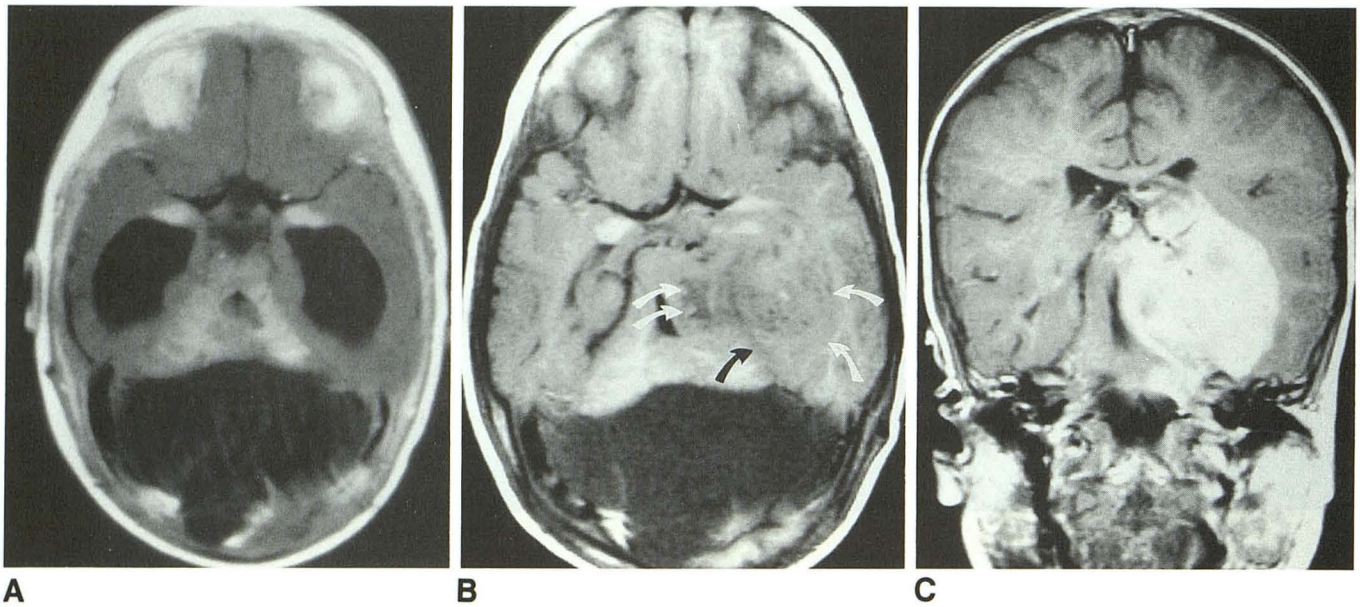

Fig. 5. Patient 5.

A, Axial spin-echo 550/20 image shows Dandy-Walker malformation, high-intensity signal in the cerebellar hemispheres, and high-intensity foci anterior to the dilated temporal horns of the lateral ventricles. [From Kadonaga et al (4), reprinted with the permission of Blackwell Scientific Publications, Inc.]

B, Noncontrast axial spin-echo 500/16 image shows a heterogeneous mass (*arrows*) in the left temporal lobe, distorting the high signal anterior to the temporal horn and crossing the tentorium cerebellum, with invasion of the midbrain and cerebellar peduncle.

C, Postcontrast coronal spin-echo 550/29 image shows that the tumor heterogeneously enhances.

D, Microscopic specimens from left temporal lobe tumor shows melanocytes (*small closed arrows*) involving the meninges, with extensive invasion into the underlying cerebral cortex (*open arrows*).

D

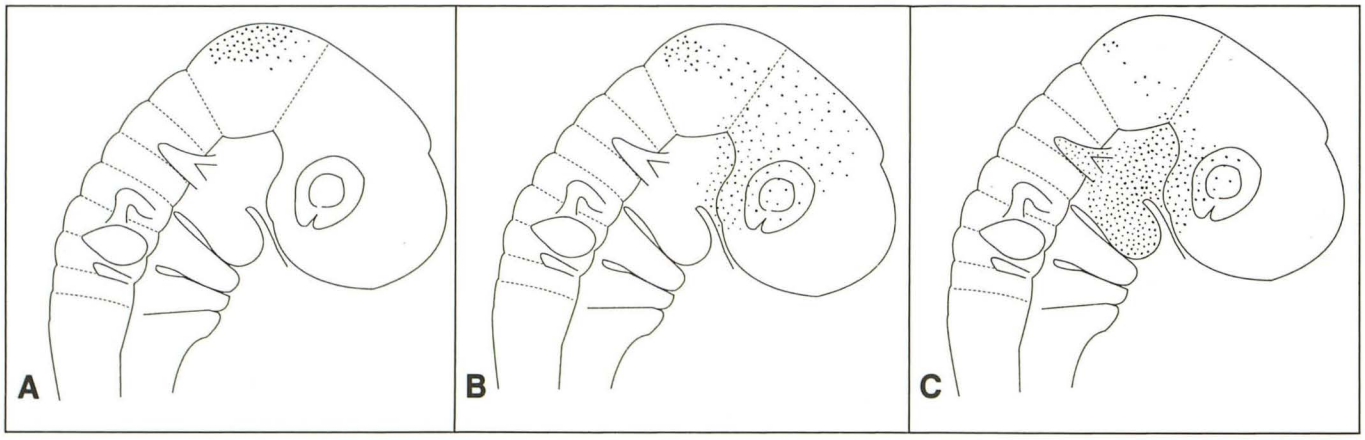

Fig. 6. Migration of neural crest cells to form the meninges.

A, Neural crest cells originate in the dorsolateral portion of the neural tube.

B,C, The cells migrate from their site of origin to the region of the cephalic flexure, where the earliest portions of the meninges coalesce in the region that will eventually form the basilar leptomeninges and the tentorium cerebellum.

explanation is that the melanin-containing cells are merely neural crest cells that are misprogrammed, either genetically or as a result of abnormal interaction with cell surface or interstitial molecules. Melanocyte precursor cells appear to migrate and differentiate relatively early in development; melanotic cells have been found in fetal epidermis at a gestational age of 10 weeks and in the meninges at 5 months' gestation (3,25).

The pia-arachnoid invaginates into the brain with developing blood vessels to form the perivascular spaces (26). We presume that an abundance of pia-arachnoidal melanocytes, or potential melanocytes, migrates within these meningeal layers in patients with neurocutaneous melanosis. The finding of melanotic cells surrounding blood vessels in the perivascular spaces is characteristic of neurocutaneous melanosis; melanocytes are not seen in the perivascular spaces of healthy patients (1,2,19). Accumulations of melanocytes within the perivascular spaces in neurocutaneous melanosis can be large (1–3). We presume that the melanotic deposits in most of our patients were, in fact, located in the perivascular spaces.

It is important to note that it is not possible to distinguish benign accumulations of melanocytes from malignant ones based on the MR images in most cases. For example, the anterior temporal lobe accumulations in patients 3 and 4 (Figs 3 and 4) are identical in appearance to that in the case discussed by Sebag et al, which was reported as a malignant melanoma, and that in our patient 5, in whom the left anterior temporal accumulation grew and invaded the tentorium and cerebellum after remaining stable on serial exams over 20 months (4). However, the accumulations in patient 3 were unchanged over 7 months, and those in patient 4 have been stable for over 12 months. It is not surprising that MR differentiation of benign from malignant melanomas is difficult, as differentiation of benign from malignant melanocytes is difficult histologically as well. Benign cells can show cellular pleomorphism and can accumulate in nests or nodules (3). Features that aid in differentiation of benign meningeal melanosis from melanoma include (19,27): 1) benign collections lack necrosis and hemorrhage; 2) only malignant cells invade basal lamina of the blood vessels in the perivascular spaces; 3) benign cells infrequently show mitotic activity; and 4) benign cells lack annulate lamellae (concentric lamellar structures thought to represent modified melanosomes). Only the first criterion can be assessed by MR; necrosis will result in heterogeneity of the lesion, and hemorrhage will cause marked hypointensity on T2- or T2*-weighted images (9). The presence of associated vasogenic edema may also prove helpful in differentiating benign from malignant collections of melanocytes. Theoretically, vasogenic edema should only occur as a result of structural injury to the tight junctions of the cerebral endothelium, metabolic impairment of endothelial transport systems, or neovascularization by vessels lacking blood-brain barrier characteristics (28). The presence of vasogenic edema, therefore, would imply infiltration of surrounding tissues by the melanocytes, a condition considered by Fox et al to indicate malignant change (1). The lesions in all of our patients initially lacked edema, necrosis, and hemorrhage; however, a follow-up scan of patient 6 showed tumor growth, central heterogeneity (indicative of necrosis), and invasion of adjacent parenchyma (4). At surgery, malignant melanoma was found (4). It should be noted that some malignant melanomas will lack edema, hemorrhage, and necrosis (6,8,9). Therefore, it appears that only necrotic or hemorrhagic intracranial masses, or masses eliciting vasogenic edema, in patients with neurocutaneous melanosis can confidently be identified as malignant melanomas; those without hemorrhage, edema, or necrosis cannot be classified unless they show growth on subsequent scans. Patients 1, 2, 3, 6, and 7, who had no necrosis or edema associated with their intracranial masses, are being followed with serial neurologic exams and serial imaging studies. Surgical intervention will be considered only if clinical or radiologic evidence of progression is documented.

We did not detect definite meningeal enhancement in any of the three patients who were imaged after the administration of gadopentetate dimeglumine. T1 shortening of pia-arachnoid was seen in two patients; one of these was scanned after the administration of contrast material, and no significant enhancement was detected. Thus, we believe that the case described by Rhodes et al (5), in which striking enhancement of the meninges was seen after the administration of contrast material, is unusual and should not be considered typical of this disorder. Although most of our patients did not have surgical or pathologic confirmation of leptomeningeal melanosis, the presence of the presumed parenchymal melanin deposits almost certainly indicates that significant melanin was present within the leptomeninges as well, as the former is not described without the

latter (1–3,17). Moreover, patient 4, who had nearly normal meninges on precontrast MR imaging studies postoperatively (Fig 4A), had pia-arachnoid that was black and thickened with melanocytes (Cogen P, personal communication), illustrating the lack of sensitivity of noncontrast MR in detecting leptomeningeal infiltration by melanin-producing cells. Unfortunately, we are not able to differentiate normal postoperative enhancement from that secondary to melanotic meninges. It will be interesting to see, as more cases of neurocutaneous melanosis are imaged by MR, how many show leptomeningeal enhancement or precontrast T1 shortening of the meninges. Based on our experience, however, the absence of meningeal enhancement does not exclude the diagnosis of neurocutaneous melanosis. Moreover, as microscopic accumulations of melanin-producing cells in the Virchow-Robin spaces will not be seen on MR, a completely normal scan does not entirely exclude the diagnosis.

The characteristic finding of T1 shortening in the region of the amygdala in these patients was quite helpful in establishing the diagnosis of neurocutaneous melanosis in patient 4. When he presented with new focal motor seizures and a parietal mass on computed tomography, the initial clinical diagnosis was melanoma metastasis from probable malignant degeneration of a part of his large cutaneous nevus. However, after the MR was performed, and the characteristic temporal lobe focus (Fig 4C) identified, a confident diagnosis of neurocutaneous melanosis was established, as the anterior temporal lobe is an unusual location for cerebral metastasis, and the rest of the metastatic work-up was normal. Thus, awareness of this common location for melanocyte accumulation in neurocutaneous melanosis can facilitate diagnosis and aid in patient care.

The presence of the cerebellar hypoplasia in patient 1 (Fig 1) is of interest, in that it may be another manifestation of dysplasia of the leptomeninges in neurocutaneous melanosis. Van Heuzen et al (29) reported a spinal subarachnoid lipoma in a patient with neurocutaneous melanosis. Lipomas have been shown to result from maldevelopment of the arachnoid/subarachnoid space (30). Five patients have been reported with the Dandy-Walker malformation in association with neurocutaneous melanosis (4). This association suggested that a maldevelopment of the meninges associated with neurocutaneous melanosis, more specifically a defective ectodermal-mesodermal interaction (31,32), is causally related to the hind brain malformation (4). The cerebellar anomaly seen in patient 4 adds further evidence supporting this hypothesis.

The differential diagnosis of the areas of T1 shortening in our patients is rather limited. Lipomas have short T1 relaxation times, but arise in the subarachnoid space, not in cerebral parenchyma, and have associated chemical shift artifact (30). Dermoids can have short T1 relaxation times and may arise in the middle cranial or posterior fossae, but are usually more sharply demarcated, have chemical shift artifact, and demonstrate mass effect (33). Benign hemorrhage and hemorrhagic nonmelanotic neoplasms have short T1 relaxation times, but tend to have markedly short T2 relaxation times as well as some associated edema and mass effect (34). Moreover, hemorrhage will often produce neurologic or behavioral abnormalities. We believe that the characteristic location and lack of mass effect of the foci of short T1 in patients with neurocutaneous melanosis combined with the clinical setting of a young patient with giant melanotic nevi should allow confident MR diagnosis.

To summarize, we have reported the MR findings of seven patients, five with provisional diagnoses of neurocutaneous melanosis and two with pathologically proved neurocutaneous melanosis. The most common intracranial abnormalities are regions of T1 shortening in the cerebellar hemispheres and anterior temporal lobes in the region of the amygdala. Differentiation of melanomas from benign accumulations of melanotic cells within the Virchow-Robin spaces may not be possible if necrosis, hemorrhage, or edema (which indicate malignancy) is not present. Meningeal enhancement appears to be uncommon.

References

1. Fox H, Emery J, Goodbody R, Yates P. Neuro-cutaneous melanosis. *Arch Dis Child* 1964;39:508–516
2. Fox H. Neurocutaneous melanosis. In: Vincken P, Bruyn G, ed. *The phakomatoses.* New York: Elsevier, 1972:4:14–428
3. Kadonaga J, Frieden I. Neurocutaneous melanosis: definition and review of the literature. *Acad Dermatol* 1991;24:747–755
4. Kadonaga J, Barkovich AJ, Edwards MSB, Frieden I. Neurocutaneous melanosis in association with the Dandy-Walker complex. *Pediatr Dermatol* 1992;9:37–43
5. Rhodes R, Friedman H, Hatten Jr H, et al. Contrast-enhanced MR imaging of neurocutaneous melanosis. *AJNR Am J Neuroradiol* 1991;12:380–382
6. Sebag G, Dubois J, Pfister P, et al. Neurocutaneous melanosis and temporal lobe tumor in a child: MR study. *AJNR Am J Neuroradiol* 1991;12:699–700

7. Rokitansky J. Ein ausgezeichneter fall von pigment-mal mit ausgebreiteter pigmentierung der inneren hirn- und rüchenmarkshaute. *Allg Wien Med Z* 1861;6:113–116
8. Woodruff Jr W, Djang W, McLendon R, Heinz E, Voorhees D. Intracerebral malignant melanoma: high-field-strength MR imaging. *Radiology* 1987;165:209–213
9. Atlas S, Grossman R, Gomori J, et al. MR imaging of intracranial metastatic melanoma. *J Comput Assist Tomogr* 1987;11:577–582
10. Jimbow K, Miyake Y, Homma K, et al. Characterization of melanogenesis and morphogenesis of melanosomes by physiochemical properties of melanin and melanosomes in malignant melanoma. *Cancer Res* 1984;44:1128–1134
11. Sealy R. Radicals in melanin biochemistry. *Methods Enzymol* 1984;105:479–483
12. Gomori J, Grossman R, Shields J, Augsburger J, Joseph P, DeSimeone D. Choroidal melanomas: correlation of NMR spectroscopy and MR imaging. *Radiology* 1986;158:443–445
13. Burton D, Forsen S, Karlstrom G, Dwek R. Proton relaxation enhancement in biochemistry: a critical survey. *Prog NMR Spectroscopy* 1979;13:1–45
14. Thomas C, Toone B, Rose P. Neurocutaneous melanosis and psychosis. *Am J Psychiatry* 1988;145:649–650
15. Adeyanju M, Reyes M, Junaid A. Fatal pneumococcal infection in neurocutaneous melanosis. *J Child Neurol* 1988;3:293–294
16. Fischer S. Primary perivascular cerebral, cerebellar and leptomeningeal melanoma. *Acta Psychiatry Scand* 1956;31:21–34
17. Lamas E, Diez Lobato R, Lotelo T, Ricoy J, Castro S. Neurocutaneous melanosis: report of a case and review of the literature. *Acta Neurochir* 1977;36:93–105
18. O'Rahilly R, Muller F. The meninges in human development. *J Neuropath Exp Neurol* 1986;45:588–608
19. Yu H, Tsaur K, Chein C, et al. Neurocutaneous melanosis: electron microscopic comparison of the pigmented melanocytic nevi of skin and meningeal melanosis. *J Dermatol* 1985;12:267–276
20. Le Douarin N. *The neural crest.* Cambridge: Cambridge University Press, 1982:273
21. Stern C, Artinger K, Bronner-Fraser M. Tissue interactions affecting the migration and differentiation of neural crest cells in the chick embryo. *Development* 1991;113:207–216
22. Kitamuira K, Takiguchi-Hayashi K, Sezaki M, Yamamoto H, Takeuchi T. Avian neural crest cells express a melanogenic trait during early migration from the neural tube: observations with the new monoclonal antibody, "MEBL-1." *Development* 1992;114:367–378
23. Cramer S. The melanotic differentiation pathway in congenital melanocytic nevi: theoretical considerations. *Pediatr Pathol* 1988;8:253–265
24. Jacobson M. *Developmental neurobiology.* 3rd ed. New York: Plenum, 1991:776
25. Farnell J, Globus J. Primary melanoblastosis of the leptomeninges and brain. *Arch Neurol Psychiatry* 1931;25:803–823
26. Marin-Padilla M. Embryonic vascularization of the mammalian cerebral cortex. In: Peters A, Jones E, eds. *Development and maturation of the cerebral cortex.* New York: Plenum, 1988:4:79–509
27. O'Valle F, Aneiros J, Osuna A, et al. Human melanoma cell lines: an immunofluorescence and ultrastructural study. *J Cutan Pathol* 1988;15:374–379
28. Milhorat T. Classification of the cerebral edemas with reference to hydrocephalus and pseudotumor cerebri. *Child Nerv Syst* 1992;8:301–306
29. van Heuzen E, Kaiser M, de Slegte R. Neurocutaneous melanosis associated with intraspinal lipoma. *Neuroradiology* 1989;31:349–351
30. Truwit CL, Barkovich AJ. Pathogenesis of intracranial lipoma: an MR study in 42 patients. *AJNR Am J Neuroradiol* 1990;11:665–674
31. Sievers J, von Knebel Doeberitz C, Pehlemann F, et al. Meningeal cells influence cerebellar development over a critical period. *Anat Embryol* 1986;175:91–100
32. von Knebel Doeberitz C, Sievers J, Sadler M, et al. Destruction of meningeal cells over the newborn hamster cerebellum with 6-hydroxydopamine prevents foliation and lamination in the rostral cerebellum. *Neuroscience* 1986;17:409–426
33. Barkovich AJ. Neuroimaging of pediatric brain tumors. In: Berger M, ed. *Pediatric neurooncology.* Philadelphia: Saunders, 1992:7:39–770
34. Gomori JM, Grossman RI, Goldberg HI, Zimmerman RA, Bilaniuk LP. Intracranial hematomas: imaging by high field MR. *Radiology* 1985;157:87–93