

The **next generation** GBCA  
from Guerbet is here

Explore new possibilities >

Guerbet | 

© Guerbet 2024 GUOB220151-A

# AJNR

## **Treatment of traumatic arterial vasospasm with intraarterial papaverine infusion.**

A B Vardiman, T A Kopitnik, P D Purdy, H H Batjer and D S Samson

*AJNR Am J Neuroradiol* 1995, 16 (2) 319-321  
<http://www.ajnr.org/content/16/2/319>

This information is current as  
of September 20, 2024.

---

# Treatment of Traumatic Arterial Vasospasm with Intraarterial Papaverine Infusion

Arnold B. Vardiman, Thomas A. Kopitnik, Phillip D. Purdy, H. Hunt Batjer, and Duke S. Samson

**Summary:** We report a case of severe posttraumatic arterial vasospasm treated with repetitive intraarterial papaverine infusions. The salient features of the mechanism of action of papaverine are included.

**Index terms:** Vasospasm; Head, injuries; Drugs, intraarterial injection

Head injury commonly results in some degree of subarachnoid hemorrhage. If significant, the hemorrhage may play a role in the development of posthemorrhagic arterial vasospasm similar to that seen with aneurysmal subarachnoid hemorrhage. McCullough reported a direct correlation between the magnitude of basal subarachnoid blood and the degree of arteriographic vasospasm in a monkey head injury model (1). Therapy directed at vasospasm treatment, namely hyperdynamic volume expansion, is hazardous with an underlying head injury because of the presence of mass lesions, contusions, or diffuse edema. We present a case of angiographically documented vasospasm after traumatic subarachnoid hemorrhage and its treatment with intraarterial infusions of papaverine hydrochloride.

## Case Report

An unconscious 61-year-old white man was transported to the hospital for evaluation. Examination upon arrival revealed multiple facial contusions, abrasions, and a right ocular globe disruption. The patient was lethargic but obeying commands in all extremities. He was profoundly hypothermic on presentation (temperature, 32.2°C); aggressive resuscitation included peritoneal lavage with warmed Ringer's lactate. During rewarming, the patient had a respiratory arrest, and later an episode of electromechanical dissociation responsive to medication. After resuscitation, a head computed tomogram was ob-

tained, showing thick subarachnoid hemorrhage and a right temporal lobe contusion (Fig 1A and B). A four-vessel cerebral arteriogram was obtained and was unremarkable. Although the patient remained intubated for positive airway control, he remained awake and obeyed commands. Intracranial pressure was monitored by ventricular catheter, and treatment was directed at maintaining intracranial pressure less than 20 mm Hg. His arteriogram was repeated on hospital day 3 and revealed mild to moderate vasospasm. By hospital day 5 the patient was lethargic and, despite aggressive hypervolemic and judicious hyperdynamic treatment, his condition worsened to decorticate posturing. The patient's intracranial pressure was not elevated and a repeat head computed tomogram was unchanged. A cerebral arteriogram revealed diffuse vasospasm in both the middle and anterior cerebral artery distributions (Fig 1C). While in the angiography suite, 300 mg of papaverine diluted in 100 mL of saline was infused over a period of 1 hour into each internal carotid artery, with improvement in the degree of angiographic arterial spasm (Fig 1D) and improved contrast transit time. The patient began obeying commands in his right upper extremity 1 hour after papaverine infusion. Three days later on hospital day 8, the patient again neurologically deteriorated. Arteriography revealed recurrent spasm, which was treated with a subsequent intraarterial papaverine infusion as previously described. The patient again improved, obeying commands in his right upper extremity 2 hours after the infusion.

The patient underwent a fourth and final papaverine infusion into both internal carotid arteries on hospital day 11 for recurrent clinical and angiographic vasospasm, which again resulted in his improvement to following commands in the right upper extremity. Serial transcranial Doppler studies were performed throughout the patient's hospitalization, but changes in  $P_{CO_2}$ , hematocrit, and intracranial pressure rendered interpretation difficult and inconclusive. The patient was eventually transferred to the ward, obeying commands in his right upper extremity, with a moderate left hemiparesis. He died late in his hospital course secondary to a pulmonary embolism.

---

Received January 14, 1993; accepted after revision April 14.

From the Departments of Neurological Surgery (A.B.V., T.A.K., H.H.B., D.S.S.) and Neuroradiology (P.D.D.), the University of Texas Southwestern Medical Center at Dallas.


Address reprint requests to Thomas A. Kopitnik, MD, Department of Neurological Surgery, UT Southwestern Medical Center, 5323 Harry Hines Blvd, Dallas, TX 75235-8855.

AJNR 16:319-321, Feb 1995 0195-6108/95/1602-0319 © American Society of Neuroradiology

Fig 1. *A and B*, Computed tomographic scans show thick diffuse posttraumatic subarachnoid hemorrhage.

*C*, Left lateral cerebral arteriogram before papaverine infusion demonstrates vasospasm in the distal anterior cerebral distribution.

*D*, Cerebral arteriogram after papaverine infusion demonstrates improvement in the degree of vasospasm in the distal anterior cerebral circulation.



## Discussion

It has long been recognized that cerebral arterial vasospasm occurs in 5% to 50% of patients suffering a significant head injury (2–4). This is undoubtedly related to the common finding of subarachnoid blood after a major head injury. The amount of blood present in the basal cisterns is directly related to the incidence of vasospasm in postaneurysmal hemorrhage, and likely as well in trauma. Suwanwela analyzed 350 patients with moderate to severe head injuries and found proximal arterial spasm in 5% of those with moderate injuries and spasm in 58% of those with severe head injuries (5).

The severity of brain injury associated with the computed tomogram appearance of significant subarachnoid hemorrhage is frequently associated with mass lesions, contusions, or diffuse edema. The existence or potential for elevated intracranial pressure complicates the treatment of vasospasm with hyperdynamic therapy of volume augmentation and blood pressure elevation. Elevated intracranial pressure despite ventricular drainage can be considered a contraindication to hyperdynamic volume therapy. This patient presented with significant traumatic subarachnoid hemorrhage and received maximal medical therapy for intracranial pressure control as well as clinically

symptomatic vasospasm. As he continued to worsen neurologically, we instituted our protocol for severe postaneurysmal vasospasm refractory to medical therapy, with infusion of intraarterial papaverine hydrochloride.

Papaverine hydrochloride is an opium alkaloid of which the primary pharmacological activity is the relaxation of vascular smooth muscle (6). This vasodilating effect of papaverine results from phosphodiesterase inhibition and resultant cyclic-adenosine monophosphate accumulation within the smooth muscle cell. Intrathecal injection of papaverine hydrochloride in a monkey vasospasm model has been shown to decrease angiographic vasospasm (7). Kuwayama has shown that intraarterial papaverine hydrochloride significantly reversed angiographic vasospasm in a dog vasospasm model, with one-half the animals experiencing vasodilation back to control size (8). Unfortunately, these experimental models as well as this patient's course demonstrate that the effects of papaverine are fleeting, and multiple infusions may be necessary.

Prior reports have described the use of "superselective" intraarterial papaverine infusion for the treatment of vasospasm (9–11). In these reports a small microcatheter (Tracker) is typically used to deliver papaverine immedi-

ately into the spastic vascular territory. We have used nonselective papaverine infusion techniques for vasospasm related to aneurysmal subarachnoid hemorrhage and have seen encouraging clinical and angiographic results. In light of our previous experience and the presence in this patient of precavernous atherosclerotic narrowing, we elected nonselective infusion through a standard angiographic catheter into the cervical internal carotid artery. The dose of papaverine was selected empirically and by communication with other neurosurgical and neuroradiological centers that use this technique for treatment of aneurysmal hemorrhagic vasospasm (N. F. Kassell, personal communication). We also considered the use of balloon angioplasty, a technique of documented efficacy (4, 12–14), but believed the distal component of spasm and the precavernous carotid atherosclerosis made the use of intraarterial papaverine preferable.

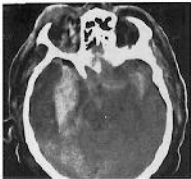The clinical improvement seen in this particular case was likely caused by global effects of papaverine rather than effects in a single vascular territory. The patient's neurologic improvement from decorticate posturing to following commands was most likely caused by papaverine-laced blood perfusing the diencephalon and brain stem through the posterior communicating and posterior cerebral arteries. Although clinical improvement was transient and angiographic improvement modest, the patient ultimately stabilized at his improved neurologic status.

The infusion of intraarterial papaverine into a vascular bed actively in a state of vasospasm proved to be a safe and useful adjunct in the treatment of this complicated trauma patient. The effectiveness of papaverine used in this manner offers some unique advantages in critically injured trauma patients who are deteriorating neurologically and have had maximal

medical and surgical treatment. The clinical and angiographic results, although transient, show promise and should be cause for further investigation.

## References

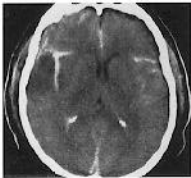1. McCullough D, Nelson KM, Ommaya AK. The acute effects of experimental head injury on the vertebrobasilar circulation: angiographic observations. *J Trauma* 1971;11:422–428
2. Wilkins RH. Intracranial vascular spasm in head injuries. In: Vinken PJ, Bruyn GW, eds. *Handbook of Clinical Neurology, I: Injuries of the Brain and Skull*. Amsterdam: North Holland, 1975;23:163–165
3. Wilkins RH. Trauma-induced cerebral vasospasm. In: Wilkins RH, ed. *Cerebral Arterial Spasm: Proceedings of the Second International Workshop, Amsterdam, The Netherlands*. Baltimore: Williams and Wilkins, 1980;472–475
4. Wilkins RH, Odom GL. Intracranial arterial spasm associated with craniocerebral trauma. *J Neurosurg* 1970;32:626–633
5. Suwanwela C, Suwanwela N. Intracranial arterial narrowing and spasm in acute head injury. *J Neurosurg* 1972;36:314
6. Pal J. Das papaverine als gefamittel und anastheticum. *Deutsch Med Wsehr* 1914;40:164–168
7. Ogata M, Marshall BM, Loughheed WM. Observations on the effects of intrathecal papaverine in experimental vasospasm. *J Neurosurg* 1973;38:20–25
8. Kuwayama A, Zervas NT, Shintani A, Pickren KS. Papaverine hydrochloride and experimental hemorrhagic cerebral arterial spasm. *Stroke* 1972;3:27–33
9. Eckard DA, Purdy PD, Giron MS, Samson D, Kopitnik T, Batjer H. Intraarterial papaverine for relief of catheter-induced intracranial vasospasm. *AJNR Am J Neuroradiol* 1992;58:883–884
10. Kaku Y, Yonekawa Y, Tsukahara T, Kazekawa K. Superselective intra-arterial infusion of papaverine for the treatment of cerebral vasospasm after subarachnoid hemorrhage. *J Neurosurg* 1992;77:842–847
11. Kassell NF, Helm G, Simmons N, Phillips CD, Cail W. Treatment of cerebral vasospasm with intraarterial papaverine. *J Neurosurg* 1992;77:848–852
12. Higashida RT, Halbach VV, Cahan LD, et al. Transluminal angioplasty for treatment of intracranial arterial vasospasm. *J Neurosurg* 1989;71:648–653
13. Newell DW, Eskridge JM, Mayberg MR, et al. Angioplasty for the treatment of symptomatic vasospasm following subarachnoid hemorrhage. *J Neurosurg* 1989;71:654–660
14. Zubkov YN, Nikiforov BM, Situstin VA. Balloon catheter technique for dilatation of constricted cerebral arteries after aneurysmal SAH. *Acta Neurochir* 1984;70:65–79



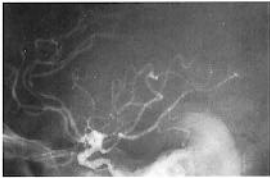A



C



B



D