AJNR

The Stockholm School of Neuroradiology.

E Lindgren and T Greitz

AJNR Am J Neuroradiol 1995, 16 (2) 351-360
http://www.ajnr.org/content/16/2/351.citation

HISTORY

The Stockholm School of Neuroradiology

Erik Lindgren and Torgny Greitz, *Department of Neuroradiology, Karolinska Institutet, Stockholm, Sweden*

When we were asked by the editor of the *AJNR* to write the story of the "Stockholm School" of neuroradiology, he suggested that we try to explain the circumstances that alowed neuroradiology to develop faster in Sweden than elsewhere and how it came about that Swedish radiologists were performing pneumoencephalographies, angiographies, and myelographies themselves while these procedures were still done by neurosurgeons in other countries.

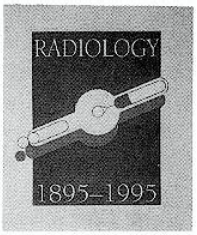

First we would like to begin with an attempt to define what we mean by the Stockholm School of neuroradiology. This concept was introduced by one of the present authors in a survey of the history of neuroradiology published in the textbook of Newton and Potts in 1971 (1). The foundations of the research and teaching center at the Serafimer Hospital (Fig 1), which was to become the Stockholm School of neuroradiology, were laid down in the 1930s, and the role of this center as a "mecca" of neuroradiology was established in the 1940s. In the 1950s neuroradiologists trained at the Serafimer headed centers elsewhere in Sweden (eg, in Gothenburg and Lund), and these centers also received many visiting scientists and trainees in neuroradiology. From that time it would perhaps be more appropriate to speak about a Swedish school of neuroradiology. However, all the "neuro" specialties at the Serafimer moved to the Karolinska Hospital in 1963, and we believe that the work done there and that done at the Serafimer together represent a continuum and may be regarded as a product of one and the same research and teaching center, which we would like to call the Stockholm School of neuroradiology (Fig 2).

Why did this development start in Stockholm and not elsewhere in Sweden or in Europe? The first and main prerequisite was the fact that an independent department of neurology had been created at the Serafimer Hospital and was headed by a professor of neurology at the Karolinska Institute as early as 1887. Outside France, independent departments of neurology of a corresponding importance did not exist in Europe or in other parts of Sweden. This also explains why the first neurosurgical operations in Sweden were performed in Stockholm.

To understand the background of the early and rapid advancement of neuroradiology in Sweden, one has to consider three additional main contributing factors. First, the unique early organization of diagnostic radiology in Sweden; second, the close cooperation, based on mutual confidence and respect, between the radiologists and the referring clinicians; and third, the intimate relationships between the pioneers in radiology and the Swedish roentgen industry.

The man who had the main responsibility for the way the roentgen departments became organized in Sweden was Gösta Forsell. Forsell became the first director of the Roentgen Institute at the Serafimer in 1908; he was granted a "personal professorship" in 1917 and occupied the first chair in medical radiology in Sweden in 1926. Thanks to the authority and the high esteem that he enjoyed, Forsell managed to convince the authorities that each hospital should have only one x-ray department, and the heads of the roentgen departments in Sweden should have exactly the same position as other clinical heads. In most European countries, as well as in the United States, each clinical specialty had its own small roentgen department, *usually run by clinicians* who had no special training and were aided by technicians. The Swedish organization meant that specially trained radiologists took the full responsibility not only for the "interpre-

Address reprint requests to Torgny Greitz, MD, Department of Neuroradiology, Karolinska Sjukhuset, S-171 76 Stockholm 60, Sweden.

AJNR 16:351–360, Feb 1995 0195-6108/95/1602–0351



Fig 1. The entrance to the Serafimer Hospital, built in 1752.

tation" of the images, but also for the choice of technique, including the risk of complications involved. Because the procedures used within neuroradiology were to become more risky than those used in other fields of radiology, the referring doctors who were accustomed to a certain risk of complications at interventional procedures (ie, the surgeons), were reluctant to transfer the full responsibility from themselves to radiologists. To do so was considered appropriate only in Sweden, and gradually also in the other Scandinavian countries, first in Norway and later in Denmark. The independence of the roentgen department may be said to be the key that opened the door for the Swedish pioneers into the area of technical development of radiology. Swedish radiologists soon began to think in terms of new methodology and had no restriction for the implementation of their ideas other than their own responsibility toward their patients.

Forsell was a great organizer, but he took little part in the daily work of his department. He is sometimes referred to as one of the pioneers in neuroradiology, because he was the first to examine a case of dilatation of the internal auditory meatus caused by an acoustic neuroma. However, Henschen, a pathologist, had observed these changes at autopsy (2) and suggested that it should be possible to demonstrate the widening at roentgen examination.

The foundations of Swedish neuroradiology were laid down by Forsell's coworkers, and the first name that should be mentioned in this context is Erik Lysholm. Lysholm had worked at the roentgen department of the Serafimer Hospital between 1921 and 1925 and then moved to a hospital outside Stockholm but returned to the Serafimer in 1930, when he started to work with the neurosurgeon Herbert Olivecrona, an early and prominent pioneer of neurosurgery in Europe. It therefore seems appropriate to consider the year 1930 as the starting point for the Stockholm School of neuroradiology. Lysholm also had a close working relationship with an engineer, Georg Schönander, founder of the Schönander factory, later named the Elema-Schönander AB. The cooperation between these men was most fruitful and continued into the era of their followers—the present authors have for many years enjoyed the collaboration with the chief research engineer at this Swedish industry, Georg Fredzell. Lysholm introduced the stationary grid, still in use in all roentgen departments; the total number of sales is now approaching a half-million. Lysholm's skull table, presented in 1931, was the first precision apparatus for roentgenography (3) (Fig 3). With the aid of this apparatus, a large number of pneumographic examinations were performed in the early 1930s by the Stockholm School. These examinations were made according to strict principles as to the technique used but



Fig 2. Three directors of the Stockholm School of Neuroradiology. *A*, Erik Lysholm, director, 1930 to 1947; *B*, Erik Lindgren, 1947 to 1963; *C*, Torgny Greitz, 1963 to 1987.

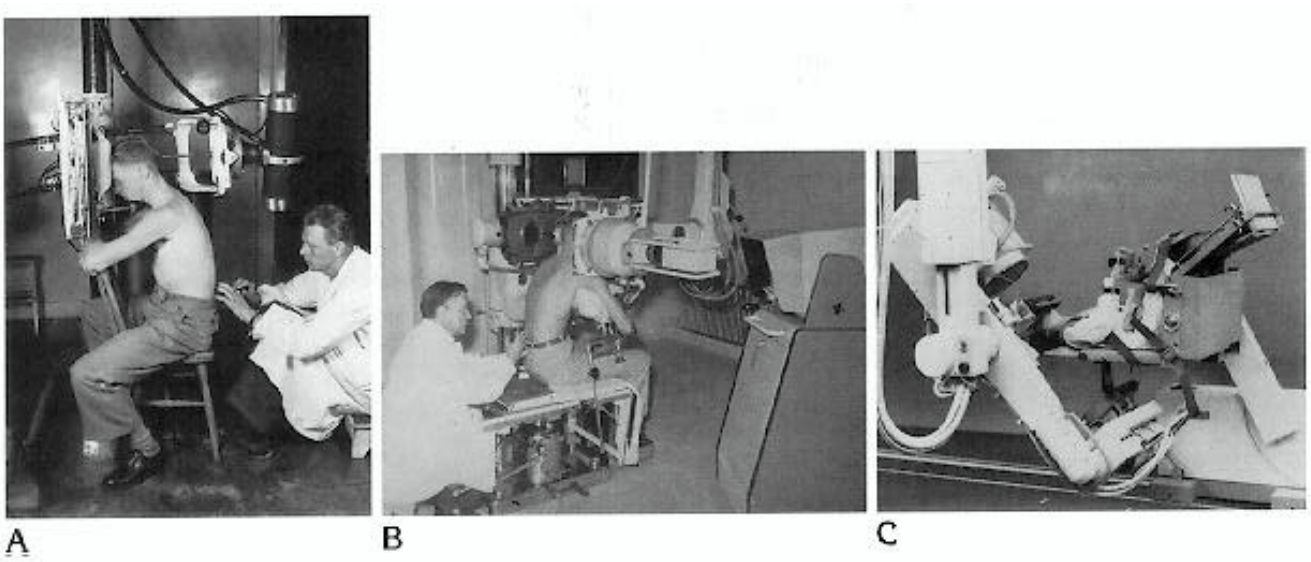

Fig 3. *A*, Pneumoencephalography using the Lysholm skull table. Ingmar Wickbom performs the lumbar puncture in 1950. Note the primitive auxiliary equipment, the wooden chair for the patient, and the stool for the examiner.

B, Pneumoencephalography with Mimer II; photo taken in the early 1960s at the Serafimer. Injection of air was now controlled with an image intensifier. The examiner is Sven-Erik Sjögren. The patient is sitting on a specially designed table, which could be turned into a horizontal bed (couch) for the continued procedure.

C, The Mimer III came equipped with a rotating chair for somersaulting of the patient during pneumoencephalography to fill the ventricular system and the cisterns "fraction by fraction."

with the understanding that each case constituted a special problem that required variation and individualization of the positioning and exposure techniques. The common approach to pneumography in the early days had been to use large quantities of air to fill up the ventricular system as much as possible. At the Serafimer, a comparatively small amount of air was used and was moved to various parts of the ventricular system. The images obtained of these individual parts were drawn together into a composite "total image" of the case. These drawings were then compared with the findings at operation and at autopsy.

Lysholm and coworkers presented the results obtained in "Das Ventrikulogram," published under three separate covers from 1935 to 1937 (4–6). These books, which later appeared in an English translation, soon became regarded as a "bible" of neuroradiology and significantly contributed to the fame of the Serafimer and the Stockholm School.

It was not long before the accuracy and precision in the diagnostic work-up of patients, gained by these technical improvements, became obvious to the neurosurgeons. Olivecrona had commenced doing neurosurgical operations in the mid-1920s and opened a department of neurosurgery at the Serafimer hospital in 1930. He always showed great confidence in the radiologists—as they did in him—and this mutual respect evidently formed the basis for the continued success of both specialties.

The rumour about the outstanding results of treatment at the Serafimer spread internationally. In an address recently given before the European Society of Neuroradiology, Ian Mosely, the present director of the Lysholm Department of Radiology in London, related the following:

> When my mentor James Bull went to Sweden in the late 1930s to learn neuroradiology, he did so because Wiley McKissock, the neurosurgeon who wanted his services, sent him. When Wiley first went to Stockholm, he asked: 'How do the surgeons always open the head over the lesion? Why don't they ever look on the wrong side for a subdural haematoma with ipsilateral signs, or mistake frontal ataxia for a cerebellar tumour?' The answer was that they had a clever young man who took x-ray pictures of the patient and told them where to make their incision. This was Erik Lysholm, whose name James Bull gave to the department of which I have recently received the honour of being the fifth director.

However, when Mosely went on to say that "Lysholm shared his knowledge not only with radiologists but also with neuroradiologist and neurosurgeons so that they could now localize space occupying lesions for themselves," he is

misinformed. From the very beginning up to the present time the neuroradiologists of the Stockholm school have had the responsibility for the entire diagnostic procedure (with the exception of ventricular puncture), including the evaluation or "interpretation" of the images, in the same sense that the neurosurgeons were responsible for their operations. We think it is important to stress the fact that this distinction between the responsibilities existed, because it obviously played an important role for the rapid development of neuroradiology—as well as neurosurgery—in Sweden. James Bull was one of the very first foreign radiologists who came to Sweden to learn neuroradiology. Even after the death of Lysholm in 1947, visitors continued to come to the Serafimer, now under the leadership of Erik Lindgren. Such well-known neuroradiologists as Giovanni di Chiro, Giovanni Ruggiero, Sigurd Wende, and Nestor Azambuja—all of them like James Bull presidents of a Symposium Neuroradiologicum—trained at the Serafimer and regard themselves as pupils of Lindgren. And many others spent time with us there, such as Gordon Gryspeerdt, David Sutton, Philip Sheldon, Jaqueline Vignaud, and August Wackenheim, as well as several American radiologists: Al Smith, Elliot Lasser, James Galloway, and Robert A. Zimmerman, to mention a few. And people continued to come to Sweden when neuroradiology moved over from the Serafimer to the Karolinska Hospital in 1963 and Torgny Greitz became head of the department (a position that he held until 1987). Among Americans, Hans Newton, Stewart Reuter, Tryggve Gabrielsen, and Ronald Ross joined the department at the Karolinska for brief periods.

As already mentioned, neuroradiologists who trained at the Serafimer later headed centers elsewhere in Sweden, such as in Gothenburg (Wickbom) and Lund (Cronquist), and these centers also received many visiting scientists and trainees in neuroradiology. Among those trained in Gothenburg, one may mention William Hanafee, Fred Hodges III, and Mark Mishkin, and among those who took to Lund, Sidney Wallace and Vincent Hinck.

Why was it that Sweden could attract so many during several decades? Apart from the high standard of the routine work, the quality of the achievements in research and technical developments are an important reason. It would not be to much to say that most of the "old" methods used within neuroradiology, albeit not introduced in Sweden, were brought to perfection by the Stockholm School.

Lysholm had used ventriculography for air studies. In the late 1940s, cisternal punctures were used for pneumoencephalography, but after 1950 this technique was abandoned to be replaced by lumbar puncture, which was considered safer. It was shown that the lumbar approach could be used, even in the presence of increased intracranial pressure, providing burr holes were made in the vault before the examination. With this precaution taken, immediate ventricular puncture could be made to lower the pressure when necessary. A technique for pneumoencephalography (7) was worked out that allowed for taking standardized projections and a complete and correct work-up of the anatomy of the intracranial cerebrospinal fluid (CSF) spaces, including the temporal horns and the subarachnoid cisterns, areas that had not received sufficient attention by previous investigators. The use of cerebral angiography became more widespread with the introduction of water-soluble contrast media, less toxic than the sodium iodide used by Moniz, and with the use of direct percutaneous puncture of the artery. In Stockholm, techniques for percutaneous angiography of the carotid and vertebral arteries (8–10) were worked out (Fig 4), taking advantage of the precision of the Lysholm skull table, which was equipped with a manual casette changer for three views. The first extensive clinical studies of carotid angiography (11, 12) and vertebral angiography (9) with the percutaneous approach were published in Scandinavia.

The first cerebral angiograms made with catheterization were performed in Lund by Radner (13), who used the brachial approach for angiography of the vertebral artery. Lindgren, in 1954, introduced catheterization of the vertebral artery via the femoral artery (14), this representing the first cerebral angiographies made by this approach. Amundsen of Norway was the first to catheterize and examine routinely all cerebral vessels, carotid as well as vertebral arteries, via the femoral route, a technique that he had been using at the Rikshospitalet in Oslo since 1964 (15). Newton learned about this when Amundsen introduced this routine in Newton's department at the University of California Hospital in San Francisco while Newton was in Sweden in 1966. Newton made the first cathe-



4

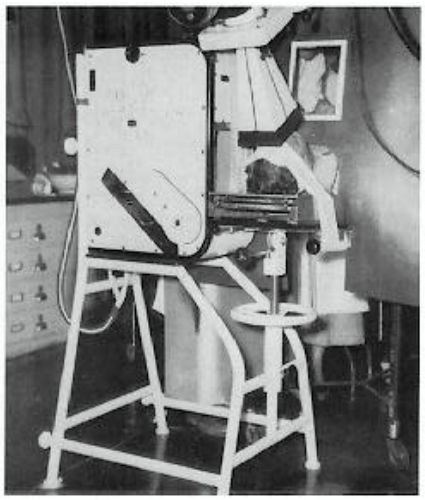

5

Fig 4. The Lysholm skull table equipped with a manual casette changer for angiography, 1955. Torgny Greitz is introducing the needle into the carotid artery, assisted by Elliot Lasser, American guest scientist, now emeritus professor of radiology in San Diego. Rapid serial angiography was not yet a routine. The following year, Lasser became professor (and chairman) of radiology at the University of Pittsburgh.

Fig 5. The first cut-film changer. This apparatus, the AOT changer, specially designed for rapid serial cerebral angiography, was presented in 1952. A manual changer was still used at this time for the anteroposterior projections, because no changer for frontal projections had yet been constructed.

terization of the carotid artery from the femoral at the Karolinska in 1966 when he came back from a 1-week visit to Oslo.

The necessity of rapidly changing a large number of films to allow a precise study of the circulatory conditions had been realized already in the 1940s (16, 17), but such studies were hampered by the absence of suitable film changers. The cut-film changer, specially designed for cerebral angiography and presented by Fredzell and Sjögren (18) at the Symposium Neuroradiologicum in Stockholm in 1952, and still in use all over the world (originally manufactured by the Schönander AB, now by Siemens AS), met an obvious need and brought rapid serial angiography into the routine work of the neuroradiologists (Fig 5). Rapid serial angiography may be said to have paved the way for another methodological advancement, the subtraction technique, a method suggested in a thesis by Ziedses des Plantes in 1934 but more or less forgotten and then reintroduced at the Symposium in Rome in 1961 (19–21), when its use as a routine tool in conjunction with rapid serial angiography was emphasized by the Stockholm School.

In the early days iodized oil was introduced and used extensively worldwide as a contrast medium in the subarachnoid space, both for myelography and for ventriculography in the diagnosis of lesions of the posterior fossa. The Stockholm School took a stand against the use of these contrast media at an early stage, and they were hardly ever used in Sweden. Considering the number of cases of postmyelographic arachnoiditis that are now reported, this may seem to have been a wise decision. As a result of this attitude, oily contrast media were hardly ever used for myelography in Sweden. At the Serafimer, gas (air or oxygen) was used, and the myelographic technique was worked out by Lindgren (22) and later modified by Westberg (23) to allow the differentiation between cystic and solid cord lesions.

The interest in technical achievements was kept alive within the Stockholm School even after the transfer of the activities from the Serafimer to the Karolinska in 1963. In cooperation with Fredzell, now at the Elema factory, the construction of a new apparatus for neuroradiologic examinations had begun at the Serafimer and was continued at the Karolinska and resulted finally in the Mimer III (24, 25). This apparatus allowed "instant fluroscopy" and "instant tomography" during pneumoencephalography, as well as easy positioning of the patient thanks to the rotating chair combined with the unit.

The Mimer III also proved suitable for myelography as well as interventional procedures, such as percutaneous cordotomy and blocking of the trigeminal nerve in neuralgia, and it is still used for these purposes.

During the last decades, during which we have witnessed the changing face of neuroradiology, the Stockholm School has not played the same prominent role for the technical developments as before, albeit some noticeable contributions have been made. The Karolinska had its computed tomographic (CT) scanner installed

6

7

Fig 6. Godfrey Hounsfield and Torgny Greitz flanking the EMI scanner at the department of neuroradiology, Karolinska Hospital. This unit was the first in Europe outside Great Britain. The photo was taken while Hounsfield was in Stockholm to receive the Nobel Prize in Medicine.

Fig 7. Faculty of a refresher course in neuroradiology, organized by Mannie Schechter at the Albert Einstein College of Medicine, New York, May 15–24, 1966. In the 1950s and 1960s, neuroradiologists trained at the Stockholm School were invited as lecturers to many refresher courses in the United States. The names of the "Serafimers" are in italics. *Sitting, left* to *right: Giovanni di Chiro*, Harold Peterson, Leo Davidoff, Harold Jacobson, Harry Zimmerman, Mannie Schechter, and *Alan Zimmer. Standing: Sten Cronqvist*, Bernard Epstein, Lauslevee Zingesser, Milton Elkin, *Ingmar Wickbom, Torgny Greitz*, Colin Holman, D. L. McRae, Ernest Wood, and *James Bull.*

in 1973 (Fig 6)—first on the European continent—and members of the department were the first to publish methodological innovations such as CT cisternography (26), CT angiography (27), dynamic CT (28), and stereotactic CT (29). The implementation of stereotactic methods as well as the integration of all imaging methods used for diagnostic and therapeutic purposes was facilitated by the introduction of a system for reproducible noninvasive head fixation (30).

Also, the inherent capacity of CT for diagnosis using radionuclides was realized very early. The world's third positron emission tomography unit, a ring camera, was installed in the department of neuroradiology in 1977 and had been built in cooperation with the department of physics at Stockholm University (31). A later version of this positron emission tomographic camera was sold commercially by the Swedish manufacturer Scanditronix AB and was installed at several leading positron emission tomography centers in Europe as well as in the United States. With the department of physics, an adjustable computerized brain atlas was developed particularly for use in functional neuroimaging (32, 33).

The high diagnostic accuracy that was the reason for the early and long-lasting fame of the Stockholm School was based not only on the technical improvements but also on the implementation of guidelines for diagnostic work, based on the philosophy of the school. This implied that a radiologic diagnosis should be based on objective facts; that is, on the anatomic—or physiologic—changes observed on the radiograms. This meant that intimate knowledge of the anatomy of the central nervous system was considered a *conditio sine qua non*.

When pneumography and angiography became more widely used in the late 1940s, it was realized that adequate and sufficient knowledge of the anatomy of the central nervous system and its variations could not always be gained from anatomy textbooks. Over the following years, a series of anatomic investigations were carried out by the Stockholm School, based on the combined use of dissections of anatomic specimens and roentgen examinations, both postmortem and in vivo.

The interest was first focused on the CSF spaces. The normal anatomy and its variations were described with regard to the temporal horn (34), the sylvian aqueduct (35), the third ventricle (36), the fourth ventricle (37), and the subarachnoid cisterns (38), and the knowledge gained by these studies was used to increase the accuracy in locating space-occupying lesions.

Attention was also directed toward vascular anatomy. The first more-or-less white spot on the map to be explored was the central veins and the deep dural sinuses, which were the subject of a thorough radiologic-anatomic study by Curt Johanson in 1954 (39). This was the starting point for a series of roentgenographic-anatomic investigations of the vascular anatomy of the brain. This type of penetrating analysis has been taken up particularly by Salamon in France and Huang in the United States with regard to the arteries and veins of the posterior fossa.

In a series of papers published in the 1960s, the Stockholm School presented an anatomic and radiographic description of all major central arteries and some of the meningeal arteries, several of which were not described correctly, or at all, in the previous anatomic literature, such as the anterior choroidal artery (40), the medial and lateral (posterior) choroidal arteries (41), the posterior inferior cerebellar artery (42), the posterior pericallosal artery (43), the arteries of the basal ganglia (44, 45), the meningeal branches of the ophthalmic artery, including the anterior meningeal artery (46), and the anterior meningeal branch of the vertebral artery (47). Also, the normal size of the internal carotid artery including its main branches was assessed (48).

It seems as though anatomists, before the discovery of x-rays and before the appearance of neurosurgery, had a limited interest in the cerebral vessels, which could explain the incomplete and partly incorrect description in the anatomy textbooks. Neuroradiologists, not only in Sweden, but also in the United States and France, today are responsible for the most adequate descriptions of the gross anatomy of the brain vessels and their variations. Unfortunately, the errors of the older descriptions in anatomy textbooks still prevail in many modern anatomy books, and they are regretfully to be found also in modern handbooks of neuroradiology. As an example, it seems not to be fully appreciated that the so-called posterior choroidal artery consists of two separate vessels: one artery originating medial to the main trunk of the posterior cerebral artery and running toward the midline supplying the plexus in the roof of the third ventricle, and one or two vessels originating lateral to the main trunk of the posterior cerebral artery running in the choroidal fissure and supplying the posterior part of the plexus of the temporal horn. No one of the numerous artists drawing sketches of the thalamostriate arteries seems to have been informed about the fact that these vessels, like the artery of Heubner, have a recurrent course at their origin.

The Stockholm School has been acknowledged for bringing physiology into neuroradiology. Lysholm had a keen interest in the use of radioactive isotopes in diagnostic work, which probably contributed to the early introduction of radionuclide scanning at the Serafimer (49). Lysholm planned to use isotopes for the study of brain circulation. Greitz, when measuring cerebral circulation time by rapid serial angiography, compared the results with those obtained using a radioactive nondiffusible tracer (50). This study pointed to the importance of circulatory changes as indicators of intracranial disease. As an example, the angiographically determined circulation at times proved to be more sensitive in revealing the presence of a pathologic lesion than were the global flows measured with the xenon clearance method (51). The isotope method of Greitz led to other methods of studying regional cerebral circulation, such as Oldendorf's method of measuring cerebral transit time (52) and the xenon clearance method of Lassen and Ingvar (53).

Interest in the CSF circulation was evoked in the 1960s by the introduction of isotope cisternography by Di Chiro (54), and by the new concept of "normal pressure" hydrocephalus. The normal CSF circulation in children was described in relation to the pattern in adults (55), and the anatomic (pneumographic) criteria for communicating hydrocephalus, as opposed to cerebral atrophy, were defined (56). With hydrocephalus, a general decrease was found in circulation time as well as in cerebral blood flow, changes that could be more or less normalized after shunting (57, 58). The first report of the possibility of demonstrating the CSF circulation using magnetic resonance imaging was published by Bergstrand and coworkers in 1985 (59) and was presented at the Symposium Neuroradiologicum in Stockholm in 1986. Recently, a modified model for the CSF circulation has been proposed by the Stockholm school (60), based on an observation made mainly with magnetic resonance and suggesting that the main absorption is through the central nervous system.

Although the premier achievements of the Stockholm School may be the aspects of meth-

odology and normal anatomy and physiology there is no doubt that the experience gained in many instances has contributed to a better characterization of many pathologic processes. This facilitated not only the radiologic diagnosis but also the clinical delimitation and definition of many lesions in the central nervous system. This could be said particularly about lesions of the posterior fossa, as these have been the subject of many investigations (61–65) (Lindquist M, "Cisternal Abnormalities Produced by Tumours in the Posterior Cranial Fossa," Umeå, Umeå University, 1980;51:1–31, thesis). The success of Olivecrona relied, as was pointed out by Mosely, on the accurate diagnoses of his patients and allowed him to systemalize his experiences to avoid further mistakes in his treatment. Also, it became easier to understand the clinical symptoms occurring with various types of transtentorial herniations, when these could be studied and classified in vivo (66). The differential diagnosis between the flaccid, hydromyelic cysts and the tense tumor cysts of the cord led to the implementation of a treatment of tumor cysts by percutaneous puncture (23)—a kind of interventional neuroradiology that seems to be more or less forgotten in these days when only so-called surgical angiography seems to be looked on as interventional neuroradiology. Also, the evidence that atherosclerosis and arteriectasia are two distinct and different entities as shown by angiography, histologic investigations, and determinations of the blood triglycerides (Ryttman A, "Atherosclerosis and Ectasia Estimated by Cerebral Angiography and Related to Plasma Lipid Concentration and Cerebral Blood Flow," Stockholm, 1975:1–23, thesis) seems to have escaped attention. (Now, when the new aspects of the CSF circulation have initiated a discussion on the cause and treatment of hydrocephalus, let us hope that it will continue so that these new aspects will not fall into oblivion).

In the letter inviting us to write a historical vignette about the Stockholm School of neuroradiology, Dr Huckman writes that he hopes that we will "include the names of the non-Scandinavian neuroradiologists who trained there and what the experience was like for them, and for you, and how that influenced the practice of neuroradiology in other countries." Many names of the foreign visitors have already been mentioned, but the important role that these colleagues played for the development and the fame of Stockholm School of Neuroradiology deserves to be reemphasized. The names Di Chiro, Ruggiero, Roullaud, Azambuja, Galloway, Kuru, Ross, Newton, Reuter, Gabrielsen, Corrales, Hatam, Bajraktari, Riding, White, Doyon, Voigt, Kingsley, Tampieri, Haberbeck, Jedrezejczak, and Poskitt all represent individuals who added to our knowledge by their work in Stockholm and contributed significantly to the prestige of our institutions by publishing their results in the international literature.

An important role of the early visitors was to spread information about the way neuroradiology was conducted in Sweden (Fig 7). The first to "preach the gospel" was James Bull when he returned from Stockholm to England. Important contributions were made by Ruggiero, who, after having left Sweden, first worked in France and then returned to Italy, his native country, and by Di Chiro, who became a leading scientist in the United States. Thus the influence of the Stockholm School of neuroradiology reached Europe earlier than the United States. The break through in the United States came in 1955, after the Symposium in London, and after a series of lectures that Erik Lindgren gave when he toured several of the most important neurocenters in the United States at the end of 1955. As a result of this, Torgny Greitz was invited in 1956 to spend a year at the Mallinkrodt Institute of Radiology. Taveras wrote the following about this in an essay (67) in the *AJNR* on the occasion of the 25th anniversary of the ASNR:

> . . .and slowly, partly because of the stimulus engendered by the IV Symposium Neuroradiologicum. . .more radiologists in this country became interested in the subspecialty and some of them sought training outside the United States. In the late 1950s, Torgny Greitz, from Sweden, was invited to come to the Mallinkrodt Institute of Radiology at Washington University to spend a couple of years practicing and teaching neuroradiology. At that time, neuroradiology in Europe, and particularly in Sweden was far more developed than in the United States. . .

The dominance of the Stockholm School of neuroradiology as a research and teaching institution at that time may be further illustrated by the fact that 8 of the 15 presidents of the Symposia were trained at the Serafimer.

The transactions of the Symposia were formerly always published in *Acta Radiologica*. This journal, edited by Lindgren, had the position as the leading—and only—neuroradiological journal but lost this status when *Neuroradi-*

ology and *AJNR* were launched. After 1974 only one Symposium, that in Stockholm, had its proceedings published in *Acta Radiologica*. The dissertations from the Serafimer (Stockholm School) were published in supplements of *Acta Radiologica*, and Di Chiro has described the eagerness with which one in the 1950s looked forward to each additional yellow copy of this series of supplements—each containing new and important information. In this way *Acta Radiologica* contributed to enforce the impression of Sweden, and particularly Stockholm, as the "mecca of neuroradiology."

References

1. Lindgren E. A history of neuroradiology. In: Newton, Potts, eds. *Radiology of the Skull and Brain. Skull.* Vol 1, Book 1. St Louis: C. V. Mosby, 1971:1–25
2. Henschen F. Die Akustikustumoren, eine neue Gruppe radiografisch darstellbarer Hirntumoren. *Fortschr Roentgenstr* 1912; 18:207–216
3. Lysholm E. Apparatus and technique for roentgen examination of the skull. *Acta Radiol* 1931;Suppl 12:1–120
4. Lysholm E, Ebenius B, Sahlstedt H. Das Ventrikulogramm. I Teil. Röntgentechnik. *Acta Radiol* 1935;Suppl 24:1–75
5. Lysholm E, Ebenius B, Lindblom K, Sahlstedt H. Das Ventrikulogramm. II Teil. Dritter und vierter Ventrikel. *Acta Radiol* 1937; Suppl 26:1–199
6. Lysholm E, Ebenius B, Sahlstedt H. Das Ventrikulogramm. III Teil. Die Seitenventrikeln. *Acta Radiol* 1935;Suppl 25:1–124
7. Lindgren E. Some aspects on the technique of encephalography. *Acta Radiol* 1949;31:161–177
8. Lindgren E. The technique of direct (percutaneous) cerebral angiography. *Br J Radiol* 1947;20:236
9. Lindgren E. Percutaneous angiography of the vertebral artery. *Acta Radiol* 1950;33:389–404
10. Sjögren SE. Percutaneous vertebral angiography. *Acta Radiol* 1953;40:113–127
11. Engeset A. Cerebral angiography with Perabrodil (carotid angiography). *Acta Radiol* 1944;Suppl 56:1–207
12. Wickbom I. Angiography of the carotid artery. *Acta Radiol* 1948; Suppl 72:1
13. Radner S. Vertebral angiography by catheterization. *Acta Radiol* 1951;Suppl 87:1–134
14. Lindgren E. Another method of vertebral angiography. *Acta Radiol* 1956;46:251–257
15. Amundsen P, Dugstad G, Noyes W. Cerebral angiography via the femoral artery with particular reference to cerebrovascular disease. Proceedings of the 18th Congress of Scandinavian Neurologists, Helsinki. *Acta Neurol Scand* 1967;43(Suppl 31):115
16. Curtis J. Rapid serial angiography. *J Neurol Neurosurg Psychiatry* 1949;12:167–181
17. Schurr P, Wickbom I. Rapid serial angiography. Further experience. *J Neurol Neurosurg Psychiatry* 1952;15:110–118
18. Sjögren SE, Fredzell G. Apparatus for rapid serial angiography. *Acta Radiol* 1953;40:361–368
19. Ziedses des Plantes BG. Planigraphy and Subtration. Roetgenographic differentiation methods (translated from Dutch). In: *Collected works of B. G. Ziedses des Plantes.* Amsterdam: Excerpta Medica, 1973:9–84
20. Ziedses des Plantes BG. Application of the roentgenographic subtraction method in neuroradiology. *Acta Radiol Diagn* 1963;1: 961–966
21. Ziedses des Plantes BG. The application of the subtraction method to cerebral angiography. In: *Collected Works of B. G. Ziedses des Plantes.* Amsterdam: Excerpta Medica, 1973;115–122
22. Lindgren E. On the diagnosis of tumors of the spinal cord by the aid of gas myelography. *Acta Chir Scand* 1939;82:303–318
23. Westberg G. Gas myelography and percutaneous puncture in the diagnosis of spinal cord cysts. *Acta Radiol* 1966;Suppl 252:1–67
24. Fredzell G, Lindgren E. Mimer. *Acta Radiol* 1960;53:209–214
25. Fredzell G, Greitz T, Grepe A, et al. Mimer III and rotating chair. *Acta Radiol Diagn* 1968;7:543–552
26. Greitz T, Hindmarsh T. Computer assisted tomography of intracranial CSF circulation using a water-soluble contrast medium. *Acta Radiol Diagn* 1974;15:497–507
27. Riding M, Bergström M, Bergvall U, et al. Computer intravenous angiography. *Acta Radiol* 1975;Suppl 346:82–90
28. Hatam A, Bergvall U, Lewander R. Contrast medium enhancement with time in computer tomography. *Acta Radiol* 1975;Suppl 346:63–81
29. Bergström M, Greitz T. Stereotaxic computed tomography. *AJR Am J Roentgenol* 1976;127:167–170
30. Greitz T, Bergström M, Boëthius J, et al. Head fixation system for integration of radiodiagnostic and therapeutic procedures. *Neuroradiology* 1980;19:1–6
31. Eriksson L, Bergström M, Bohm C, et al. A ring detector positron camera system: its merits; clinical experience. *Neuroradiology* 1978;16:572–574
32. Bohm C, Greitz T, Kingsley D, et al. Adjustable computerized stereotaxic brain atlas for transmission and emission tomography. *AJNR Am J Neuroradiol* 1983;4:731–733
33. Greitz T, Bohm C, Holte S, et al. A computerized brain atlas: construction, anatomical content, and some applications. *J Comput Assist Tomogr* 1991;15:26–38
34. Lindgren E. A pneumographic study of the temporal horn with special reference to tumours in the temporal region. *Acta Radiol* 1948;Suppl 69:1–151
35. Lindgren E, Di Chiro G. The roentgenologic appearance of the aqueduct of Sylvius. *Acta Radiol* 1953;39:117–125
36. Greitz T, Löfstedt S. The relationship between the third ventricle and the basilar artery. *Acta Radiol* 1954;42:85–100
37. Corrales M, Greitz T. Fourth ventricle, I: a morphologic and radiologic investigation of the normal anatomy. *Acta Radiol Diagn* 1972;12:113–133
38. Liliequist B. The subarachnoid cisterns. *Acta Radiol* 1959;Suppl 185:1–108
39. Johanson C. The central veins and deep dural sinuses of the brain. An anatomical and angiographic study. *Acta Radiol* 1954;Suppl 107:1–184
40. Sjögren SE. The anterior choroidal artery. *Acta Radiol* 1956;46: 143–157
41. Galloway J, Greitz T. The medial and lateral choroid arteries. An anatomic and roentgenographic study. *Acta Radiol* 1960;53:353–366
42. Greitz T, Sjögren SE. The posterior inferior cerebellar artery. *Acta Radiol Diagn* 1963;1:284–297
43. Galloway J, Greitz T, Sjögren SE. Vertebral angiography in the diagnosis of ventricular dilatation. *Acta Radiol Diagn* 1964;2: 321–333
44. Westberg G. The recurrent artery of Heubner and the arteries of the central ganglia. *Acta Radiol Diagn* 1963;1:949–954
45. Westberg G. Arteries of the basal ganglia. *Acta Radiol Diagn* 1966;5:581–596

46. Kuru Y. Meningeal branches of the ophthalmic artery. *Acta Radiol Diagn* 1967;6:241–251
47. Greitz T, Laurén T. Anterior meningeal branch of the vertebral artery. *Acta Radiol Diagn* 1968;7:219–224
48. Gabrielsen T, Greitz T. Normal size of the internal carotid, middle cerebral and anterior cerebral arteries. *Acta Radiol Diagn* 1970; 10:1–10
49. Sjögren SE. Experience in localisation of brain tumours by means of diiodo^{131} fluorescein. *Acta Radiol* 1953;40:356–360
50. Greitz T. A radiologic study of the brain circulation by rapid serial angiography of the carotid artery. *Acta Radiol* 1956;Suppl 140: 1–123
51. Cronqvist S, Greitz T. Cerebral circulation time and cerebral blood flow. Comparison of angiography and the 133-Xe technique. *Acta Radiol Diagn* 1969;8:296–304
52. Oldendorf W. "Transit time" methods. In: Gilson A, Smoak W, eds. *Central Nervous System Investigated with Radionucleids.* Springfield: Charles C. Thomas, 1971:203–213
53. Raichle M. The circulatory and metabolic correlates of brain function in normal human subjects. In: Plum F, ed. *Handbook of Physiology, Section V, Higher Functions of the Nervous System.* Bethesda: American Society of Physiology, 1987:643–673
54. Di Chiro. Movement of the cerebrospinal fluid in human beings. *Nature* 1964;204:290–291
55. Henriksson L, Voigt K. Age dependent differences of distribution and clearance patterns in normal RIHSA cisternograms. *Neuroradiology* 1976;12:103–107
56. Greitz T, Grepe A. Encephalography in the diagnosis of convesity block hydrocephalus. *Acta Radiol Diagn* 1971;11:232–242
57. Greitz T. Cerebral blood flow in occult hydrocephalus studied with angiography and the xenon 133 clearance method. *Acta Radiol Diagn* 1969;8:376–384
58. Greitz T, Grepe A, Kalmér M, et al. Pre- and postoperative evaluation of cerebral blood flow in low-pressure hydrocephalus. *J Neurosurg* 1969;31:644–651
59. Bergstrand G, Bergström M, Nordell B, et al. Cardiac gated MR imaging of cerebrospinal fluid flow. *J Comput Assist Tomogr* 1985;9:1003–1006
60. Greitz D. Cerebrospinal fluid circulation and associated intracranial dynamics. A radiologic investigation using MR imaging and radionuclide cisternography. *Acta Radiol* 1993;Suppl 386:1–23
61. Ruggiero G, Castellano F, Meningeomas of the posterior fossa. *Acta Radiol* 1953;Suppl 104:1–177
62. Liliequist B. Pontine angle tumour. Encephalographic appearances. *Acta Radiol* 1959;Suppl 186:1–96
63. Greitz T. Tumours of the quadrigeminal plate and adjacent structures. *Acta Radiol Diagn* 1972;12:513–538
64. Corrales M, Greitz T. Fourth ventricle, II: tumours of the cerebellum. *Acta Radiol Diagn* 1972;12:241–270
65. Möller A. Pneumography in paraventricular and intraventricular tumours of the posterior fossa. *Acta Radiol* 1974;Suppl 342:1–151
66. Azambuja N, Lindgren E. Sjögren SE. Tentorial herniations. Anatomy, pneumography, angiography. *Acta Radiol* 1956;46:214–241
67. Taveras J. ASNR: the silver anniversary: the next 25 years. *AJNR Am J Neuroradiol* 1987;8:393–395