

Are your **MRI contrast agents** cost-effective?

Learn more about generic **Gadolinium-Based Contrast Agents**.



FRESENIUS
KABI

caring for life

AJNR

The effect of contrast dose, imaging time, and lesion size in the MR detection of intracerebral metastasis.

W T Yuh, E T Tali, H D Nguyen, T M Simonson, N A Mayr and D J Fisher

This information is current as of May 27, 2024.

AJNR Am J Neuroradiol 1995, 16 (2) 373-380
<http://www.ajnr.org/content/16/2/373>



The Effect of Contrast Dose, Imaging Time, and Lesion Size in the MR Detection of Intracerebral Metastasis

William T. C. Yuh, E. Turgut Tali, Hoang D. Nguyen, Tereasa M. Simonson, Nina A. Mayr, and David J. Fisher

PURPOSE: To evaluate the effect of MR contrast dose versus delayed imaging time on the detection of metastatic brain lesions based on lesion size. **METHODS:** Contrast MR examinations with gadoteridol were obtained in 45 patients with brain metastases. The patients were divided into two groups: 16 received cumulative standard dose (0.1 mmol/kg) and 29 received cumulative triple dose (0.3 mmol/kg). Both groups were evaluated at two dose levels (lower dose and higher dose) with two separate injections. Each patient received an initial bolus injection of either 0.05 (cumulative standard dose) or 0.1 (cumulative triple dose) mmol/kg of gadoteridol to reach the lower-dose level and underwent imaging immediately and 10 and 20 minutes later. Thirty minutes after injection, an additional bolus injection of 0.05 (cumulative standard dose) or 0.2 (cumulative triple dose) mmol/kg was administered to reach the cumulative higher-dose level (cumulative standard dose, 0.1 mmol/kg; cumulative triple dose, 0.3 mmol). Images were acquired immediately. **RESULTS:** There was no difference in the detection rate for lesions larger than 10 mm among T2-weighted, lower-dose immediate and delayed, or immediate higher-dose images in both study groups. Lesions smaller than 10 mm had improved detection with delayed imaging in both study groups; however, the immediate higher-dose studies still had the highest detection rate. **CONCLUSION:** In the evaluation of small central nervous system metastases, either delayed imaging after the injection of standard contrast dose or higher contrast dose may improve their detection, and therefore affect clinical management. Higher contrast dose (cumulative triple dose) studies appear to be more effective than delayed imaging with standard dose.

Index terms: Brain neoplasms, magnetic resonance; Magnetic resonance, contrast enhancement; Efficacy studies

AJNR Am J Neuroradiol 16:373–380, February 1995

The detection of brain metastases requires reasonably high lesion contrast, which depends on the signal of a lesion in relation to the surrounding background (1, 2). Several investigators, using gadopentetate dimeglumine at a dose of 0.1 mmol/kg, reported that the signal intensity or lesion contrast of primary and secondary central nervous system lesions increased with delayed imaging time (1–6). Improvement in lesion contrast has also been demonstrated with higher doses of gadolinium

(1, 2, 4, 7–11). Lesion contrast or lesion-to-background ratio, therefore, can be improved by using either a higher dose of contrast agent or a lower dose with delayed imaging time. We hypothesized that higher lesion contrast is necessary for the detection of small metastatic lesions (<10 mm) and that immediate high-dose imaging is superior to delayed imaging at standard dose.

Materials and Methods

Contrast magnetic resonance (MR) examinations with various doses of gadoteridol and imaging times (immediate versus delayed) were obtained in 45 patients with clinically suspected brain metastases with an incremental dose technique during the phase II and III multicenter, open-label, dose-ranging, safety and efficacy trials of the nonionic contrast agent gadoteridol (Gd-HPDO3A, ProHance, Squibb Diagnostics, Princeton, NJ). All patients involved in this study gave informed consent and were

Received October 4, 1993; accepted after revision July 20, 1994.

From the Department of Radiology, the University of Iowa College of Medicine, Iowa City.

Address reprint requests to W. T. C. Yuh, MD, MSEE, Department of Radiology, The University of Iowa Hospitals and Clinics, 200 Hawkins Dr, Iowa City, IA 52242.

AJNR 16:373–380, Feb 1995 0195-6108/95/1602-0373
© American Society of Neuroradiology

TABLE 1: Cumulative standard dose group

Size of Lesion, cm	Number of Lesions Detected (n = 16 patients)				
	Immediate Initial Dose (0.05 mmol/kg)	10-Minute Delayed Initial Dose	20-Minute Delayed Initial Dose	Immediate Standard Dose (0.1 mmol/kg)	T2-Weighted Images
<0.5	34 (37.7%)	44 (48.8%)	78 (86.7%)	90 (100%)	0 (0%)
0.5-1.0	23 (63.8%)	23 (63.8%)	33 (91.6%)	36 (100%)	17 (47.2%)
1.0-1.5	8 (100%)	8 (100%)	8 (100%)	8 (100%)	8 (100%)
1.5-2.0	4 (100%)	4 (100%)	4 (100%)	4 (100%)	4 (100%)
>2.0	14 (100%)	14 (100%)	14 (100%)	14 (100%)	14 (100%)

studied in compliance with a protocol approved by our institution's Human Subjects Research Committee. Extensive laboratory tests as well as monitoring protocols were performed according to the Food and Drug Administration guidelines.

Based on the total amount of contrast agent received (initial injection plus additional injection), these 45 patients were divided into two groups: 16 patients received a cumulative standard dose (0.1 mmol/kg) and 29 patients received a cumulative triple dose (0.3 mmol/kg). Each patient received an initial injection (lower dose) of 0.05 (cumulative standard dose) or 0.1 (cumulative triple dose) mmol/kg of gadoteridol to reach the lower-dose level and was imaged immediately (immediate lower-dose study) and at 10 and 20 minutes (delayed lower-dose study) after injection. At 30 minutes, an additional bolus injection (higher dose) of either 0.05 (cumulative standard dose) or 0.2 (cumulative triple dose) mmol/kg was administered to achieve a cumulative dose (higher-dose level) of either 0.1 (cumulative standard dose) or 0.3 (cumulative triple dose) mmol/kg, respectively. Images were acquired immediately after the injection of the additional dose (immediate higher-dose study).

Imaging was performed using either a 0.5-T or 1.5-T superconductive scanner. Precontrast examinations included both axial T1-weighted (350-583/15-20/1-2 [repetition time/echo time/excitations]) and T2-weighted (2000-2500/90-100/1-2) images. Postcontrast imaging was performed at two dose levels in all patients in both groups. Postcontrast T1-weighted images (same parameters as the precontrast study) at lower-dose levels were obtained immediately (immediate lower-dose study) and at 10 and 20 minutes (delayed lower-dose study) after the initial lower-dose injection in both groups. Immediately after the second bolus injection of additional contrast (higher-dose level), T1-weighted examinations were obtained (immediate higher-dose study). Each patient's MR examinations were performed on the same MR scanner using scanning protocols identical to those of the precontrast T1-weighted images. For all imaging sequences, the field of view was 24 cm with a 192 × 256 matrix size. The section thickness was constant for each patient's images (5 mm with 50% gap for the 1.5-T system and 10-mm contiguous section thickness for the 0.5-T system).

A randomized, independent, retrospective blinded review by four radiologists was done after the precontrast

and postcontrast MR examinations of all patients. The reviewers had no knowledge of the contrast dose used or the image acquisition time (immediate or delayed) and had no access to other image sets within each study. For each cumulative standard dose or cumulative triple dose MR examination, the reviewers were asked to document the number of lesions on five separate studies: T2-weighted studies, immediate and delayed (10 minute and 20 minute) low-dose studies, and immediate higher-dose studies. Each lesion in each study was measured, numbered, and drawn on a chart that included six stylized brain sections in the transverse plane. Each lesion was measured and classified according to its largest measurement in any imaging plane as less than 5 mm, 5 to 10 mm, 11 to 15 mm, 16 to 20 mm, or larger than 20 mm.

A lesion was defined as an abnormal focal parenchymal enhancement with a signal intensity higher than the normal brain parenchyma that does not appear as a thin linear structure (blood vessel) in contiguous sections in any orthogonal plane. The criteria for deciding whether a lesion was present were as follows: each of the four radiologists independently identified the lesions as present and cases of disagreement (only two or three reviewers identified a lesion) were resolved in conference (11 lesions) by consensus. Information including the contrast dose, imaging time, and other image sets was not available to the readers in conference. If no consensus was reached, the entire image series was evaluated (2 of 11 lesions required this step). The distribution of the number of lesions in all patients studied had large variance and was nongaussian, thus Wilcoxon's signed ranked test was used in the analysis of lesion count data.

Results

There were no reported adverse effects in these 45 patients for doses up to 0.3 mmol/kg. No changes in laboratory values were related to the contrast injection. The lesion detection rates with different contrast doses, imaging times, and lesion size are summarized in Table 1 (cumulative standard dose) and Table 2 (cumulative triple dose). Because the higher-dose studies showed the highest detection rates (Figs 1-3), they were used as a reference for compar-

TABLE 2: Cumulative triple dose group

Size of Lesion, cm	Number of Lesions Detected (n = 29 patients)				
	Immediate Initial Dose (0.1 mmol/kg)	10-Minute Delayed Initial Dose	20-Minute Delayed Initial Dose	Immediate High Dose (0.3 mmol/kg)	T2-Weighted Images
<0.5	11 (34.4%)	13 (40.6%)	24 (75.0%)	32 (100%)	3 (9.4%)
0.5-1.0	36 (90.0%)	36 (90.0%)	38 (95.0%)	40 (100%)	25 (62.5%)
1.0-1.5	5 (100%)	5 (100%)	5 (100%)	5 (100%)	5 (100%)
1.5-2.0	3 (100%)	3 (100%)	3 (100%)	3 (100%)	3 (100%)
>2.0 cm	15 (100%)	15 (100%)	15 (100%)	15 (100%)	15 (100%)

ison with the lower-dose studies (Tables 1 and 2). The agreement between the reviewers was greater than 96%; the disagreements were related to lesions smaller than 5 mm.

Large Lesions

There was no difference ($P > .18$) in the detection rate of lesions larger than 10 mm among the T2-weighted, immediate or delayed lower-dose studies, and immediate higher-dose studies in either the cumulative standard dose (Table 1) or cumulative triple dose group (Table 2). Because large lesions were frequently associated with vasogenic edema and/or mass effect, T2-weighted images readily demonstrated the associated abnormalities of these lesions and therefore showed the same detection rate as the contrast studies for lesions more than 10 mm (Figs 1 and 3). Although lesion delineation was poor on the long-repetition-time images because of surrounding vasogenic edema, there were no instances in which two lesions adjacent to each other were misinterpreted as a single lesion by T2-weighted imaging in our patient population.

Small Lesions

Lesions 5 to 10 mm. The detection rate of lesions of this size was lowest on T2-weighted images. Those lesions missed by T2-weighted images and demonstrated by contrast studies were usually associated with limited mass effect and/or vasogenic edema. For lesions in the 5 to 10-mm range, progressive improvement in the detection rate was seen with increasing delay in imaging time after the initial dose in both groups (Tables 1 and 2) (Figs 1 and 3). However, delayed imaging at lower-dose levels still detected fewer lesions ($P = .0431$) than the immediate higher-dose studies in both cumulative stan-

dard dose (Table 1) and cumulative triple dose (Table 2) groups (Figs 1 and 3).

Lesions less than 5 mm. In lesions smaller than 5 mm, the detection rate improved markedly with a higher dose and, to a lesser extent, with delayed imaging (Figs 1 and 2). Thus, improved lesion contrast influenced the detection rate more effectively in smaller lesions (<5 mm) than in larger lesions (5 to 10 mm) (Tables 1 and 2). T2-weighted images again demonstrated the lowest detection rate for lesions smaller than 5 mm, in part related to the absence of vasogenic edema and mass effect (Figs 1 and 2). Compared with larger lesions, the detection rate of lesions smaller than 5 mm improved more dramatically with the initial contrast injection at lower-dose levels and further improved with delayed imaging time ($P = .0418$) in both the cumulative standard dose (Table 1) and cumulative triple dose (Table 2) groups. Immediate higher-dose studies again showed the highest detection rate compared ($P = .0431$) with that of the delayed studies at lower-dose levels in both cumulative standard dose and cumulative triple dose groups.

Discussion

Intracranial metastases occur in approximately 25% of patients with cancer and account for up to 40% of all adult brain neoplasms (12, 13). Lung carcinomas, breast carcinomas, and melanomas (in decreasing order) are the most common primary neoplasms that metastasize to the brain (13). Large brain metastases are frequently associated with marked mass effect and a large amount of vasogenic edema and, therefore, can be readily detected on MR or CT examinations with or without contrast material. However, early and small metastases, frequently located near the corticomedullary junction, may not be associated with vasogenic




Fig 1. Cumulative triple dose (0.3 mmol/kg) study of medium and small lesions: improved detection rate of small lesions with delayed imaging and higher contrast dose.


A, Axial T2-weighted image (2000/100/1) shows two lesions (left temporal lobe and left occipital lobe). No apparent signal abnormality was noted elsewhere in the brain (note particularly the frontal lobes).

B, Immediate postcontrast (contrast dose, 0.1 mmol/kg) axial T1-weighted image demonstrates one extra lesion (*curved arrow*) in the right frontal lobe in addition to the two lesions previously demonstrated on the T2-weighted image. A "possible" lesion is noted in the left frontal lobe (*large arrow*) in addition to the enhancement of a small vessel (*small arrow*). The border of the two lesions demonstrated on the T2-weighted image is much better delineated on the contrast study.

C, Ten-minute delayed postcontrast (contrast dose, 0.1 mmol/kg) axial T1-weighted image shows the same findings and detection rate as the immediate postcontrast study (B).

D, Twenty-minute delayed postcontrast (contrast dose, 0.1 mmol/kg) axial T1-weighted image shows similar findings to those in the immediate (B) and 10-minute (C) studies. In addition, there is another possible lesion (*arrow*) in the left frontal lobe.

E, Immediate higher-dose (contrast dose, 0.3 mmol/kg) axial T1-weighted image shows both left frontal lobe lesions that were considered possible lesions on the standard-dose studies (immediate, 10- or 20-minute delayed) now judged by the reviewer as definite lesions. Additionally, a new possible lesion is noted in the right frontal lobe (*arrow*).



edema or mass effect and therefore may not be readily detected (3).

Intracranial metastases are diagnosed before or at the same time as the primary tumor in approximately 20% of patients with cancer (14). Metastases have an exponential growth rate and may remain small for years (15). This suggests that many lesions may have been present in the brain at the time of primary tumor diagnosis but were too small to be detected by

conventional radiologic means. In addition, up to 50% of all patients with intracerebral metastases will have only a single lesion demonstrated by CT or MR (12, 13, 16, 17). In this group of patients, the detection of additional occult lesions that were not evident on routine radiologic examinations (including CT and standard-dose contrast-enhanced MR) is essential for optimal patient treatment. Detecting these metastases with a high-dose MR exami-





Fig 2. Cumulative triple dose (0.3 mmol/kg) study of small lesion: improved detection rate with delayed imaging and higher contrast dose.

A, Axial T2-weighted image (2000/100/1) demonstrates no apparent abnormality in the cerebellum.

B, Immediate postcontrast (contrast dose, 0.1 mmol/kg) axial T1-weighted image shows two possible lesions (*arrows*) in the left cerebellar hemisphere.

C, Ten-minute delayed postcontrast (contrast dose, 0.1 mmol/kg) axial T1-weighted image shows similar findings to those in B (immediate study).

D, Twenty-minute delayed postcontrast (contrast dose, 0.1 mmol/kg) axial T1-weighted image shows one lesion (*arrow*) that was reclassified by the reviewer from "possible" in the previous studies to "definite" here, whereas the other lesion remained "possible."

E, Immediate higher-dose (contrast dose, 0.3 mmol/kg) axial T1-weighted image shows two definite lesions.

nation becomes important particularly after the initial diagnosis of those primary tumors with a propensity for early metastases to the brain.

Early diagnosis of brain involvement and determination of the number of metastases are important not only for cost effectiveness but also for the quality of life (18). Treatment is the factor that determines survival in brain metastases (18). Untreated patients with brain metastases have a median survival of fewer than 3 months. Patients with multiple central nervous system metastases are usually treated with radiation or chemotherapy without surgical resection of the primary tumor or brain metastases.

Those with solitary lesions, in the absence of significant systemic disease, can be treated with surgical resection and radiation treatment (13, 19). It has been reported that patients with solitary metastases who undergo resection have an increased survival time and an improved quality of life compared with patients with solitary metastases who undergo chemotherapy alone (18). Recently, radiosurgery has been reported to be useful in the treatment of patients with central nervous system metastases (20–22). Again, the application of such techniques depends on the number of brain metastases detected by radiologic means. Thus, it is critical




Fig 3. Cumulative standard dose (0.1 mmol/kg) study of large and small lesions: improved detection rate of small lesion with delayed imaging and higher contrast dose.

A, Axial T2-weighted image (2000/100/1) shows a large lesion in the left occipital lobe with marked mass effect and vasogenic edema. No apparent abnormality is seen in the rest of the brain parenchyma (note particularly the right temporal lobe).

B, Immediate postcontrast (contrast dose, 0.05 mmol/kg) axial T1-weighted image shows intense enhancement and better delineation of the large lesion shown on the T2-weighted image. Note the relative absence of enhancement in the central portion of the lesion presumably representing necrosis. Because this lesion is large and associated with marked vasogenic edema, T2 weighting can readily detect such an abnormality despite poor lesion delineation.

C, Ten-minute delayed postcontrast (contrast dose, 0.05 mmol/kg) axial T1-weighted image exhibits the same detection rate of a single lesion as in B with progressive enhancement of the central portion of the lesion.

D, Twenty-minute delayed postcontrast (contrast dose, 0.05 mmol/kg) axial T1-weighted image demonstrates the same detection rates as in B and C, but the lesion is now enhanced homogeneously. In addition, possible lesions (*arrows*) are identified by the reviewers in the right temporal lobe.

E, Immediate higher-dose (contrast dose, 0.1 mmol/kg) axial T1-weighted image again shows the large lesion in the left occipital lobe but now with further enhancement. The previously noted central necrosis is again demonstrated as the result of the marked enhancement of the viable tumor tissue achieved with the high-dose study. Only one of the two possible lesions noted in the 20-minute delayed image (D) is now judged by the reviewer to be a definite lesion.

to make this distinction (zero, solitary, or multiple brain metastases) in patients with a clinical suspicion of intracranial metastatic disease, especially those with a newly diagnosed primary tumor (ie, lung, breast, and others).

An understanding of the principles involved in lesion detection may help explain our results.

Lesion detection is dependent on both lesion size and lesion contrast (1, 8, 9). Enhancing lesions with high lesion/background ratios have a better chance of being detected as demonstrated by phantom studies (1, 8, 9). Large and/or high-contrast lesions have an increased likelihood of being detected over small and/

or low-contrast lesions (low lesion/background ratio). However, the minimal requirement for lesion detectability may not depend solely on either size or high lesion/background ratio alone, but on the combined effects of these two as demonstrated by the phantom studies (1).

In the past, lesion size has not been considered an important parameter in the lesion detection rate of brain metastases with various contrast agents, different doses, and delayed imaging times (3–6, 19, 23–31). Whether delayed imaging improves the detection rate has been controversial (4, 6, 12, 33). There are reports that delayed imaging (20 to 30 minutes) at a dose of 0.1 mmol/kg offers no advantage over immediate postcontrast studies (5, 11, 32). Many of the lesions in these reports were fairly large. Based on the findings of the phantom studies, it is expected that delayed imaging would not have helped in the detection of those large lesions. Conversely, Healy et al (3) showed that delayed imaging did improve lesion detection. Most of the lesions in their study were 5 mm or smaller. Our results agree with those of previous reports, if lesion size is considered one of the parameters influencing lesion detection.

Our results also suggest that a lesion size of 10 mm is the critical value in lesion detection. Lesions larger than 10 mm were readily detected by almost all methods including noncontrast T2-weighted imaging. We think that this was in part because vasogenic edema was associated with the larger metastases. Healy et al (3) reported that metastatic lesions measuring smaller than 10 mm typically are not accompanied by abnormal signal on T2-weighted images (ie, vasogenic edema).

For lesions smaller than 10 mm, any method to improve lesion contrast becomes essential for detection. Methods such as delayed imaging and/or high-dose examinations, used to improve lesion contrast, will help in the detection of smaller lesions (less than 10 mm). Our results from both cumulative triple dose and cumulative standard dose study groups clearly show that delayed imaging improves the detection of lesions smaller than 10 mm.

It has been recommended that image acquisition be delayed from 5 to 35 minutes after the administration of contrast material at a dose of 0.1 mmol/kg to ensure optimal detection (3, 5, 11, 32). Using region-of-interest techniques, Schörner et al (6) showed that the optimal sig-

nal intensity occurred between 8.5 and 38.5 minutes after the injection of the contrast agent (0.1 mmol/kg). In our study, 20 minutes was the optimal delayed time as compared with the 10-minute or immediate images in either the cumulative triple dose or cumulative standard dose group in the detection of small lesions (less than 10 mm). We did not perform delayed images of more than 20 minutes and therefore cannot judge the effect of longer delayed imaging times.

Our results demonstrated improved detection rates with delayed imaging at lower-dose levels (after initial injection) in both cumulative standard dose and cumulative triple dose groups, but higher-dose studies still had better detection rates for small lesions. This is likely related to the fact that further improvement in lesion contrast was achieved with a higher contrast dose than with the lower-dose delayed imaging (2). Furthermore, lesion detection rate is predictably higher in triple-dose studies than in delayed standard-dose studies, which may affect patient treatment.

In the cumulative triple dose group of 29 patients, comparing lesion detection between the immediate and delayed standard dose imaging with the triple dose, 10 patients had potential altered treatment based on the information provided by the high-dose studies. Eight of these patients had a solitary metastasis detected in the immediate and delayed standard-dose studies, whereas the triple-dose studies revealed multiple lesions in 7 of the 8 patients, precluding possible surgical resection and high-dose radiation boost in addition to the whole-brain radiation. Two patients had no lesion detected on the standard-dose study but showed a solitary parenchymal lesion after receiving the cumulative triple dose.

In summary, our study showed that the detection rate of small lesions, measuring less than 10 mm, improved with both higher contrast doses and delayed imaging times. Although imaging improved the detection rate, higher-dose immediate studies still remained superior to delayed studies in detecting small lesions. However, for lesions larger than 10 mm, there is no apparent advantage in using delayed imaging or higher-contrast doses, because usually these lesions have already been detected on the noncontrast or lower-dose studies. Thus, our results suggest that higher doses appear to be more efficacious than delayed images in the

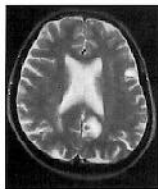detection of small and/or early metastatic lesions in patients with negative findings or single lesions demonstrated on noncontrast or lower-dose studies. Delayed imaging and higher doses are not necessary if multiple metastases have been demonstrated on the noncontrast and/or lower-dose studies. The efficacy of higher-dose delayed studies remains to be determined.

Acknowledgments

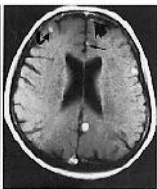We gratefully acknowledge the assistance of Drs Donald Mueller, Yutaka Sato, and Gerald Farrar.

References

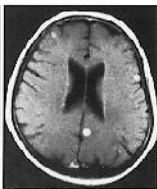1. Yuh WTC, Fisher DJ, Engelken JD, et al. MR evaluation of CNS tumors: dose comparison study with gadopentetate dimeglumine and gadoteridol. *Radiology* 1991;180:485-491
2. Yuh WTC, Engelken JD, Muhonen MG, Fisher DJ, Ehrhardt JC. Experience with high-dose gadolinium MR imaging in the evaluation of brain metastases. *AJNR Am J Neuroradiol* 1992;13:335-345
3. Healy ME, Hesselink JR, Press GA, Middleton MS. Increased detection of intracranial metastases with intravenous Gd-DTPA. *Radiology* 1987;165:619-624
4. Niendorf HP, Laniado M, Semmler W, Schörner W, Felix R. Dose administration of gadolinium-DTPA in MR imaging of intracranial tumors. *AJNR Am J Neuroradiol* 1987;8:803-815
5. Russell EJ, Geremia GK, Johnson CE, et al. Multiple cerebral metastases: detectability with Gd-DTPA-enhanced MR imaging. *Radiology* 1987;165:609-617
6. Schörner W, Laniado M, Niendorf HP, Schubert C, Felix R. Time-dependent changes in image contrast in brain tumors after gadolinium-DTPA. *AJNR Am J Neuroradiol* 1986;7:1013-1020
7. Runge VM, Kirsch JE, Burke VJ, et al. High-dose gadoteridol in MR imaging of intracranial neoplasms. *J Magn Reson Imaging* 1992;2:9-18
8. Yuh WTC, Fisher DJ, Mayr-Yuh NA, et al. Review of the use of high-dose gadoteridol in the magnetic resonance evaluation of central nervous system tumors. *Invest Radiol* 1992;27(Suppl 1):S39-S44
9. Yuh WTC, Fisher DJ, Nguyen HD, Tali ET, Mayr NA. The application of contrast agents in the evaluation of neoplasms of the central nervous system. *Top Magn Reson Imaging* 1992;4:1-6
10. Haustein J, Laniado M, Niendorf HP, et al. Pathology of tumors of the nervous system. *Radiology* 1993;186:855-860
11. Haustein J, Laniado M, Niendorf H-P, et al. Administration of gadopentetate dimeglumine in MR imaging of intracranial tumors: dosage and field strength. *AJNR Am J Neuroradiol* 1992;13:1199-1206
12. Posner JB, Chernik NL. Intracranial metastases from systemic cancer. *Adv Neurol* 1978;19:579-592
13. Russell DJ, Rubenstein LJ. *Pathology of Tumours of the Nervous System*. 5th ed. Baltimore: Williams & Wilkins, 1989:825-841
14. Rubin R, Green J. *Solitary Metastases*. Springfield, IL: Charles C Thomas, 1968
15. Tannock IF. Principles of cell proliferation: cell kinetics. In: DeVita VT Jr, Hellman S, Rosenberg SA, eds. *Cancer: Principles and Practice of Oncology*, 3rd ed. Philadelphia: JB Lippincott, 1989: 3-13
16. Delattre JY, Krol G, Thaler HT, Posner JB. Distribution of brain metastases. *Arch Neurol* 1988;45:741-744
17. Weiss L, Gilbert HA, Posner JB. *Brain Metastases*. Boston: GK Hall & Co, 1980:2-29
18. Martini N. Operable lung cancer. *Cancer J Clin* 1993;43:201-214
19. Davis PC, Hudgin PA, Peterman SB, Hoffman JC Jr. Diagnosis of cerebral metastases: double-dose delayed CT vs contrast-enhanced MR imaging. *AJNR Am J Neuroradiol* 1991;12:293-300
20. Kihlstrom L, Karlsson B, Lindquist C, Noren G, Rahn T. Gamma knife surgery for cerebral metastasis. *Acta Neurochir Suppl (Wien)* 1991;52:87-89
21. Black PM. Solitary brain metastases. Radiation, resection, or radiosurgery? *Chest* 1993;103:367S-369S
22. Mehta MP, Rozental JM, Levin AB, et al. Defining the role of radiosurgery in the management of brain metastases. *Int J Radiat Oncol* 1992;24:612-625
23. Carr DH, Brown J, Bydder GM, et al. Intravenous chelated gadolinium as a contrast agent in NMR imaging of cerebral tumours. *Lancet* 1984;1:484-486
24. Claussen C, Laniado M, Kazner E, Schörner W, Felix R. Application of contrast agents in CT and MRI (NMR): their potential in imaging of brain tumors. *Neuroradiology* 1985;27:164-171
25. Brant-Zawadzki M, Berry I, Osaki L, Brasch R, Murovic J, Norman D. Gd-DTPA in clinical MR of the brain, I: intraaxial lesions. *AJNR Am J Neuroradiol* 1986;7:781-788
26. Felix R, Schörner W, Laniado M, et al. Brain tumors: MR imaging with gadolinium-DTPA. *Radiology* 1985;156:681-688
27. Elster AD, Rieser GD. Gd-DTPA-enhanced cranial MR imaging in children: initial clinical experience and recommendations for its use. *AJNR Am J Neuroradiol* 1989;10:1027-1030
28. Hesselink JR, Healy ME, Press GA, Brahme FJ. Benefits of Gd-DTPA for MR imaging of intracranial abnormalities. *J Comput Assist Tomogr* 1988;12:266-274
29. Laniado M, Weinmann HJ, Schörner W, Felix R, Speck U. First use of GdDTPA/dimeglumine in man. *Physiol Chem Phys Med NMR* 1984;16:157-165
30. Wessbecher FW, Maravilla KR, Dalley RW. Optimizing brain MR imaging protocols with gadopentetate dimeglumine: enhancement of intracranial lesions on spin-density- and T2-weighted images. *AJNR Am J Neuroradiol* 1991;12:675-679
31. Sze G. New applications of MR contrast agents in neuroradiology. *Neuroradiology* 1990;32:421-438
32. Sze G, Milano E, Johnson C, Heier L. Detection of brain metastases: comparison of contrast-enhanced MR with unenhanced MR and enhanced CT. *AJNR Am J Neuroradiol* 1990;11:785-791



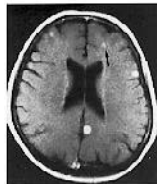A



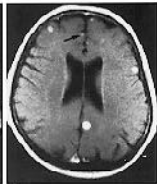B



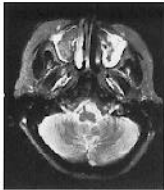
C



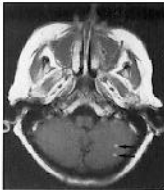
D



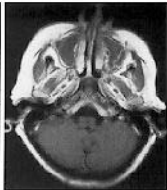
E



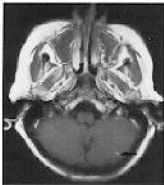A



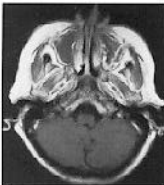
B



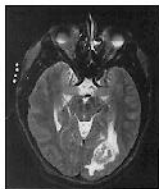C



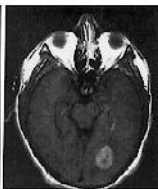D



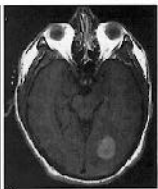E



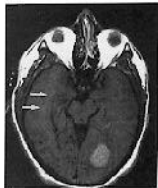A



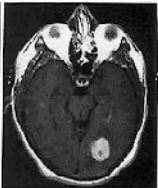B



C



D



E