

Rerupture of Cerebral Aneurysms during Angiography

Hidekazu Saitoh, Katsumi Hayakawa, Kazumasa Nishimura, Yoshishige Okuno, Tetsuaki Teraura, Katsuhiro Yumitori, and Atsushi Okumura

PURPOSE: To assess the incidence of angiography-related rerupture of intracranial aneurysms and to analyze other risk factors of this complication. **METHODS:** Clinical data from 144 patients with acute subarachnoid hemorrhage from ruptured intracranial aneurysm were reviewed retrospectively. In all patients, angiography was done by the transaortic approach. **RESULTS:** The incidence of rerupture caused by angiography was 2 (1.4%) of 144 and that of spontaneous rerupture was 14 (9.7%) of 144. Angiography within 6 hours after the initial subarachnoid hemorrhage attack was associated with a significantly higher incidence of rerupture (4.8%) than that after a longer interval (0%). In cases of spontaneous rerupture, patients with worse levels of consciousness showed a higher incidence of rerupture, and this tendency also was evident in cases of induced rerupture. There was no significant correlation between the rerupture rate and the injection volume of contrast medium, aneurysm location, or patient age or sex. **CONCLUSION:** Although angiography within 6 hours after initial intracranial aneurysm rupture was associated with a higher rate of rerupture, the incidence of rerupture in this study (4.8%) was much lower than those reported previously (20% to 38.5%). The present findings suggest that emergency angiography within 6 hours after aneurysm rupture, which enables neurosurgeons to carry out early surgery, should not be discouraged.

Index terms: Angiography, complications; Aneurysm, intracranial

AJNR Am J Neuroradiol 16:539-542, March 1995

Although cerebral angiography is necessary for early diagnosis of ruptured intracranial aneurysms, rerupture associated with the angiographic procedure has been reported as a serious complication. Recently, Japanese neurosurgeons have reported high incidences (20% and 38.5%) of aneurysm rerupture during emergency cerebral angiography within 6 hours after ictus (1, 2). Therefore, there may be a tendency to hesitate or even avoid performing emergency angiography in patients with acute subarachnoid hemorrhage within 6 hours after ictus. We conducted a retrospective study to assess the incidence of rerupture of intracranial aneurysms associated with angiography and to an-

alyze other risk factors of this potentially fatal complication.

Clinical Materials and Methods

Between 1976 and 1992, 167 patients with acute subarachnoid hemorrhage were confirmed angiographically to have intracranial aneurysm, and records for 144 of them were available for this study. The mean age of the 144 patients was 56 years, and the female:male ratio was 81:63. Our protocol for angiography included the Seldinger catheterization technique and a four-vessel study via the transaortic approach; thus there was no case of direct puncture of the carotid artery or retrograde transbrachial artery injection. We mainly used 6.5F to 7.5F Headhunter or Simmons catheters (Cook, Bloomington, Ind) between 1976 and 1984, and 5F to 5.5F Headhunter or Simmons catheters (Cook, Bloomington, Ind, and Toray, Japan) after 1984. The contrast media we used included meglumine diatrizoate (Angiografin, 305.8 mg iodine/mL [Schering, Berlin, Germany]) between 1976 and 1984; metrizamide (Amipaque, 300 mg/mL [Schering, Berlin, Germany]) between 1984 and 1986; iopamidol (Iopamiron, 300 mg/mL [Schering, Berlin, Germany]) between 1986 and 1988, and a combination of ioxoglate meglumine and ioxoglate sodium (Hexabrix, 320 mg/mL

Received March 24, 1994; accepted after revision September 27.

From the Departments of Radiology (H.S., K.H., K.N., Y.O.) and Neurosurgery (T.T., K.Y., A.O.), Kyoto City Hospital, Kyoto, Japan.


Address reprint requests to Dr Hidekazu Saitoh, Department of Radiology, Kyoto City Hospital, 1-2 Higashi-takado-cho, Mibu, Nakagyo-ku, Kyoto 604, Japan.

AJNR 16:539-542, Mar 1995 0195-6108/95/1603-0539
© American Society of Neuroradiology

Fig 1. Case 1.

A, Initial common carotid angiogram (lateral view) shows an internal carotid posterior communicating aneurysm without definite extravasation.

B, At the time of second injection, extravasation is evident.



[Gerbet, France]) after 1989. We also used an automatic power injector (a Contrac 4E [Siemens, Germany] between 1976 and 1990, and a Mark V [Medrad, Pittsburgh, Pa] after 1990) in all cases. The injection volume and rate were 12 to 15 mL (7 to 8 mL/s) when the catheter tip was in the common carotid artery, 9 to 12 mL (7 to 8 mL/s) when in the internal carotid artery, and 5 to 9 mL (5 to 7 mL/s) when in the vertebral artery. Definition of rerupture associated with angiography was (a) extravasation of contrast medium during angiography, (b) an increase of hemorrhage evident on computed tomography (CT) after angiography, or (c) fresh bleeding from the ventricular drainage tube or spinal drainage tube. In cases with criteria b and c, there were associated clinical signs of acute neurologic deterioration during and within 24 hours after angiography. In contrast, definition of spontaneous rerupture was criteria b or c above, with the attack occurring before or 24 hours after angiography. We compared the induced rerupture rate with the spontaneous rerupture rate and analyzed statistically (by χ^2 test) correlations between rerupture and risk factors such as timing of angiography, consciousness level (3-3-9 method), contrast material injection rate, and blood pressure.

Results

The incidence of rerupture caused by angiography was 2 (1.4%) of 144, and that of spontaneous rerupture 14 (9.7%) of 144. The two cases of induced rerupture were as follows.

Case 1

A 66-year-old woman underwent emergency angiography 2 hours after onset of subarachnoid hemorrhage. The preangiographic consciousness level was 100 (3-3-9 method) and blood pressure was 150/92 mmHg. A left internal carotid posterior communicating aneurysm (without extravasation) was revealed by injection of meglumine diatrizoate (12 mL, 8 mL/s) into the left common carotid artery (Fig 1A). At the time of second injection to obtain another plane or view, extravasation occurred (Fig 1B).

The patient soon underwent surgery for aneurysm clipping, but her consciousness level did not improve and she died 30 days later.

Case 2

A 50-year-old man underwent cerebral angiography 5 hours after onset of subarachnoid hemorrhage. The preangiographic consciousness level was 10, and the blood pressure 110/76 mmHg. From a catheter positioned in the left internal carotid artery, contrast material (ioxaglate) was injected (10 mL, 6 mL/s) three times. An anterior communicating artery aneurysm was observed without extravasation. After the angiography, during compression at the puncture site, ictus occurred suddenly, followed by rapid deterioration of the patient's consciousness level. CT revealed an increase of subarachnoid hemorrhage and the presence of intraventricular blood. Emergency ventricular drainage improved his condition, and a clipping operation performed 9 days later was successful. (In both cases, the patient had no spontaneous rerupture other than the induced rerupture.)

In 42 cases, angiography was done within 6 hours after ictus, and in 2 cases (4.8%) (described above), rerupture caused by angiography occurred (Table 1A). In other cases in which the interval between ictus and angiogra-

TABLE 1A: Induced rerupture and angiographic timing

Time after Ictus of Angiography	Induced Rerupture Rate
0-6 h	2/42(4.8%)
7-24 h	0/53 (0%)
2-3 d	0/26 (0%)
4-14 d	0/15 (0%)
15 d	0/8 (0%)
Total	2/144

TABLE 1B: Period of spontaneous rerupture

Time after First Ictus	No. of Reruptures
0-6 h	1
7-24 h	1
2-3 d	1
4-14 d	9
15 d	2
Total	14

phy was more than 7 hours, no induced rerupture occurred. Therefore, angiography within 6 hours after the initial subarachnoid hemorrhage was associated with a significantly higher incidence of rerupture ($P < .05$).

The number of spontaneous rerupture are showed in Table 1B. Each period represents when the rerupture occurred, but not angiographic timing. It is difficult to show the incidence of spontaneous rerupture because the denominators (ie, the number of patients who had not been treated surgically) decreased continuously. The mortality rate in patients with rerupture (both induced and spontaneous) was much higher (80%) than in those without (29%).

There were no induced reruptures and 4 spontaneous reruptures among 89 patients whose preangiographic consciousness levels ranged from 0 to 3, whereas 2 induced reruptures and 9 spontaneous reruptures occurred among 45 patients with consciousness levels of more than 10 (Table 2). With regard to spontaneous rerupture, the difference between the 2 groups was statistically significant ($P < .025$).

Injection volume and rate are shown in Table 3. All the arteries were feeders of the aneurysms. In this table, N represents the total number of injections; the average number of injections was 2.0. The injection volumes and rates in cases of induced rerupture were almost equal to the average values.

There was no significant correlation between rerupture and patient age, sex, or aneurysm location.

TABLE 2: Consciousness level of the patients

Consciousness Level (3-3-9 Method)	No. of Patients	Induced Rerupture	Spontaneous Rerupture
0; clear	51	0	3
I (1-3); confusion	38	0	1
II (10-30); drowsy	21	1	3
III (100); semicomatose	8	1	2
III (200); coma	14	0	4
III (300); deep coma	2	0	0
Unknown	10	0	1

TABLE 3: Contrast medium injection

Site	N	Volume, mL (mean)	Rate, mL/s (mean)	Induced Rerupture (volume; rate)
CCA	88	8-17 (13.0)	5-8 (7.5)	1 (12 mL; 8 mL/s)
ICA	175	6-13 (10.1)	4.5-8 (6.8)	1 (10 mL; 6 mL/s)
VA	17	10-15 (12.5)	5-7 (6.0)	
Subclavian artery	3	7-10 (9.1)	5 (5)	

Note.—CCA indicates common carotid artery; ICA, internal carotid artery; VA, vertebral artery; and N, total number of injections.

Discussion

Because rerupture of intracranial aneurysm is a serious complication with a high mortality rate, it is important to know whether angiography has a significant association with rerupture.

In some reports (3-5), the total rerupture rate (both induced and spontaneous) was about 30%, with peak times of occurrence within 24 hours (especially within 6 hours) and 1 week after the first ictus. However, caution should be exercised when assessing the rerupture rate because it is influenced by the surgery rate and timing in each hospital, which tend to vary. Generally, the rerupture rate in cases allowed to take a natural course is much higher than in those cases treated surgically (5). Locksley's study of a large series in 1966 revealed 189 reruptures (31%) among 602 nonsurgical cases and 101 reruptures (16%) among 641 surgical cases. The rerupture rate in this study, which included both surgical and nonsurgical cases, was 15 (10%) of 144. The reason for this lower incidence is thought to be the progress made in preoperative management since 1966 and the relatively earlier timing of surgery.

As to the relation between rerupture rate and angiography, Yasui et al (3) reported a figure of 3.0% (11 of 368), Iwa et al (2) 4.5% (7 of 154), Itoh et al (1) 4.4% (13 of 295), and Perret et al (6) 2.0% (67 of 3376, including 439 patients with arteriovenous malformations). These data show a slightly higher rate than 1.4% (2 of 144), possibly because angiographic methods in other hospitals included the frequent use of retrograde transbrachial artery injection, which uses a large volume of contrast material, and direct carotid artery puncture, which might be accompanied by pain and subsequent blood pressure elevation.

The relation between angiography timing and rerupture is a very important but controversial subject. The rate of rerupture associated with angiography performed within 6 hours after the first ictus was 4.8% (2/42), which was significantly higher than that after 6 hours. Itoh et al (1) and Iwa et al (2) also reported high incidences of rerupture induced by emergency angiography (20% [9 of 45] and 38.5% [5 of 13], respectively). However, as mentioned previously, the angiographic method used and other patient treatment factors may reduce the incidence to a level as low as that in our study. Therefore we do not favor the opinion that emergency angiography should be avoided. Locksley (5) reported that patients with ruptured intracranial aneurysm allowed to take a natural course have a risk of rerupture ranging from 1% to 4% each day regardless of angiographic timing. Therefore postponement of angiography and surgery may increase the spontaneous rerupture rate.

From a therapeutic viewpoint, a multiinstitutional study by Kassell (7) indicated that early surgery reduced the risk of rebleeding but did not appear to have a major influence on mortality or morbidity resulting from vasospasm. Therefore, the overall treatment results derived from a policy of early surgery are better than those derived from delayed surgery.

Conclusions

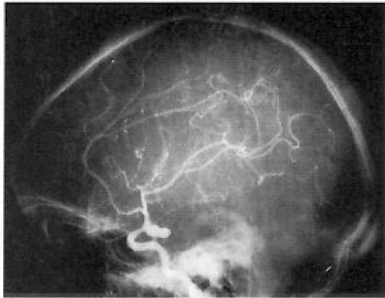
The incidence of rerupture of cerebral aneurysm related to angiography was 1.4% (2 of

144), but spontaneous rerupture was observed in 9.7% (14 of 144) of patients with acute subarachnoid hemorrhage. The significant risk factor of angiography induced rerupture was the timing of angiography *within 6 hours* after the initial subarachnoid hemorrhage attack. The primary risk factor for spontaneous rerupture was consciousness level of patients (20%, 9 of 45 drowsy, deeply comatose patients).

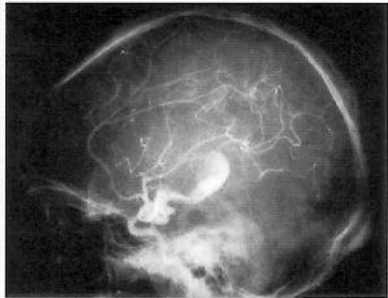
This study showed that the incidence of rerupture induced by angiography within 6 hours after onset of aneurysm rupture was not so high as reported before. Emergency angiography, enabling neurosurgeons to carry out early surgery, should not be discouraged.

References

1. Itoh S, Kwak R, Emori T, et al. Risk factors of cerebral aneurysm rerupture during angiography. *No Shinkei Geka* 1986;13:399-407
2. Iwa H, Kyoi K, Tsunoda S, Yokoyama K, Imanishi M, Utsumi S. Clinical characteristics of contrast medium extravasation from intracranial aneurysm during cerebral angiography. *No Shinkei Geka* 1986;14:263-270
3. Yasui N, Suzuki A, Ohta H, Kamiyama H, Kawamura S. Rebleeding attack of the cerebral aneurysm. *No Shinkei Geka* 1985;13:61-68
4. Kojo N, Tokutomi T, Nakayama K, Takagi S, Shigemori M. Clinical analysis of factors affecting rebleeding from ruptured cerebral aneurysms. *Jpn J Stroke* 1990;12:62-67
5. Locksley HB. Report on the cooperative study of intracranial aneurysms and subarachnoid hemorrhage, II. *J Neurosurg* 1966;25:321-368
6. Perret G, Nishioka H. Report on the cooperative study of intracranial aneurysms and subarachnoid hemorrhage. *J Neurosurg* 1966;25:98-114
7. Kassell NF, Torner JC, Jane JA, et al. The international cooperative study on the timing of aneurysm surgery, II. *J Neurosurg* 1990;73:37-47



A



B