

Are your **MRI contrast agents** cost-effective?

Learn more about generic **Gadolinium-Based Contrast Agents**.



FRESENIUS  
KABI

caring for life

**AJNR**

**MR and cognitive testing of patients undergoing osmotic blood-brain barrier disruption with intraarterial chemotherapy.**

S Roman-Goldstein, P Mitchell, J R Crossen, P C Williams, A Tindall and E A Neuwelt

This information is current as of April 18, 2024.

*AJNR Am J Neuroradiol* 1995, 16 (3) 543-553  
<http://www.ajnr.org/content/16/3/543>

# MR and Cognitive Testing of Patients Undergoing Osmotic Blood-Brain Barrier Disruption with Intraarterial Chemotherapy

Simon Roman-Goldstein, Peter Mitchell, John R. Crossen, Paul C. Williams, Angelique Tindall, and Edward A. Neuwelt

**PURPOSE:** To determine whether osmotic blood-brain barrier disruption is associated with MR abnormalities or cognitive deterioration and, if so, whether the MR findings correlate with cognitive test results. **METHODS:** Fifteen brain tumor patients who had a complete tumor response (nine central nervous system lymphoma, three germ cell and two astrocytoma, and one primitive neuroectodermal tumor) treated with blood-brain barrier disruption procedures (318 total procedures) with intraarterial chemotherapy were included. MR images were evaluated for the development of white matter hyperintensity, vascular lesions, or atrophy. Cognitive testing was performed to assess deterioration caused by this therapy. **RESULTS:** In two patients white matter hyperintensity developed, in two small vascular lesions developed, and in one mild atrophy developed. One infarct was asymptomatic and the second one resulted in mild dysesthesia in one upper extremity. No patient showed diminished cognitive function on the posttherapy evaluation. **CONCLUSION:** In patients undergoing blood-brain barrier disruption with intraarterial chemotherapy, new abnormalities on MR imaging may develop. These patients maintain the same level of cognitive and neurologic function and MR findings do not correlate with the results of cognitive testing.

**Index terms:** Blood-brain barrier; Chemotherapy; Iatrogenic disease or disorder; Brain, magnetic resonance

*AJNR Am J Neuroradiol* 16:543-553, March 1995

Osmotic blood-brain barrier disruption, when combined with intraarterial chemotherapy, which increases drug delivery, has been shown to be an effective treatment for brain tumors (1-3). Prior studies with serial cognitive testing have shown blood-brain barrier disruption with

intraarterial chemotherapy was associated with preservation of cognitive function (3, 4). Therapeutic modalities other than osmotic blood-brain barrier disruption with intraarterial chemotherapy, in particular radiation therapy, for the treatment of malignant brain tumors have shown toxic effects on the central nervous system from both a structural and neurobehavioral aspect (5, 6). This investigation was undertaken to detect the possible presence of new structural abnormalities diagnosed by magnetic resonance (MR) imaging or functional abnormalities detected by cognitive testing. Neuropsychological assessment has been shown to be a useful addition to clinical impressions and mental status exams for detecting cognitive impairments (7-12). Thus, the approach of the present study involved a serial assessment design with patients as their own controls for systematic evaluation of the potential neurotoxicity of osmotic blood-brain barrier disruption with intraarterial chemotherapy. In addition, the correlation between structural lesions documented by MR im-

---

Received April 5, 1994; accepted after revision August 29.

This work was supported by the Veterans Administration Merit Review Grant, the National Institutes of Health, Grant #31770, and the Cooper Fellowship Fund.

This paper was presented at the 31st Annual Meeting of the American Society of Neuroradiology, May 16-20, 1993, Vancouver, British Columbia.

From the Departments of Diagnostic Radiology (S.R.-G.), Neurology (S.R.-G., P.C.W., E.A.N.), and Medical Psychology (J.R.C.), Oregon Health Sciences University and Portland VA Medical Center; the Department of Radiology, Royal Melbourne Hospital, Parkville, Melbourne, Victoria, Australia (P.M.); and the Neurosciences Department, St Peter's Community Hospital, Helena, Mont (A.T.).

Address reprint requests to Edward A. Neuwelt, MD, Neurology L603, Oregon Health Sciences University, 3181 SW Sam Jackson Park Rd, Portland, OR 97201-3098.

*AJNR* 16:543-553, Mar 1995 0195-6108/95/1603-0543  
© American Society of Neuroradiology

aging and neurobehavioral sequelae diagnosed by comprehensive neuropsychologic testing was evaluated.

## Patients and Methods

### *Patient Demographics and Procedures*

Fifteen consecutive patients (nine male, six female) ranging from 6 to 66 years of age with pathologically confirmed brain neoplasms were included in this study. Before and after 1 year of treatment with blood-brain barrier disruption with intraarterial chemotherapy, all patients underwent MR imaging and neuropsychologic testing between March 1987 and November 1992. The study included a total of 318 disruption procedures with an average of 21 procedures per patient (range, 15 to 26).

### *Inclusion Criteria*

Patients were included in this series if they completed 1 year of disruption therapy and had a complete tumor response defined as no residual enhancement (13). No patient in this series had prior cranial radiation, and only the three germinoma patients had prior chemotherapy. Each of these three patients received intravenous cisplatin (total dose, 300 mg/m<sup>2</sup>) and intravenous etoposide (total dose, 1500 mg/m<sup>2</sup>) before undergoing blood-brain barrier disruption and intraarterial chemotherapy. These criteria were established so that any MR or neuropsychologic examination changes would be attributable to disruption therapy and not to the effects of residual tumor or other therapies. A minimum 1-year period was chosen to allow for the possible development of delayed structural or cognitive abnormalities caused by disruption therapy.

### *Disruption Procedure*

Osmotic blood-brain barrier disruption with intraarterial chemotherapy administration was performed under general anesthesia via a transfemoral catheter placed into either the distal cervical internal carotid artery or in a vertebral artery at the level of the sixth cervical vertebral body. The blood-brain barrier was then disrupted by the intraarterial injection of 25% mannitol. The flow rate of mannitol varied from 5 to 12 mL per second, and the duration of the injection was 30 seconds. The flow rate in any procedure was selected to deliver enough mannitol to disrupt the blood-brain barrier in a specific vascular territory (14). Two different chemotherapy regimens were used. In one regimen, intravenous cyclophosphamide (15 mg/kg) was administered immediately before the blood-brain barrier disruption injection and intraarterial methotrexate (2.5 g) immediately after the blood-brain barrier disruption (followed by oral procarbazine [100 mg/d] for 14 days). The second regimen consists of intravenous etoposide (200 mg/m<sup>2</sup>) administered before blood-brain barrier disruption with intraarterial carbopla-

tin (200 mg/m<sup>2</sup>) administered immediately after blood-brain barrier disruption. Patients were usually treated for 1 year in this protocol. The usual treatment course consisted of two disruption procedures in different vascular territories on successive days each month for a total of 24 procedures in 1 year of therapy. In diffuse tumors, such as primary central nervous system lymphoma or disseminated germinoma, the bilateral internal carotid artery and vertebral artery territories were treated, whereas in malignant astrocytomas only those circulations most likely to supply the tumor were treated (1, 2). Patient characteristics and procedure histories are summarized in Table 1.

### *Imaging Protocols*

MR images were usually made on a 1.5-T Signa scanner (General Electric, Milwaukee, Wis), and were obtained before the first blood-brain barrier disruption procedure. Additional films were obtained after completion of 1 year of disruption therapy and then at yearly intervals. The MR protocol included sagittal and transaxial T1-weighted images at 600/20/4 (repetition time/echo time/excitations) with 5-mm section thickness, transaxial proton-density images with 5-mm section thicknesses (2800/30/1), and T2-weighted images (2800/80/1). Gadopentetate dimeglumine (Magnevist, Berlex Imaging, Wayne, NJ) was then injected intravenously and additional transaxial and coronal T1-weighted images obtained with the same pulse sequences and section thickness as the unenhanced MR images. Patients underwent monthly contrast-enhanced computed tomography (CT) scans with scans of 10-mm section thickness performed 30 minutes after an intravenous injection of 150 mL of iopamidol injection 61% (Isovue 300, Squibb Diagnostics, Princeton, NJ) during the year of disruption therapy to assess tumor response.

### *Image Analysis*

The images were analyzed for the development of white matter disease, atrophy, and vascular lesions. White matter disease was defined as new areas of hyperintensity in the periventricular white matter. Atrophy was defined as enlargement of the ventricles or sulci when compared with pretherapy scan and was subjectively graded as none, mild, moderate, or marked. Vascular lesions were defined as peripheral wedge-shaped areas of cortical and subcortical signal abnormality or new areas of hyperintensity in the brain stem or basal ganglia.

### *Neuropsychological Test Protocol*

All patients underwent serial neuropsychologic assessment consisting of a broad battery of tests including the Wechsler Adult Intelligence Scale-Revised; Wechsler Memory Scale-Revised; Trail Making Test: Parts A and B; California Verbal Learning Test; Rey-Osterreith Complex Figure Test; Finger Tapping Speed; and Grip Strength. For

**TABLE 1: Diagnostic, demographic, and procedural data on patients undergoing osmotic blood-brain barrier disruption with intraarterial chemotherapy**

Patient	Sex/Age, y	Diagnosis	Chemotherapy	Number of Disruption Procedures				Total Procedures	Years since Diagnosis	Current Status
				RICA	LICA	LVA	RVA			
1	M/28	Germ	Carbo	6	6	6	0	18	2	Recurrent tumor Enhancing lesion
2	M/68	PCNSL	Metho	8	6	8	0	22	2	NED
3	M/47	PCNSL	Metho	6	8	7	0	21	2	NED
4	M/50	PCNSL	Metho	10	7	7	0	24	4	Recurrent tumor Enhancing lesion
5	F/64	PCNSL	Metho	7	8	9	0	24	6	NED
6	F/56	PCNSL	Metho	5	7	5	0	17	4	NED
7	M/66	PCNSL	Metho	9	10	6	1	26	1	Died, recurrent tumor
8	M/13	Germ	Carbo	5	6	8	0	19	2	Enhancing lesion Recurrent tumor Cerebrospinal fluid cytology
9	M/22	Astro	Metho	0	12	12	0	24	2	Recurrent tumor Hyperintensity on T2- weighted image
10	F/62	Astro	Both	11	9	0	0	20	2	NED
11	M /6	PCNSL	Metho	8	7	8	0	23	2	NED
12	F/15	Germ	Carbo	6	6	7	0	19	2	Recurrent tumor Cerebrospinal fluid cytology
13	M/43	PCNSL	Metho	7	8	8	0	23	2	NED
14	F/45	PCNSL	Metho	7	8	8	0	23	2	NED
15	F/24	PCNSL	Carbo	4	5	2	4	15	2	NED

Note.—Astro indicates astrocytoma; both, both carbo and metho regimens; carbo, carboplatin and etoposide regimen; germ, germinoma; LICA, left internal carotid artery; LVA, left vertebral artery; metho, methotrexate, cyclophosphamide, and procarbazine regimen; NED, no evidence of disease; PCNSL, primary central nervous system lymphoma; PNET, primitive neuroectodermal tumor; RICA, right internal carotid artery; and RVA, right vertebral artery.

children less than 8 years of age, the Stanford Binet Intelligence Scales (4th ed) was the only test administered. For children between 9 and 16 years of age, the Wechsler Intelligence Scale for Children–Revised, was substituted for the Wechsler Adult Intelligence Scale of Learning and Memory–Revised, the Wide Range Assessment of Learning and Memory was substituted for the Wechsler Memory Scale–Revised, the California Verbal Learning Test was omitted, and the age-appropriate version of the Trail Making Test was administered. The tests evaluated intellectual ability, verbal and spatial memory, visual perception and tracking, attention span and concentration, fine motor dexterity, and grip strength. Baseline assessments were completed 24 to 48 hours before the initial blood-brain barrier disruption procedure. Later testing occurred after completion of 1 year of therapy and subsequently at yearly intervals. Cognitive test results were included in this study only in patients with no evidence of recurrent or residual tumor. Treatment-related impairment or improvement was defined statistically as one standard deviation change from the patient's baseline performance.

#### *Neuropsychologic Test Analyses Method*

Consistent with previous research, each patient's level of function on an individual test was reported as a z score that was based on the mean and standard deviation of the reference population used in that test (3, 4). The z score was defined as the difference between an individual's test score and the mean of the reference population for that test divided by the standard deviation for that test. For example, a z score of  $-1$  signifies the patient scores one standard deviation below the mean for that test. This statistical conversion facilitates evaluation of test scores for patients with different characteristics that could invalidate direct comparison of raw scores, ie, across young adult and geriatric age groups. Conversion of raw data to z scores also enabled more meaningful comparison of results across different tests and made possible the computation of a global index of functioning. The patient's global level of functioning was the mean of the patient's z scores on the individual tests, which was reported as the global z score. In computing z scores for each test, the reference norms adopted were the appropriate age and gender


groups in the test manuals for the Wechsler Adult Intelligence Scale-Revised (15), the Wechsler Intelligence Scale for Children-Revised (16), the Stanford Binet Intelligence Scales SBIS (17), the Wechsler Memory Scale-Revised (18), the Wide Range Assessment of Learning and Memory (19), and the California Verbal Learning Test (20). The means and standard deviations for other tests were derived from published normative studies for the Rey-Osterreith Complex Figure Test and for the Trail Making Test, Finger Tapping Speed, and Grip Strength (21-23).

## Results

### *Imaging Results*

Ten patients showed no new abnormalities on repeat MR imaging as shown in Figure 1A

through E. Two of 15 patients, patient 6 and patient 9, developed new areas of hyperintensity on T2-weighted images involving a large portion of the white matter in the left cerebral hemisphere, a per-patient incidence of 15% as shown in Figure 2A through D. This was an incidence of 18% per patient in those receiving a regimen including intraarterial methotrexate, but none of the patients receiving intraarterial carboplatin developed these abnormalities. Although patients included in this study had no enhancement after blood-brain barrier disruption with intraarterial chemotherapy, the white-matter hyperintensity on T2-weighted images noted on the pretherapy scans persisted on the



(600/16/2) shows no residual enhancement and subacute hemorrhage in the left caudate nucleus (*black arrow*).

E, A T2-weighted image (2800/80/1) shows less periventricular hyperintensity than in part B (*black arrow*) and hemorrhage in the left caudate nucleus (*curved white arrow*).




Fig 2. Twenty-two-year-old man with a malignant astrocytoma (patient nine). A and B were obtained before disruption therapy; C and D were obtained 21 months after A and B.

A, Coronal enhanced T1-weighted image (600/20/2) shows enhancement in the left temporal region (*black arrow*).


B, Transaxial T2-weighted image (2800/80/1) at the level of the bodies of the lateral ventricles.

C, Posttreatment coronal enhanced T1-weighted image (700/15) shows resolution of enhancement (*black arrow*).

D, A transaxial T2-weighted image (3000/90) shows new areas of hyperintensity in the white matter of the left hemisphere (*black arrows*).

posttherapy scans in 12 of 15 patients. In patient 4, atrophy manifested as mild ventricular enlargement developed. In patient 13, a stroke developed with onset of left-hand dysesthesia, which appeared within 24 hours of disruption in the left internal carotid artery territory procedure; MR scanning showed a right thalamic infarct as shown in Figure 3A through D. Patient 5 was noted to have what appeared to be a right parietal infarct on routine follow-up imaging, but no evidence of neurologic deficit. The incidence of a new vascular lesion was two of 318 procedures, or 1%. These data are summarized in Table 2. In four patients (numbers 1, 8, 12, and 15) who received intraarterial carboplatin

in conjunction with osmotic blood-brain barrier disruption in the vertebral artery, high-frequency hearing loss developed. In six patients recurrent tumor developed. In patients 8 and 12, both with germinoma, the MR scans showed no evidence of disease at the time of recurrence, but cerebrospinal fluid cytology was positive. In patient 9, the residual hyperintensity of the white matter, which did not enhance, was proved at repeat biopsy to represent recurrent astrocytoma. The other 3 patients (patients 1, 4, and 7) all presented with enhancing lesions at the time of recurrence. The tumors recurred from 4 to 12 months after the last correlation of imaging and cognitive data.



### *Cognitive Results*

The baseline summary z score for each patient showed a wide range of functioning that ranged from significant impairment to normal levels as summarized in Table 2. No patient showed evidence of a global decline in cognitive function as defined by a decline of one standard deviation on global z score. Five patients showed improved global functioning evidenced by an improvement of at least one standard deviation in global z score. In patients with significant changes in individual cognitive test results from the pretherapy to the follow-up testing, the direction of change showed improvement in most cases. There were a few patients who showed decreases on certain individual tests, but these were rare and did not

suggest a pattern of selective impairment on any individual neuropsychologic function. The data for individual tests are summarized in Table 3. Figure 4 illustrates the results of cognitive testing in the 10 patients without new abnormalities on MR scanning. No patients showed evidence of decline in cognitive function, and 3 patients improved. In Figure 5, the cognitive results of patients with new abnormalities on MR scans are shown. Patients 6 and 13 improved; the other patients showed no change.

### **Discussion**

A 15% incidence of new white matter hyperintensity on T2-weighted images occurred in patients undergoing intraarterial chemotherapy

**TABLE 2: Global z scores and imaging changes before and after treatment of patients with blood-brain barrier disruption chemotherapy**

Patient	Pre-therapy Global Z Score	Post-therapy Global Z Score	New MR Abnormalities	Residual Hyperintensity
1	-2.59	-2.47	None	Present
2	0.62	1.06	None	Present
3	0.41	-0.06	None	Present
4	-2.00	-1.46	Atrophy	Present
5	-0.79	-0.57	Asymptomatic right parietal infarct	Present
6	-2.10	-0.41	Diffuse white matter hyperintensity in the left cerebral hemisphere	Present
7	-1.48	-0.87	None	Present
8	-0.42	0.61	None	Absent
9	-0.39	0.02	Diffuse white matter hyperintensity in the left cerebral hemisphere	Present
10	0.16	-0.17	None	Present
11	-1.53	-1.42	None	Present
12	-0.24	0.71	None	Absent
13	-0.08	1.21	Symptomatic right thalamic infarct	Present
14	-2.15	-0.32	None	Present
15	-0.93	0.07	None	Absent

Note.—Z score indicates the patient's raw score minus the sample mean for that test divided by the standard deviation for that test; the global z score is the mean of the patient's z score on the individual tests. Residual hyperintensity is areas of hyperintensity on T2-weighted images remaining in the white matter after completion of therapy.

with osmotic opening of the blood-brain barrier, which was at the low end of the range of 9% to 100% incidence of new white matter hyperintensity, which occurred in patients treated with radiation therapy and conventional chemotherapy (24–29). Prior studies have included patients with both radiation therapy and intravenous chemotherapy, so the rates of white matter abnormalities may be a result of a combination of chemotherapy and radiation therapy.

Intravenous methotrexate at a dose of 8 g/m<sup>2</sup> administered over 4 hours in patients with osteosarcoma has resulted in white matter hyperintensity in 64% of patients (30). The dose used in this study was 2.5 g given intravenously after blood-brain barrier disruption in about 10 minutes and a second dose of 2.5 g given 24 hours later. On a body surface area basis, this 5-g dose would be about 2.89 g/m<sup>2</sup>, a lower systemic dose than that given in the prior report. However, prior laboratory studies have

shown when osmotic blood-brain barrier modification with intraarterial chemotherapy is used, the procedure has resulted in 50- to 100-fold increased delivery of chemotherapeutic agent as compared with intravenous chemotherapy without barrier modification (31, 32). Therefore, the dose delivered to the brain was significantly higher than in this prior study. In the prior study, patients who received intravenous methotrexate developed white matter abnormalities, whereas those who received cisplatin did not show any imaging changes, similar to the results of this study. The reason for this increased incidence of white matter changes in the prior report, despite a lower delivered dose to the brain, is unclear. Increasing the antitumor agent delivery posed the potential for increased toxicity to normal brain, and extensive preclinical studies were performed for all agents in laboratory models before using them in patients (33, 34). Because no toxicity was demonstrated, the increased drug delivery associated with blood-brain barrier disruption was most likely not the cause of the MR abnormalities.

Recurrent tumor has developed in six of the 15 patients in this series. Three of the 6 recurrences occurred in the 12 patients with residual hyperintensity on T2-weighted image in post-therapy scans. The other 3 patients with recurrent tumor had no evidence of residual hyperintensity. New areas of white matter hyperintensity, which developed in patient 9, were shown to be a malignant astrocytoma on a later craniotomy. Patient 6 has shown no evidence of recurrence on clinical examination. Thus the pathologic correlate of the new white matter hyperintensity was unknown in this patient. These findings, though a small patient series that included different types of tumors, suggested that residual areas of hyperintensity were not a predictor for the risk of recurrent tumor. These data were consistent with the conclusion of a prior study in which it appears non-enhancing white matter lesions in cancer patients have questionable clinical significance (35, 36).

Enlargement of the ventricles developed in only 1 patient; most likely this mild enlargement was caused by regression of the primary central nervous system lymphoma, a tumor that is often periventricular, rather than by brain tissue loss (37). The incidence of atrophy in this series is (7%) less than the 46% to 100% incidence reported when conventional intravenous che-



**TABLE 3: Change in z scores on individual cognitive tests before and after treatment with osmotic blood-brain barrier disruption and intraarterial chemotherapy**

Patient	WAIS-R FSIQ	WMS-R GMI	WMS-R DRI	CFT Recall	VLT Index	WMS-R ACI	CFT Copy	TMT B	Tap	Grip	Summary
1	0.14	-0.13	0.00	1.11	0.25	-0.53	0.00	0.00	...	...	0.12
2	1.07	-0.53	-0.07	-0.44	0.19	-0.06	0.00	1.46	-0.33	1.27	0.44
3	-0.47	0.67	-0.47	0.88	-0.93	-1.20	0.33	-0.31	0.98	-4.63	-0.47
4	1.00	0.87	0.71	1.01	0.00	1.13	0.00	0.00	0.65	1.33	0.54
5	...	...	...	0.98	-0.90	...	0.78	...	1.12	-0.22	0.35
6	1.33	3.73	2.60	0.00	...	2.93	...	2.74	0.71	1.18	1.59
7	0.46	0.80	2.06	1.37	...	0.00	0.00	0.62	-0.76	-0.12	0.52
8	0.73	0.93*	...	1.39	1.50	...	0.97	1.06†	2.27	1.24	1.03
9	0.66	0.53	0.60	-0.22	1.42	0.88	2.00	-0.43	-0.31	0.17	0.41
10	0.54	0.28	1.60	...	0.62	-3.06	...	-1.38	-1.58	-0.05	-0.33
11	0.06‡	-0.69‡	...	...	...	0.00‡	1.07‡	...	...	...	0.11‡
12	1.07	0.74	3.26	0.95	0.17	0.60	0.31	0.28	1.51	0.65	0.95
13	0.87	0.74	2.06	2.16	3.47	1.47	2.64	0.33	0.51	-0.44	1.29
14	2.16	1.00	1.80	3.15	1.65	2.67	3.46	3.84	...	...	1.83
15	0.53	1.00	0.54	0.79	0.58	2.27	2.01	0.71	0.03	1.23	1.00
Summary											
Improved	5/14	3/14	6/12	6/13	4/12	5/13	5/13	4/13	3/12	5/12	5/15
Stable	9/14	11/14	6/12	7/13	8/12	6/13	9/13	8/13	8/12	6/12	10/15
Decreased	0/14	0/14	0/12	0/13	0/12	2/13	0/13	1/13	1/12	1/12	0/15

Note.—WAIS-R FSIQ indicates Wechsler Adult Intelligence Scale-Revised Full Scale IQ; WMS-R GMI, Wechsler Memory Scale-Revised General Memory Index; WMS-R DRI, Wechsler Memory Scale-Revised Delayed Recall Index; CFT recall, Rey-Osterreith Complex Figure Test Delayed Recall Trial; VLT index, Verbal Learning Test Index; WMS-R ACI, Wechsler Memory Scale Attention/Concentration Index; CFT copy, Rey-Osterreith Complex Figure Test Copy Trail; TMT B, Trail Making Test Part B; tap, finger tapping speed; and grip, grip strength. Z score is the patient's raw score minus the sample mean for that test divided by the standard deviation for that test; global z score is the mean of the patient's z score on the individual test.

\* WRAML: General memory.

† Intermediate form.

‡ Stanford Binet 4th edition (see "Patients and Methods").

motherapy and radiation therapy were combined (28, 38–40).

Two patients sustained vascular lesions diagnosed by imaging. In one of these patients a mild but permanent deficit developed indicating a rate of stroke of 0.3%, similar to the rate of angiographic complications reported in other studies (41–44). The other patient had a new right parietal infarct that showed enhancement and signal intensity characteristics of an infarct. This lesion was clinically silent and, because prior studies of neurologic complications from cerebral angiography have included only new neurologic symptoms as a stroke, this lesion would not be included as a stroke in those studies. A previously reported series of patients who did not have MR imaging before angiography suggested that a study might be performed to determine the incidence of silent infarction after cerebral angiography (45). This study of 318 procedures done before and after multiple angiographic procedures shows that cerebral angiography is not associated with a high inci-

dence of silent infarcts, although infarction did occur in 2 of the 15 patients in this study.

The neuropsychological test results in this study compared favorably with other published findings of brain tumor treatment outcomes assessed in a similar manner. In one series, patients surviving longer than 2 years with malignant astrocytomas treated with radiation (60 Gy) followed by variable intravenous chemotherapy regimens, showed declines in psychometric performance (10). These declines on cognitive testing preceded either clinical deterioration on neurologic examination or CT evidence of tumor recurrence. Another study of 13 patients who received 45 Gy to the whole brain and a 15-Gy tumor boost with intravenous lomustine therapy showed deterioration on cognitive testing in all patients (7). Metaanalysis of many studies showed radiotherapy to be associated with a 27% incidence of cognitive deterioration (46). Other therapies seem to be associated with a higher incidence of cognitive deterioration than the regimen reported here.




Fig 4. Note comparison of cognitive test results versus time in 10 patients not showing new changes on MR after blood-brain barrier disruption and intraarterial chemotherapy.

This study showed new MR abnormalities in some brain tumor patients treated with osmotic blood-brain barrier disruption and intraarterial chemotherapy. No patient showed cognitive deterioration, although one patient had right hand dysesthesias and left thalamic infarct. And therefore, MR abnormalities did not correlate with the results of cognitive testing. This discrepancy may exist because MR may show structural abnormalities before they become clinically manifested or because MR changes do not have functional significance. New white matter abnormalities did not correlate with either diminished global cognitive function or selective deficits in this series, a result consistent with prior studies (24, 29, 47–49).

Imaging abnormalities but no cognitive sequelae were associated with blood-brain barrier disruption and intraarterial chemotherapy therapy. Future plans are to include patients who undergo cranial radiation therapy, before or after disruption therapy, in the analysis of imaging and cognitive sequelae of disruption therapy. Prior studies evaluating cognitive or imaging




Fig 5. Note comparison of cognitive test results in five patients showing new changes on MR after blood-brain barrier disruption (BBBD) and intraarterial chemotherapy.

sequelae of brain tumor therapies have included patients treated with both chemotherapy and radiation therapy in different dose regimens and variable sequences. Therefore the contributions of radiation therapy and chemotherapy to either structural or functional abnormalities were difficult to assess (7, 10, 28, 29, 38–40). Expanding this protocol may answer questions concerning the relative contribution of radiation therapy and chemotherapy to neurologic toxicity and may help clarify the role of different sequences of radiotherapy and chemotherapy in the development of imaging or neuropsychologic abnormalities (49–52).

### Conclusion

Five of 15 patients undergoing osmotic blood-brain barrier disruption with intraarterial chemotherapy administration developed new abnormalities on MR imaging, but no cognitive deterioration occurred, although in one patient a neurologic deficit corresponding to a left thalamic infarct developed.

Because brain tumor therapies may be associated with cognitive deterioration or new MR imaging changes, patients should undergo systematic evaluations with MR imaging and cognitive testing.

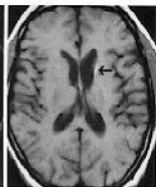
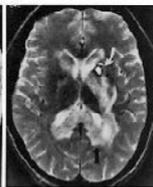
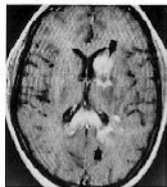## Acknowledgments

We thank Mr Raymond Hogan and Ms Annie Grummel, adult nurse practitioners and clinical coordinators of the Blood-Brain Barrier Program at the Oregon Health Sciences University, for their clinical expertise and assistance in data collection. We also thank Ms Jan Bullard for editorial assistance.

## References

- Neuwelt EA, Frenkel EP, Gumerlock MK, Brazier R, Dana B, Hill SA. Developments in the diagnosis and treatment of primary CNS lymphoma: a prospective series. *Cancer* 1986;58:1609-1620
- Neuwelt EA, Howieson J, Frenkel EP, et al. Therapeutic efficacy of multiagent chemotherapy with drug delivery enhancement by blood-brain barrier modification in glioblastoma. *Neurosurgery* 1986;19:573-582
- Neuwelt EA, Goldman D, Dahlborg SA, et al. Primary CNS lymphoma treated with osmotic blood-brain barrier disruption: prolonged survival and preservation of cognitive function. *J Clin Oncol* 1991;9:1580-1590
- Crossen JR, Goldman DL, Dahlborg SA, Neuwelt EA. Neuropsychological assessment outcomes of nonacquired immunodeficiency syndrome patients with primary central nervous system lymphoma before and after blood-brain barrier disruption chemotherapy. *Neurosurgery* 1992;30:23-29
- Valk PE, Dillon WP. Radiation injury of the brain. *AJNR Am J Neuroradiol* 1991;12:45-62
- Archibald YM, Lunn D, Rutan LA, et al. Cognitive functioning in long-term survivors of high-grade glioma. *J Neurosurg* 1994;80:247-253
- Hochberg FH, Slotnick B. Neuropsychologic impairment in astrocytoma survivors. *Neurology* 1980;30:172-177
- Lee PWH, Hung BKM, Woo EKW, Tai PTH, Choi DTK. Effects of radiation therapy on neuropsychological functioning in patients with nasopharyngeal carcinoma. *J Neurol Neurosurg Psychiatr* 1989;52:488-492
- Johnson BE, Becker B, Goff WB, et al. Neurologic, neuropsychologic, and computed cranial tomography scan abnormalities in 2- to 10-year survivors of small-cell lung cancer. *J Clin Oncol* 1985;3:1659-1667
- Johnson BE, Patronas N, Hayes W, et al. Neurologic, computed cranial tomographic, and magnetic resonance imaging abnormalities in patients with small-cell lung cancer: further follow-up of 6- to 13-year survivors. *J Clin Oncol* 1990;8:48-56
- Laukkanen E, Klonoff H, Allan B, Graeb D, Murray N. The role of prophylactic brain irradiation in limited stage small cell lung cancer: clinical, neuropsychological, and CT sequelae. *Int J Radiat Oncol Biol Phys* 1988;14:1109-1117
- Lieberman AN, Foo SH, Ransohoff J, et al. Long term survival among patients with malignant brain tumors. *Neurosurgery* 1982;10:450-453
- MacDonald DR, Cascino TL, Schold SC, Cairncross JG. Response criteria for phase II studies of supratentorial malignant glioma. *J Clin Oncol* 1990;8:1277-1280
- Roman-Goldstein SM, Clunie DA, Stevens J, et al. Computed tomography and radionuclide imaging of osmotic blood-brain barrier disruption. *AJNR Am J Neuroradiol* 1994;15:581-590
- Wechsler D. *Wechsler Adult Intelligence Scale, Revised*. New York: Psychological Corporation, 1981
- Wechsler D. *Wechsler Intelligence Scale for Children, Revised*. New York: Psychological Corporation, 1974
- Thorndike RL, Hagen EP, Satler JM. *Stanford Binet Intelligence Scale*. 4th ed. Chicago: Riverside, 1986
- Wechsler D. *Wechsler Memory Scale, Revised*. San Antonio: Psychological Corporation, 1987
- Sheslow D, Adams W. *Wide Range Assessment of Memory and Learning*. Wilmington, Delaware: Jastak, 1990
- Delis DC, Kramer JH, Kaplan E, Ober BA. *California Verbal Learning Test: Research Ed*. San Antonio: Psychological Corporation, 1987
- Bornstein RA. Normative data on selected neuropsychological measures from a nonclinical sample. *J Clin Psychol* 1985;41:651-659
- Kolb B, Whishaw IQ. *Fundamentals of Human Neuropsychology*. New York: Freeman Press, 1985
- Spreen L, Strauss E. *A Compendium of Neuropsychological Tests*. New York: Oxford, 1991
- Constine LS, Konski A, Ekholm S, McDonald S, Rubin P. Adverse effects of brain irradiation correlated with MR and CT imaging. *Int J Radiat Oncol Biol Phys* 1988;15:319-330
- Curran WJ, Hecht-Leavitt C, Schut L, Zimmerman RA, Nelson DF. Magnetic resonance imaging of cranial radiation lesions. *Int J Radiat Oncol Biol Phys* 1987;13:1093-1098
- Dooms GC, Hecht S, Brant-Zawadzki M, Berthiaume Y, Norman D, Newton TH. Brain radiation lesions: MR imaging. *Radiology* 1986;158:149-155
- Frytak S, Earnest F, O'Neill BP, Lee RE, Creagan ET, Trautmann JC. Magnetic resonance imaging for neurotoxicity in long-term survivors of carcinoma. *Mayo Clin Proc* 1985;60:803-812
- Hazuka MB, Kinzie JJ, Davis KA, DeBoise DA. Treatment-related central nervous system toxicity: MR imaging evaluation with CT and clinical correlation. *Magn Reson Imaging* 1989;7:669-676
- Tsuruda JS, Kortman KE, Bradley WG, Wheeler DC, Van Dalsem W, Bradley TP. Radiation effects on cerebral white matter: MR evaluation. *AJNR Am J Neuroradiol* 1987;8:431-437
- Lien HH, Blomlie V, Saeter G, Solheim O, Fossa SD. Osteogenic sarcoma: MR signal abnormalities of the brain in asymptomatic patients treated with high dose methotrexate. *Radiology* 1991;179:547-550
- Neuwelt EA, Frenkel EP, Rapoport S, Barnett P. Effect of osmotic blood-brain-barrier disruption on methotrexate pharmacokinetics in the dog. *Neurosurgery* 1980;7:36-43
- Neuwelt EA, Frenkel EP, D'Agostino AN, et al. Growth of human lung tumor in the brain of the nude rat as a model to evaluate antitumor agent delivery across the blood-brain-barrier. *Cancer Res* 1985;45:2827-2833
- Neuwelt EA, Glasberg M, Frenkel E, Barnett P. Neurotoxicity of chemotherapeutic agents after blood-brain barrier modification: neuropathological studies. *Ann Neurol* 1983;14:316-324
- Neuwelt EA, Pagel M, Barnett P, Glasberg M, Frenkel EP. Pharmacology and toxicity of intracarotid adriamycin administration following osmotic blood-brain barrier modification. *Cancer Res* 1981;41:4466-4470
- Elster AD, Chen MYM. Can nonenhancing white matter lesions in cancer patients be disregarded? *AJNR Am J Neuroradiol* 1992;13:1309-1315

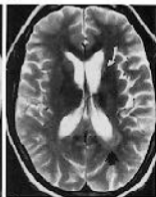
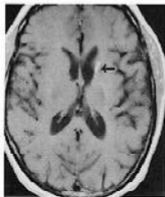
36. Heier LA, Zimmerman RD. Commentary: can nonenhancing white matter lesions be disregarded? *AJNR Am J Neuroradiol* 1992;13:1316-1318
37. Roman-Goldstein SM, Goldman DL, Howieson J, Belkin R, Neuwelt EA. MR of primary CNS lymphoma in immunologically normal patients. *AJNR Am J Neuroradiol* 1992;13:1207-1213
38. Asai A, Matsutani M, Kohno T, et al. Subacute brain atrophy after radiation therapy for malignant brain tumor. *Cancer* 1989;63:1962-1974
39. Packer RJ, Zimmerman RA, Bilaniuk LT. Magnetic resonance imaging in the evaluation of treatment-related central nervous system damage. *Cancer* 1986;58:635-640
40. So NK, O'Neill BP, Frytak S, Eagan RT, Earnest F, Lee RE. Delayed leukoencephalopathy in survivors with small lung cell cancer. *Neurology* 1987;37:1198-1201
41. Dion JE, Gates PC, Fox AJ, Barnett HJM, Blom RJ. Clinical events following neuroangiography: a prospective study. *Stroke* 1987;18:997-1004
42. Earnest F, Forbes G, Sandok BA, et al. Complications of cerebral angiography: prospective assessment of risk. *AJNR Am J Neuroradiol* 1983;4:1191-1197
43. Hankey GJ, Warlow CP, Sellar RJ. Cerebral angiographic risk in mild cerebrovascular disease. *Stroke* 1990;21:209-222
44. Waugh JR, Sacharias N. Arteriographic complications in the DSA era. *Radiology* 1992;182:243-246
45. Mamourian A, Drayer BP. Clinically silent infarcts shown on MR after cerebral angiography. *AJNR Am J Neuroradiol* 1990;11:1084
46. Crossen JR, Garwood D, Glatstein E, Neuwelt EA. Neurobehavioral sequelae of cranial irradiation in adults: a review of radiation-induced encephalopathy. *J Clin Oncol* 1994;12:627-642
47. Miller BL, Lesser IM, Boone KB, Hill E, Mehringer CM, Wong K. Brain lesions and cognitive function in late-life psychosis. *Br J Psych* 1991;158:76-82
48. Rao SM, Mittenberg W, Bernardin L, Haughton V, Leo GJ. Neuropsychological test findings in subjects with leukoaraiosis. *Arch Neurol* 1989;46:40-44
49. Kramer JH, Norman D, Brant-Zawadzki M, Ablin A, Moore IM. Absence of white matter changes on magnetic resonance imaging in children treated with CNS prophylaxis therapy for leukemia. *Cancer* 1988;61:928-930
50. Allen JC. What we learn from infants with brain tumors. *N Engl J Med* 1993;328:1780-1781
51. Duffner PK, Horowitz ME, Krischer JP, et al. Postoperative chemotherapy and delayed radiation in children less than three years of age with malignant brain tumors. *N Engl J Med* 1993;328:1725-1731
52. Mulhern RK, Horowitz ME, Kovnar EH, Langston J, Sanford RA, Kun LE. Neurodevelopmental status of infants and young children treated for brain tumors with preirradiation chemotherapy. *J Clin Oncol* 1989;7:1660-1666



A

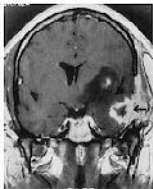
B

C

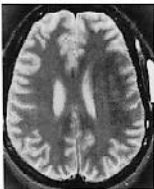

D

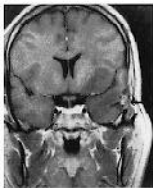E



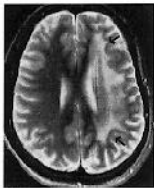A



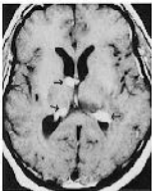
B



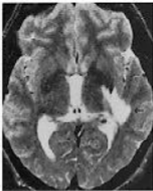
C



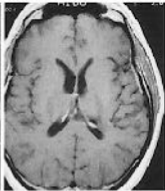
D



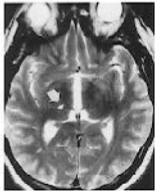
A



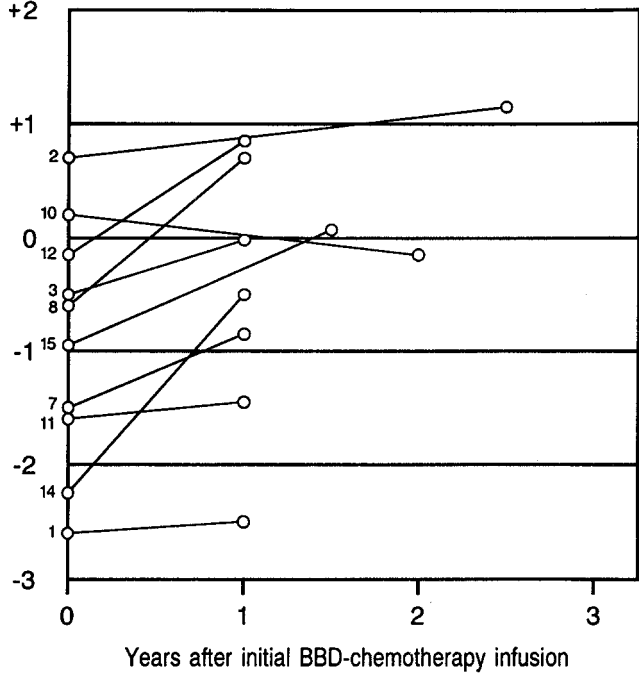
B



C

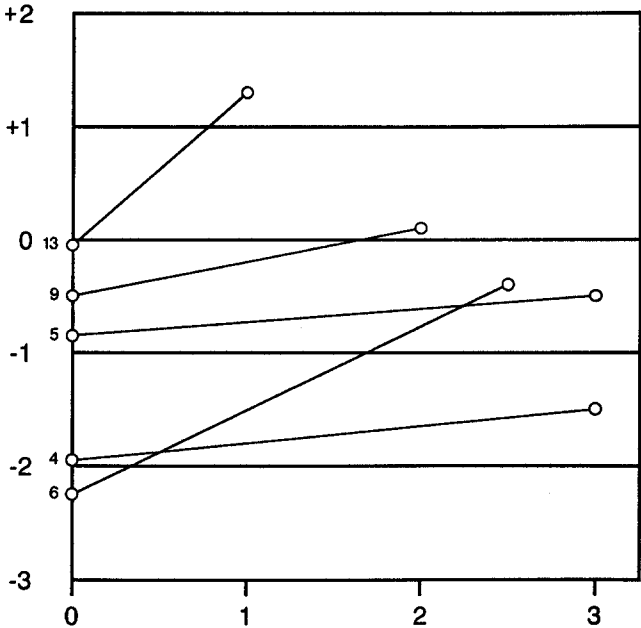


D



Small numbers to the left of data represent patient number





Years after initial BBD-chemotherapy infusion

Small numbers to the left of data represent patient number