

Are your **MRI contrast agents** cost-effective?

Learn more about generic **Gadolinium-Based Contrast Agents**.



FRESENIUS
KABI

caring for life

AJNR

Postgadolinium enhancement of a compressive neuropathy of the optic nerve.

M A Grimm, T Hazelton, R W Beck and F R Murtagh

AJNR Am J Neuroradiol 1995, 16 (4) 779-781

<http://www.ajnr.org/content/16/4/779>

This information is current as
of May 4, 2024.

Postgadolinium Enhancement of a Compressive Neuropathy of the Optic Nerve

Michael A. Grimm, Todd Hazelton, Roy W. Beck, and F. Reed Murtagh

Summary: We report the MR and CT findings of a case of postgadolinium signal enhancement of the optic nerve secondary to an extrinsically compressive lesion in a 24-year-old woman with hypertrophy of the anterior clinoid.

Index terms: Nerves, optic (II); Orbits

Although enhancement on magnetic resonance (MR) images is more characteristic of an inflammatory process or an intrinsic tumor than a compressive neuropathy (1), the following case demonstrates a compressive optic neuropathy with associated contrast enhancement on MR.

Case Report

A 24 year-old white woman presented with decreased vision in her right eye detected by routine driver's license examination in January 1989. Initially, the patient noted no deficit, although the visual acuity in the right eye was 20/50 as compared with 20/20 in the left eye. In addition, the patient correctly identified only 2 of 10 color plates with the right eye. The patient was felt to have a right optic neuropathy, but nothing in the history suggested a specific cause.

The patient's medical history was unremarkable, but a sister had multiple sclerosis and an uncle died of a brain tumor of unknown type. Endocrine abnormalities were not present at time of presentation, nor was there any history of precocious puberty. There was no abnormal pigmentation on physical examination.

Initial MR on a 1.5-T system (General Electric, Signa, Milwaukee, Wis) on June 27, 1989 (Fig 1A) revealed increased signal intensity of the right optic nerve at the level of the optic foramen after gadolinium injection. The white matter appeared normal, as did the left optic nerve and foramen, and the optic chiasm. The right anterior clinoid was noted to be larger than the left. The differential diagnoses at this point included optic neuritis secondary to any number of diseases, especially multiple sclerosis, in-

tracanalicular meningioma, venous congestion, and fibrous dysplasia (1).

The patient's visual acuity and color recognition continued to deteriorate over the next couple of months despite a course of steroids, and her right optic disk was completely pale when compared with the left optic disk on August 3, 1989. Follow-up MR was performed on January 2, 1990 in light of progressive unilateral loss of vision. Postgadolinium view demonstrated increasing optic nerve enhancement in the posterior portion of the optic canal. The area of enhancement extended to 1 to 2 mm anterior to the optic chiasm and involved the subarachnoid space adjacent to the hypertrophied anterior clinoid (Fig 1B).

Pterional craniotomy and exploration for presumed meningioma on June 6, 1990 revealed no such tumor. No disease of any kind was noted except for hypertrophy of the anterior clinoid overlying the right optic nerve, presumably causing compression. The patient's vision has continued to deteriorate, and she currently has no vision in her right eye, whereas the left eye manifests no visual deficit. A 2-year postoperative MR showed slight impingement of the optic nerve by the anterior clinoid within the optic canal and contrast enhancement of the optic nerve. Angled axial computed tomography (CT) confirmed significant narrowing of the optic canal secondary to anterior clinoid hypertrophy (Fig 1C). A three-dimensional reconstruction of the CT data demonstrated the hypertrophied anterior clinoid (Fig 1D). Although the consistency of the bone appeared homogeneous, anterior clinoid fibrous dysplasia remains the most likely presumptive diagnosis of the compressive neuropathy. Unfortunately, the patient has refused further surgery but is regularly followed every 3 months.

Discussion

Fibrous dysplasia is a condition in which bone marrow is replaced by fibrous tissue with incomplete maturation of mesenchymal tissue (2). It is either monostotic or polyostotic

Received September 9, 1992; accepted after revision June 30, 1993.

From the Departments of Radiology (M.A.G., T.H.), Neuro-Ophthalmology (R.W.B.), and Radiology and Neuroradiology (F.R.M.), University of South Florida, Tampa.

Address reprint requests to F. Reed Murtagh, MD, Department of Radiology and Neuroradiology, University Diagnostic Institute, University of South Florida, 3301 W Oak Dr, Tampa, FL 33612-9413.

AJNR 16:779-781, Apr 1995 0195-6108/95/1604-0779 © American Society of Neuroradiology

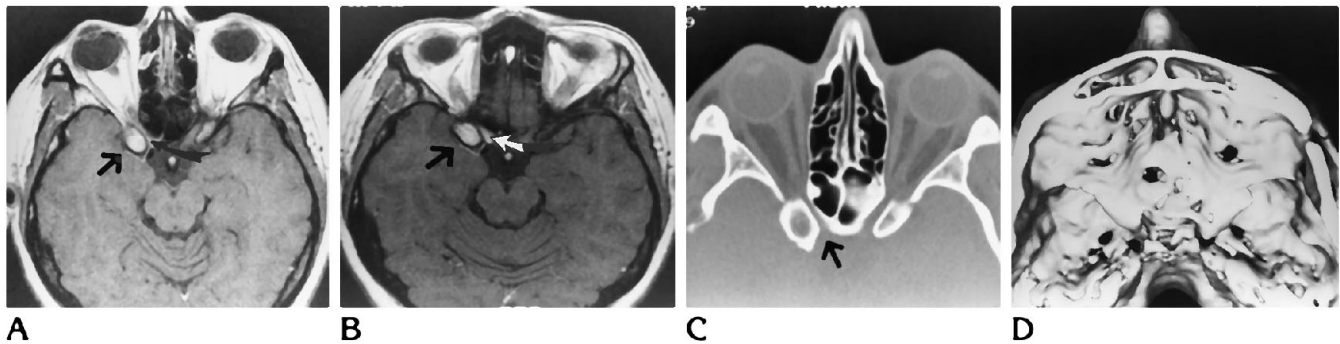


Fig 1. A, Gadolinium-enhanced MR (600/20 [repetition time/echo time]) on a 1.5-T system on June 27, 1989. *Straight arrow* depicts hypertrophied anterior clinoid, and the *curved arrow* depicts increased signal intensity of the right optic nerve.

B, Follow-up gadolinium-enhanced MR on January 2, 1990 with *straight arrow* again depicting hypertrophied anterior clinoid and the *white arrow* demonstrating increasing enhancement of the right optic nerve that extended to 1 to 2 mm anterior to the optic chiasm.

C, Angled axial CT with arrow showing narrowing of the optic canal secondary to anterior clinoid hypertrophy.

D, Three-dimensional reconstruction demonstrating the hypertrophied anterior clinoid, which is now on the viewer's right.

and accounts for 2.5% of all bone tumors and more than 7% of nonmalignant bone tumors (3). Fibrous dysplasia is sometimes associated with endocrine abnormalities or hyperpigmentation, neither of which this patient manifested. In a study by Edgerton, et al, the sphenoid bone was the second most commonly involved of the craniofacial bones and frequently presented with symptoms of optic nerve compression (3). However, rarely has fibrous dysplasia been described in an area as focal as the anterior clinoid, and never, to our knowledge, has anterior clinoid fibrous dysplasia compressed the optic nerve resulting in contrast enhancement. It is the combination of both of these occurrences that has contributed to our diagnostic dilemma.

The original MR study in this patient revealed enhancement of the right optic nerve on post-gadolinium T1-weighted images. This enhancement could have been consistent with optic neuritis, intracanalicular meningioma, or venous congestion.

Optic neuritis can be associated with any number of diseases including radiation, ischemia, systemic lupus erythematosus, and sarcoid, but it is most commonly associated with multiple sclerosis (4). The inflammation and edema associated with optic neuritis cause a disruption of the blood-brain barrier and allow leakage of contrast material, which then enhances on MR images (1). Optic neuritis was the presumed diagnosis until follow-up scans revealed that the amount of enhancement was increasing in intensity and size. Although the clinical findings on presentation resembled

those of optic neuritis, the progressive loss of vision in the absence of pain on movement of the globe has persisted over 3 years. Optic neuritis typically improves within 2 to 6 weeks. In addition, no other etiologic factors of optic neuritis have been demonstrated either on radiologic or metabolic studies.

Optic nerve meningiomas are extremely rare, especially in young adults, but had to be considered in this patient given the findings of central scotoma, painless and progressive visual loss, and optic atrophy. The progressive nature of the vision loss and the 1.5×1.0 -cm oblong signal enhancement along the lateral aspect of the right optic nerve were the contributing factors to the exploratory craniotomy for excisional biopsy of an intracanalicular meningioma. No tumor was found, but the anterior clinoid was noted from above to be hypertrophied and is probably compressing the optic nerve.

The patient has lost all vision in her right eye and a 2-year postoperative MR again has revealed signal enhancement in the right optic nerve and contiguous portion of the canal. A 3-D reconstruction showed a significant narrowing of the right optic canal. It is our contention that the compression and subsequent compromise of the right optic nerve is caused by a focal area of fibrous dysplasia that is demonstrating increased bone production but no abnormality of bone consistency. The typical CT findings of widened diploë and a ground-glass marrow appearance and the typical MR finding of altered marrow signal were not present in this particular case. However, the focal area extend-

ing from the anterior clinoid is compromising the lateral portion of the canal and producing characteristic clinical symptoms of fibrous dysplasia, but uncharacteristic postgadolinium signal enhancement.

According to Clifford-Jones et al, the foremost pathologic finding in extrinsic optic nerve compression of a longstanding nature is focal loss of the myelin sheath around intact optic nerve axons (5). Myelin does not contribute to the MR image because its protons are relatively immobile (6). Thus, the signal from a noncontrasted compressive neuropathy may be completely normal. It is possible that our patient's compressive neuropathy may have been associated with enough disruption of the blood-brain barrier as to allow contrast leakage and subsequent postgadolinium enhancement. However, this does not explain why other extrinsic compressive neuropathies do not enhance with gadolinium. In our patient, fibrous dysplasia re-

mains the likely diagnosis because of its progressive nature and its adolescent-young adult predilection.

References

1. Merandi SF, Kudryk BT, Murtagh FR, Arrington JA. Contrast-enhanced MR imaging of optic nerve lesions in patients with acute optic neuritis. *AJNR Am J Neuroradiol* 1991;12:923-926
2. Donoso LA, Margargal LE, Eiferman RA. Fibrous dysplasia of the orbit with optic nerve decompression. *Ann Ophthalmol* 1982;14:80-83
3. Edgerton MT, Pershing JA, Jane JA. The surgical treatment of fibrous dysplasia with emphasis on recent contributions from cranio-maxillo-facial surgery. *Ann Surg* 1985;34:124-128
4. Johns K, Lavin P, Elliot JH, Partain CL. Magnetic resonance imaging of the brain in isolated optic neuritis. *Arch Ophthalmol* 1986;104:1486-1488
5. Clifford-Jones RE, McDonald WI, Landon DN. Chronic optic nerve compression: an experimental study. *Brain* 1985;108:241-262
6. Bottomley PA, Hart HR, Edelstein WA, et al. Anatomy and metabolism of the normal human brain studied by magnetic resonance at 1.5 Tesla. *Radiology* 1984;150:441-446