

Are your **MRI contrast agents** cost-effective?

Learn more about generic **Gadolinium-Based Contrast Agents**.



FRESENIUS
KABI

caring for life

AJNR

Spiral CT scanning of the paranasal sinuses.

J N Suojanen and F Regan

AJNR Am J Neuroradiol 1995, 16 (4) 787-789

<http://www.ajnr.org/content/16/4/787>

This information is current as
of April 17, 2024.

Spiral CT Scanning of the Paranasal Sinuses

James N. Suojanen and Fintan Regan

Summary: Because of the interest in reducing the time and radiation required for screening sinuses with CT, we compared the quality of conventional coronal CT images with coronally reconstructed, axially acquired spiral CT images. The spiral reconstructions compared favorably with the conventional images and had significantly less motion and dental amalgam artifacts.

Index terms: Paranasal sinuses, computed tomography; Computed tomography, technique

With the advent of endoscopic sinus surgery and a better understanding of paranasal sinus physiology, coronal computed tomography (CT) has become the modality of choice for the evaluation of sinus disease (1). Concerns regarding radiation exposure, costs, and imaging times have arisen, particularly when the axial plane needs to be imaged (2). This has led several authors to suggest methods for maximizing diagnostic information with limited studies (2–4). However, not all patients can assume or maintain the position for this study and a limited examination usually requires that a patient with significant disease have a more comprehensive study performed later. Depending on the rate of reexamination in a given practice, any savings of time, money, or radiation dosage may not be realized.

Spiral or helical CT scanning is a new technique that has proved useful in the evaluation of the head and neck (5). Because it permits rapid volumetric data acquisition, spiral CT scanning should permit reconstructions of high quality so that images might only need to be acquired in one plane. Additionally, because it often uses a reduced-milliampere-second technique, radiation exposure for all patients would be reduced. To determine whether this technique could produce an acceptable imaging evaluation of the

paranasal sinuses, we compared the diagnostic quality of axially acquired spiral CT images reconstructed coronally to those of conventionally acquired coronal images.

Materials and Methods

Thirty patients were studied prospectively on a Somatom Plus-S CT scanner (Siemens; Iselin, NJ). Fourteen were men and 16 were women. Ages ranged from 21 to 79 years (mean age, 45.9 years). Three patients were unable to maintain the head position for direct coronal images. Conventional images were obtained using 5-mm-section collimation at 4-mm intervals with 120 kV and 250 mAs. Axially acquired spiral data used 2-mm-section collimation and 3-mm/s table feed (pitch, 1.5) for 30 seconds, with 120 kV and 165 mAs. The images were then reconstructed at 1-mm increments. Coronally reconstructed images 0.3 mm thick were then obtained at 4-mm increments. All data were processed using a bone (ultrahigh) algorithm. The coronal images were compared by two independent observers (one senior member of the American Society of Neuroradiology) who evaluated the detail of ostiomeatal unit anatomy, anatomic detail elsewhere, lesion conspicuity, and freedom from both dental amalgam and motion artifacts. Scores of 1 to 3 were assigned (fair to excellent). Differences were assessed using standard parametric statistical techniques, and differences were considered significant when $P < .05$. Interobserver variability was assessed using a κ test (6).

Results

All of the scans were of diagnostic quality. The interobserver κ was .61, indicating very good agreement beyond chance. Both the reconstructed images and the direct images showed the ostiomeatal anatomy and anatomic detail equally well, although the conventional scan scores were higher and the reconstructed images did have some step artifact (Table, Fig-

Received July 27, 1993; accepted after revision December 23.

Presented in part at the 31st Annual Meeting of the American Society of Neuroradiology, Vancouver, Canada, May 1993, and at the 79th Annual Meeting of the Radiological Society of North America, Chicago, December, 1993.

From the Department of Radiological Sciences, Deaconess Hospital and Harvard Medical School, Boston, Mass (J.N.S.); and the Department of Radiology, Francis Scott Key Medical Center, Baltimore, Md (F.R.).

Address reprint requests to James N. Suojanen, MD, Department of Radiological Sciences, Deaconess Hospital, 1 Deaconess Rd, Boston, MA 02215.

Comparison of spiral reconstruction with direct coronal images*

	Ostiomeatal Unit Anatomy	Bone Detail	Lesion Conspicuity	Freedom from Artifact
Reconstructions	2.45 ± 0.69	2.50 ± 0.51	2.64 ± 0.50	2.97 ± 0.10
Direct	2.55 ± 0.69	2.70 ± 0.47	2.57 ± 0.51	2.05 ± 0.60
	NS	NS	NS	Difference, $P < .005$

Note.—NS indicates no significant difference.

* Images were graded on a scale of 1 (fair) to 3 (excellent) by two independent observers; mean scores ± SD are given; 27 subjects were studied.

ure 1). Lesion conspicuity was not significantly different, although the reconstructed images did not show minimal mucosal thickening or some fine ethmoidal septa. The reconstructed images were significantly freer from artifact than the conventional images (Table, Figure 2). None of the reconstructed images was compromised by patient motion during the spiral scan.

Discussion

Spiral CT scanning of the paranasal sinuses produces images of diagnostic quality comparable to that of directly acquired images, without degradation from motion or dental amalgam artifacts. The reconstructed spiral images did not demonstrate minimal membranous thickening or some fine ethmoidal septations

because of lower anatomic resolution. That is, assuming a 25-cm field of view, direct coronal images with a 512×512 matrix give a 0.49×0.49 -mm pixel. The spiral axial images are spaced 1 mm apart, so the pixel size will be 0.49×1.00 mm for the coronally reconstructed images. However, this slightly decreased resolution did not significantly affect clinically important anatomic detail.

The spiral technique offers other advantages as well. In our study, the spiral data were acquired in a single plane with reduced-milliamperes-second techniques (165 mAs versus 250 mAs), with a pitch of more than 1 (pitch, 1.5), and with no gantry angulation. All of these factors act to reduce patient radiation dose, although we have done no phantom studies. Theoretically, dosages in the spiral studies will be of

Fig 1. Direct conventional coronal CT image (A) and coronal reconstruction (B) from axial spiral CT images at the level of the infundibulum (arrow) and uncinate processes. Some of the fine ethmoidal septae (curved arrow) are not as well demonstrated on the reconstruction.

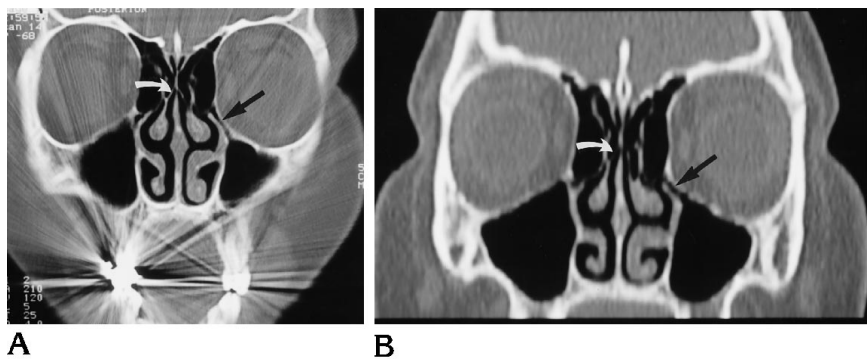
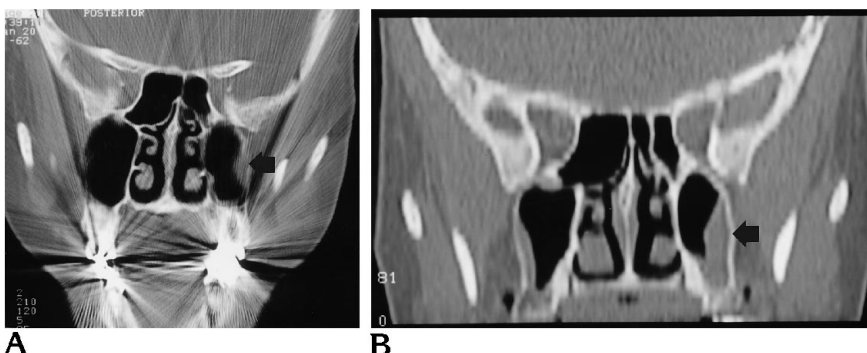


Fig 2. Direct (A) and reconstructed (B) coronal images through the posterior maxillary sinuses show some soft tissue along the wall (arrows), which is partially obscured by artifact from dental amalgam in A.



the same order of magnitude as conventional low-dose CT done in two planes (4). Additionally, patients need not flex their necks; 10% of our patients could not assume and/or maintain the position for direct coronal images. The spiral data could also be reconstructed in multiple planes or three-dimensionally without additional special processing, scanning time, or irradiation. These imaging capabilities can be important when studying patients with tumors or after trauma (7, 8).

Spiral CT scanning techniques are currently capable of producing diagnostically useful studies of the paranasal sinuses quickly and with reduced-milliampere-second techniques. As computer hardware continues to be improved, the speed and quality of image reconstructions should improve sufficiently so that this will become the CT technique of choice for both screening and complete examinations in this region.

References

1. Mafee MF. Preoperative imaging anatomy of nasal-ethmoid complex for functional endoscopic sinus surgery. *Radiol Clin North Am* 1993;31:1-20
2. White PS, Cowan IA, Robertson MS. Limited CT scanning techniques of the paranasal sinuses. *J Laryngol Otol* 1991;105:20-23
3. Babbel R, Harnsberger HR, Nelson B, Sonkens J, Hunt S. Optimization of techniques in screening CT of the sinuses. *AJNR Am J Neuroradiol* 1991;12:849-854
4. Marmolya G, Wiesen EJ, Yagan R, Haria CD, Shah AC. Paranasal sinuses: low-dose CT. *Radiology* 1991;181:689-691
5. Suojanen JN, Mukherji SK, Dupuy DE, Takahashi JH, Costello P. Spiral CT in evaluation of head and neck lesions: work in progress. *Radiology* 1992;183:281-283
6. Fleiss JL. The measurement of interrater agreement. In: Fleiss JL, ed. *Statistical Methods for Rates and Proportions*. 2nd ed. New York: John Wiley & Sons, 1981:212-225
7. Zinreich SJ, Mattox DE, Kennedy DW, et al. 3-D CT for cranial facial and laryngeal surgery. *Laryngoscope* 1988;98:1212-1219
8. Kassel EE. Traumatic injuries of the paranasal sinuses. *Otolaryngol Clin North Am* 1988;21:455-493