AJNR

MR appearance of the persistent hypoglossal artery.

N Fujita, N Shimada, H Takimoto and T Satou

AJNR Am J Neuroradiol 1995, 16 (4) 990-992
http://www.ajnr.org/content/16/4/990

MR Appearance of the Persistent Hypoglossal Artery

Norihiko Fujita, Nobumitsu Shimada, Hiroshi Takimoto, and Tadayuki Satou

Summary: We describe the MR appearance of the persistent hypoglossal artery incidentally found in a case of known glioblastoma multiforme. On the spin-echo images, an abnormal tubular structure of low intensity penetrating the hypoglossal canal was recognized. MR angiography showed its vascular nature and the anomalous vessel connecting the internal carotid and basilar arteries.

Index terms: Arteries, abnormalities and anomalies; Arteries, hypoglossal

The persistent hypoglossal artery, a persistent carotid-basilar anastomosis, is a rare vascular anomaly. We describe a case of a persistent hypoglossal artery suspected on initial spin-echo magnetic resonance (MR) examination and confirmed with subsequent MR angiography.

Case Report

A 52-year-old man who had undergone an operation for glioblastoma multiforme was admitted for further care. He was referred for an MR examination to evaluate the present state of the tumor. A spin-echo MR examination of the whole brain with and without gadopentetate dimeglumine showed a large tumor in the right supratentorial region. Although the tumor did not extend to the posterior fossa, an abnormal tubular structure of low intensity was noted on the most caudal section (Fig 1A). This extended from the premedullary cistern to the extracranial region on the right side through the hypoglossal canal. Because an abnormal vascular structure was suspected on the basis of the spin-echo finding, three-dimensional time-of-flight MR angiography was done 2 days after the initial MR examination. The original section (Fig 1B) and the reformatted MR angiograms (Fig 1C and D) showed communication between the right internal carotid and basilar arteries through an anomalous vessel penetrating the hypoglossal canal.

Discussion

Carotid-basilar anastomoses represent persistent embryonic circulatory patterns that link the carotid and vertebrobasilar systems. With the exception of extracranial proatlantal intersegmental arteries, these are named according to the cranial nerves they parallel: the persistent trigeminal, otic (acoustic), and hypoglossal arteries. Normally, these anastomoses remain functional for about 7 to 10 days during the early stage of fetal development and then obliterate at the rate the posterior communicating arteries develop (1). Failure of this obliteration results in a persistent embryonic artery.

The persistent hypoglossal artery is the second most common carotid-basilar anastomosis. Its frequency is about one sixth that of the most common one, the primitive trigeminal artery (2, 3), of which the prevalence is 0.1% to 0.2% (4). According to angiographic studies (2–5), the primitive hypoglossal artery originates from the cervical part of the internal carotid artery at the level of C-1 to C-3. After a tortuous course, it penetrates the enlarged hypoglossal canal and joins the lower portion of the basilar artery. When it is large, the proximal vertebral arteries usually are hypoplastic and the ipsilateral vertebral artery may be absent. These findings are consistent with the MR findings in our case. Differentiation between the hypoglossal and the less common proatlantal intersegmental artery on angiographic examination requires careful analysis because these primitive arteries take a similar course (6). The proatlantal intersegmental artery enters the posterior fossa through the foramen magnum, following the course of the vertebral artery. Therefore, differentiation between these primitive arteries on MR will be

Received August 5, 1993; accepted after revision September 29.

From the Departments of Radiology (N.F., T.S.) and Neurosurgery (N.S., H.T.), Suita Municipal Hospital, Osaka, Japan.

Address reprint requests to Norihiko Fujita, MD, Department of Radiology, Suita Municipal Hospital, 2-13-20, Katayama-Cho, Suita-City, Osaka 564, Japan.

AJNR 16:990–992, Apr 1995 0195-6108/95/1604–0990

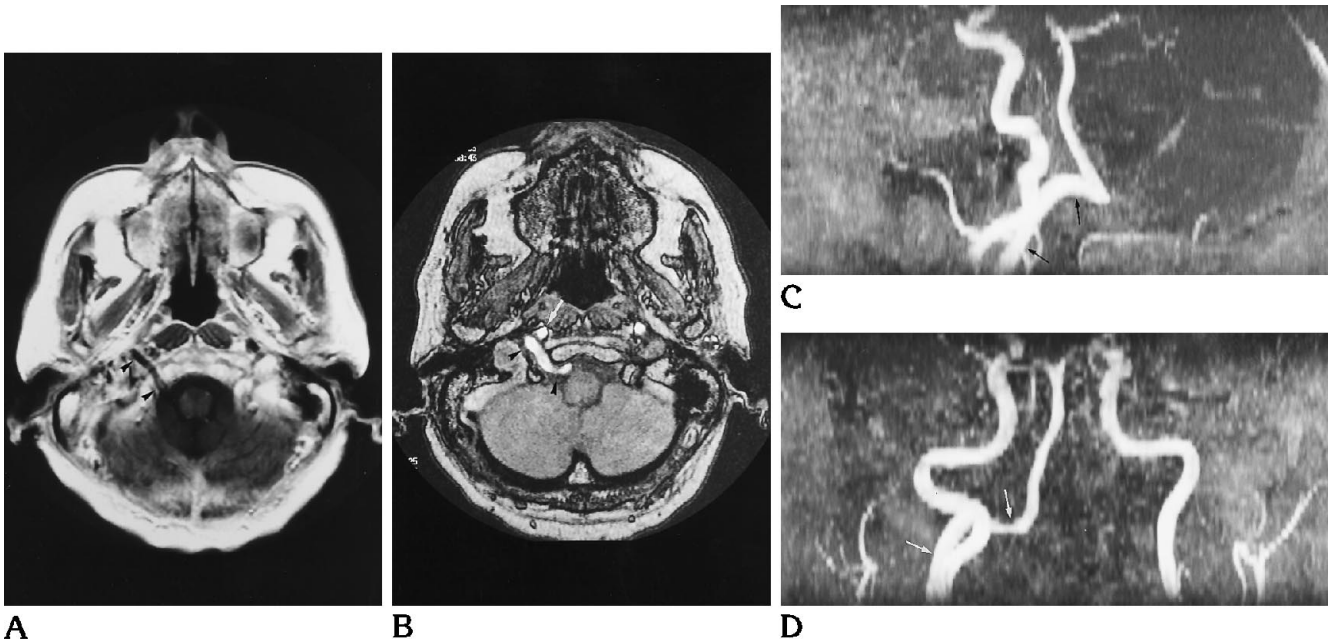

Fig 1. Spin-echo imaging and MR angiography of a persistent hypoglossal artery.

A, Postcontrast axial T1-weighted image (500/15/2 [repetition time/echo time/excitations]) at the level of the medulla oblongata shows an abnormal tubular structure of low intensity (*arrowheads*) penetrating the right hypoglossal canal.

B, Source image of axial three-dimensional time-of-flight MR angiogram (45/8/1, 25° flip angle) with magnetization transfer contrast. The abnormal tubular structure (*arrowheads*) seen in *A* produces extremely high signal intensity comparable to that of the internal carotid artery (*arrow*).

C, Sagittal and *D*, coronal reformatted views of axial MR angiogram show the course of the persistent hypoglossal artery connecting the internal carotid and basilar arteries (*arrows*). Neither vertebral artery was seen on these reformatted views because both were hypoplastic on original more caudal sections (not shown).

easy by demonstrating the foramen through which it passes.

The clinical significance of the persistent hypoglossal artery is unclear. Occasionally, aneurysms develop at the junction of this artery with the basilar artery (7–9). This vascular anastomosis may be of functional importance in patients with carotid stenoses and may provide a pathway for cerebral embolism, as reported in cases of persistent primitive trigeminal arteries (10–12).

Before the advent of MR, conventional angiography was the only method for diagnosing these primitive arteries. Since then, some cases of persistent trigeminal artery have been discovered by means of MR imaging (13–15). As illustrated in our case, when an abnormal tubular structure of low intensity penetrating the hypoglossal canal is encountered on spin-echo imaging, it suggests the presence of a persistent hypoglossal artery. MR angiography is useful for confirming the spin-echo finding and demonstrating the course of the anomalous vessel noninvasively.

References

1. Padget DH. The development of the cranial arteries in the human embryo. *Contr Embryol* 1948;32:205–261
2. Wollschlaeger G, Wollschlaeger PB. The circle of Willis. In: Newton TH, Potts DG, eds. *Radiology of the Skull Base and Brain*, vol 2. *Angiography*. St Louis: Mosby, 1974:1195–1196
3. Huber P. *Cerebral Angiography*. 2nd ed. Stuttgart: Georg Thieme, 1982:57–61
4. Lie TA. *Congenital Anomalies of the Carotid Arteries*. Amsterdam: Excerpta Medica Foundation, 1968:52–70
5. Brismar J. Persistent hypoglossal artery, diagnostic criteria: report of a case. *Acta Radiol Diagn* 1976;17:160–166
6. Anderson RA, Sondheimer FK. Rare carotid-vertebrobasilar anastomoses with notes on the differentiation between proatlantal and hypoglossal arteries. *Neuroradiology* 1976;11:113–118
7. Udvarhelyi GB, Lai M. Subarachnoid hemorrhage due to rupture of an aneurysm on a persistent left hypoglossal artery. *Br J Radiol* 1963;36:843–847
8. Huber P, Rivoir R. Aneurysm on a persistent left hypoglossal artery. *Neuroradiology* 1974;6:277–278
9. Kodama N, Ohara H, Suzuki J. Persistent hypoglossal artery associated with aneurysms: report of two cases. *J Neurosurg* 1976; 45:449–451
10. Waller FT, Simons RL, Kerber C, Kissel IO, Tanabe CT. Trigeminal artery and microemboli to the brainstem: report of two cases. *J Neurosurg* 1977;46:104–106

11. Stern J, Correll JW, Bryan RN. Persistent hypoglossal artery and persistent trigeminal artery presenting with posterior fossa transient ischemic attacks: report of two cases. *J Neurosurg* 1978;49: 614–619
12. Quencer RM, Simon J. Transient bilateral occipital lobe ischemia: microembolization through a trigeminal artery. *Neuroradiology* 1979;18:273–275
13. Richardson DN, Elster AD, Ball MR. Intrasellar trigeminal artery. *AJNR Am J Neuroradiol* 1989;10:205
14. Shintani S, Kuzuhara S, Toyokura Y. MR imaging of persistent primitive trigeminal artery. *Neuroradiology* 1990;32:79
15. Schuierer G, Laub G, Huk WJ. MR angiography of the primitive trigeminal artery: report on two cases. *AJNR Am J Neuroradiol* 1990;11:1131–1132