AJNR

Geniculate ganglion meningiomas: CT and MR appearances.

T L Larson, J M Talbot and M L Wong

AJNR Am J Neuroradiol 1995, 16 (5) 1144-1146
http://www.ajnr.org/content/16/5/1144.citation

Geniculate Ganglion Meningiomas: CT and MR Appearances

Timothy L. Larson, J. Michael Talbot, and Matthew L. Wong

Summary: We present two surgically proved cases of meningiomas that arose at the geniculate turn.

Index terms: Meninges, neoplasms; Temporal bone, neoplasms

Case Reports

Case 1

A 19-year-old woman had three episodes of left facial paralysis, each with complete resolution. The initial computed tomographic (CT) scan was interpreted as normal (Fig 1A). The patient returned 1 year later with recurrent facial paralysis. Magnetic resonance (MR) imaging showed a mass at the geniculate turn (Fig 1B). Retrospective review of the initial CT findings revealed expansion of the distal labyrinthine segment of the facial nerve and geniculate turn. The bony margins were indistinct with suggestion of faint intratumoral bone. The presumptive diagnosis was an "ossifying" hemangioma.

At surgery, a fibrotic tumor was present at the geniculate turn, which was excised along with the tumor. A greater auricular nerve graft was placed. At pathology, the mass was noted to compress the facial nerve. Microscopically, it demonstrated psammoma bodies with plump elongate spindle cells with a syncytial growth pattern. Immunohistochemical features were also consistent with the diagnosis of meningioma. Strong positive results were obtained with epithelial membrane antigen and vimentin. Stains for low-molecular-weight cytokeratin and factor VIII revealed normal levels. The patient had not regained any appreciable facial nerve function by 2 years after surgery.

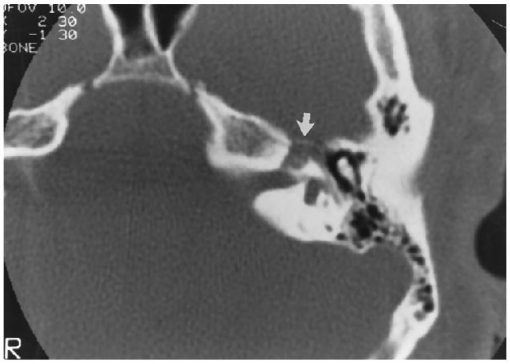

A

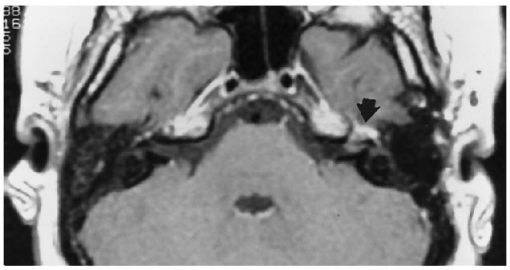

B

Fig 1. Case 1.

A, Axial CT scan (1.5-mm section, bone algorithm) shows expansion of labyrinthine segment of cranial nerve VII with expansion of the geniculate turn (*arrow*). Note unsharp margins with suggestion of either new bone or hyperostosis within the lesion.

B, Axial enhanced spin-echo MR image (600/23/4 [repetition time/echo time/excitations], 256 × 192 matrix, 3-mm section). Enhancing mass of the geniculate turn (*arrow*) extends to involve labyrinthine segment of cranial nerve VII. Fundus of the internal auditory canal also is enhanced.

Case 2

A 23-year-old woman had slowly progressive right facial paralysis of 5 years' duration. Hearing and vestibular functions were normal. A CT scan of the temporal bone obtained at another institution was interpreted as normal. In retrospect, the scans suggest expansion of the fossa of the geniculate turn on the right with abnormal calcifications within (Fig 2A). Some months later the patient returned for further evaluation. MR showed an enhancing expansile mass in the region of the right geniculate turn (Fig 2B).

Via a middle fossa approach, a 5 × 6-mm reddish granular-appearing mass enveloping the geniculate turn was identified and resected. The entire geniculate turn was resected and the facial nerve repaired with a cable graft. Microscopically, the tumor demonstrated bland nuclei with intracytoplasmic inclusions, a syncytial growth pattern

Received April 20, 1993; accepted after revision February 23, 1994.

From Seattle (Wash) Radiologists (T.L.L.); the Department of Diagnostic Radiology, University of Oregon Health Sciences, Portland (J.M.T.); and Washington Otology Neurotology Group, Seattle (M.L.W.).

Address reprint requests to Timothy L. Larson, MD, Seattle Radiologists, 1229 Madison, Suite 900, Seattle, WA 98104.

AJNR 16:1144–1146, May 1995 0195-6108/95/1605–1144

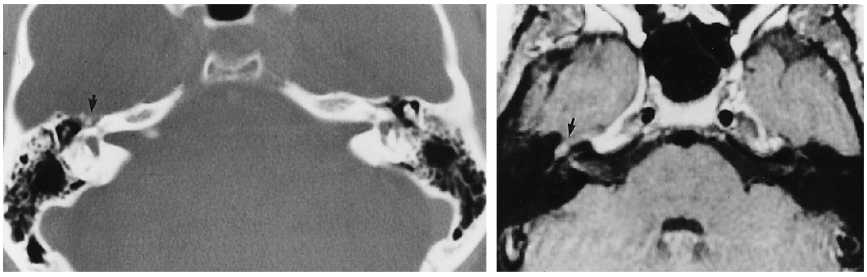

A B

Fig 2. Case 2.
A, Axial CT scan shows expansion of the geniculate turn. Note appearance of either hyperostosis or new bone formation within the lesion (*arrow*).
B, Axial enhanced T1-weighted MR image appears similar to Figure 1B, showing enhancing mass at geniculate turn (*arrow*). Cranial nerve VIII near the fundus of the internal auditory canal also is enhanced.

with psammoma bodies. Stains for epithelial membrane antigen revealed abnormal levels. The patient was doing well with good facial tone and was able to close her eye 18 months after surgery.

Discussion

Intratemporal meningiomas are rare; 85% occur in female subjects, with 30% involving the facial nerve (1). It is accepted that meningisms arise from arachnoid lining cells located in clusters around the tips of arachnoid villi (2). These cells have been noted at sites within the temporal bone. Within the internal auditory canal, arachnoid tissue envelops cranial nerves VII and VIII, extending along cranial nerve VII to the geniculate turn. Within the jugular foramen, arachnoid tissue predominates in the anterior portion. Focal brain herniations accompanied by arachnoid tissue have been noted involving the tegmen and roof of the eustachian tube (2).

In 15% of patients, the geniculate turn may be partially or completely uncovered by bone. This is particularly true in newborns, where dura of the middle cranial fossa can lie in continuity with the geniculate turn (3). In these instances it is conceivable that a meningioma could arise from the overlying dura, secondarily involving the geniculate turn. In each of our cases, there was no apparent involvement of the overlying dura, which was easily elevated to expose the geniculate turn at the time of surgery.

The CT appearance of both lesions was of an expansile mass involving the geniculate turn. The bony margins were unsharp with suggestion of intratumoral bone. The appearance suggested an ossifying hemangioma (4, 5). The CT appearance of geniculate turn meningiomas has been previously described (6, 7). Careful attention to the course of the facial nerve cannot be overstressed, because very small lesions might be apparent only on CT.

The MR examination included 3-mm T1-weighted axial images before and after contrast administration. The 5-mm T2-weighted head images were unrevealing. The studies incorporated the entire facial nerve from the brain stem to stylomastoid foramen. Each showed a small enhancing mass at the geniculate turn. Careful attention to technique is stressed, as these lesions might not be apparent on routine imaging of the head. Axial images can be supplemented with coronal and sagittal images. Other primary lesions at the geniculate turn with this appearance include nerve sheath tumors and hemangiomas. Schwannomas arising at the geniculate turn tend to have smooth, sharp margins on CT. They are reported to be somewhat larger than meningiomas or hemangiomas at presentation (4, 5). The MR appearance is too similar to that of meningioma to be differentiated with any accuracy. Intratemporal facial nerve hemangiomas involving the geniculate turn have been reported with increased frequency (4, 5, 8). Facial paralysis occurs early. CT is reported to be more sensitive for their detection, although, in previous reports, contrast-enhanced MR was not performed in patients who had lesions at the geniculate turn (5, 8). On CT, the involved bone margins are unsharp when compared with schwannomas. Intratumoral bone spicules or "honeycomb" bone have been described (4, 5). The term *ossifying hemangioma* has been coined to describe these lesions. To date, they cannot be readily differentiated from meningiomas. This is of limited importance, however, because surgery via a middle cranial fossa approach is the treatment of choice for both.

In summary, meningiomas arising at the geniculate turn are not readily differentiated from hemangiomas. Both cause facial paralysis when small. Careful attention to the course of the facial nerve on both CT and MR is critical.

References

1. Rietz DR, Ford GN, Brandenburg JH, et al. Significance of apparent intratympanic meningiomas. *Laryngoscope* 1983;93:1397–1404.
2. Nager GT, Hiroy J, Hoeplinger M. Meningiomas invading the temporal bone with extension to the neck. *Am J Otolaryngol* 1983;4: 297–324.
3. Rhoton AL, Pulec JL, Hall GM, et al. Absence of bone over the geniculate ganglion. *J Neurosurg* 1968;28:48–53.
4. Curtin HD, Jensen JE, Barnes L, et al. "Ossifying" hemangiomas of the temporal bone: evaluation with CT. *Radiology* 1987;164:831–835.
5. Lo WW, Horn KL, Carberry JN, et al. Intratemporal vascular tumors: evaluation with CT. *Radiology* 1986;159:181–185.
6. MA KH, Fagan PA. Facial nerve tumors or "all that palsies is not bells" *Aust N Z J Med* 1988;18:613–616.
7. Hooper R, Siv K, Cousius V. Temporal bone meningiomas. *Aust N Z J Surg* 1990;60:779–786.
8. Shelton C, Brackmann DE, Lo WWM, et al. Intratemporal facial nerve hemangiomas. *Otolaryngol Head Neck Surg* 1991;104:116–121.