

The **next generation** GBCA
from Guerbet is here

Explore new possibilities >

Guerbet | 

© Guerbet 2024 GUOB220151-A

AJNR

Cerebellar herniation and infarction as a complication of an occult postoperative lumbar dural defect.

R T Andrews and T M Koci

AJNR Am J Neuroradiol 1995, 16 (6) 1312-1315

<http://www.ajnr.org/content/16/6/1312>

This information is current as
of February 28, 2024.

Cerebellar Herniation and Infarction as a Complication of an Occult Postoperative Lumbar Dural Defect

Robert T. Andrews and Timothy M. Koci

Summary: A patient who underwent lumbar spine surgery sustained an occult dural injury. After unrecognized suction drainage of cerebrospinal fluid through a surgical drain, caudal herniation of the cerebellum with superior cerebellar infarction developed. This mechanism should be considered in patients in whom acute mental status changes develop after spinal surgery.

Index terms: Spine, surgery; Cerebrospinal fluid, leakage; Cerebellum, infarction; Iatrogenic disease or disorder

The controlled release of cerebrospinal fluid from the lumbar thecal sac was described by Quinke in 1891 (1). Reports of cerebellar herniation attributed to lumbar aspiration followed shortly thereafter (2). Lumbar aspiration then became an established practice in the diagnosis and treatment of central nervous system disease. Brain herniation is a recognized risk when cerebrospinal fluid aspiration is performed in patients with obstructive hydrocephalus or intracranial masses (3). Herniation secondary to prolonged aspiration of cerebrospinal fluid from a postoperative lumbar spine is described in this report.

Case Report

A 36-year-old white man was transferred to our facility 3 days after undergoing Harrington rod placement for lumbar scoliosis. It was his fourth spinal surgery. As is standard practice in such cases, a Jackson-Pratt drain was placed in the surgical bed and connected percutaneously to Hemovac suction. Thirty-six hours after surgery, there was an abrupt deterioration in mental status, with progressive worsening over the subsequent 2 days. A computed tomography (CT) scan at the referring facility demonstrated communicating hydrocephalus and bilateral cerebellar hemorrhagic infarction (Fig 1). At the time of transfer, Glasgow Coma Scale rating was 3, with decerebrate posturing and an absent gag reflex. Surgical dressings were clean and dry.

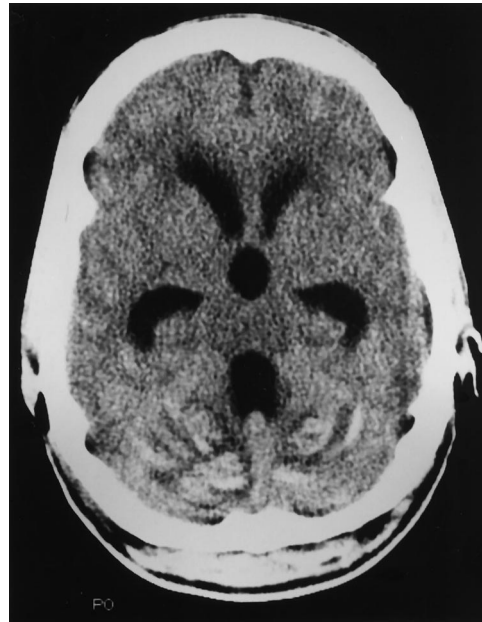


Fig 1. Axial CT shows ventricular enlargement and hemorrhagic cerebellar infarction.

Ventriculostomy at our facility revealed an intracranial pressure of less than 5 cm H₂O with clear cerebrospinal fluid. Cerebral angiography demonstrated a displaced choroidal point and descent of the posterior inferior cerebellar arteries consistent with tonsillar herniation. No arterial or venous occlusions, aneurysms, or vascular malformations were identified. Brain magnetic resonance (MR) was performed on postoperative day 5 and was compared with a previous MR (obtained 5 years before for the evaluation of a broad-based, spastic gait). The original study was notable only for cerebellar atrophy (Fig 2). The second study, however, showed panventricular enlargement and bilateral superior cerebellar hemorrhagic infarction (Fig 3A), and also clearly demonstrated herniation of the cerebellar tonsils (Fig 3B).

Over a period of 6 days, a persistently high volume of serosanguinous fluid was collected from the patient's surgical drain, ranging from 250 mL to as much as 400 mL

Received January 26, 1994; accepted after revision June 14.

From the Department of Radiology, Harbor-UCLA Medical Center, Torrance, Calif.

Address reprint requests to Robert T. Andrews, MD, Department of Radiology, Harbor-UCLA Medical Center, 1000 W Carson St, Torrance, CA 90509.

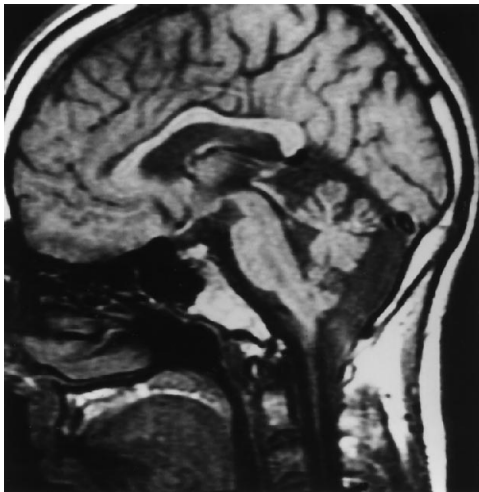


Fig 2. Sagittal T1-weighted baseline MR image shows cerebellar atrophy. There is no tonsillar ectopia. (The inferior aspect of the posterior fossa is seen in a slightly parasagittal projection; volume averaging causes the unusual appearance of the inferior medulla and the spinal cord.)

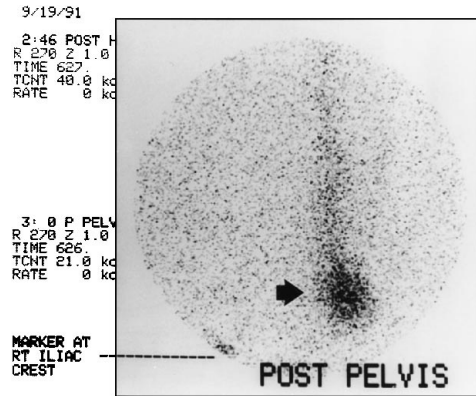


Fig 4. Scintigraphy of the neural axis after removal of the surgical drain. Pooling of isotope in the surgical bed (*arrow*) is consistent with a dural leak. Note that the iliac crest marker is mislabeled; it actually indicates the *left* iliac crest.

over 24 hours. The ventriculostomy (open to gravity) produced an average of just 87 mL per 24-hour period. The intracranial pressure ranged from 0 to 9 cm H₂O. After removal of the surgical drain on postoperative day 6, ventriculostomy output increased steadily, averaging 260 mL per 24 hours over the next 6 days. The intracranial pressure did not change significantly. Isotope cisternography of the brain and neural axis was performed immediately after removal of the surgical drain. Technetium Tc 99m pentetate was injected through the ventriculostomy and demonstrated pooling in the lumbar region, corresponding to the surgical bed (Fig 4).

The patient's mental status began to improve slowly after removal of the drain. His pupils were reactive 36 hours later, and he had spontaneous respiration after 72 hours. Within 1 week, he was able to follow commands

with his eyes, tongue, and head, but remained quadraparetic. Minimal motor function of the hands was noted on postoperative day 27 as the patient was being returned to the originating institution. A follow-up MR performed there 47 days after surgery (41 days after removal of the drain) showed ex vacuo dilatation of the fourth ventricle and ascent of the cerebellum to a normal position (Fig 5).

Discussion

The series of events that we postulate in this case are these: first, a de facto shunt was inadvertently created by positioning the surgical drain in proximity to an occult dural arachnoid tear; second, because the drain was under con-

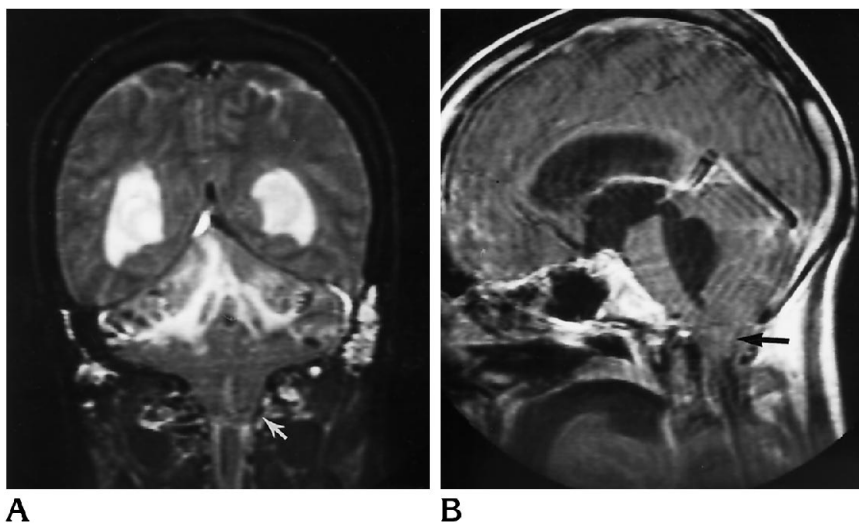


Fig 3. A, T2-weighted coronal image after placement of a paraspinous lumbar drain after scoliosis surgery shows hemorrhagic infarction, ventricular enlargement, and herniation of the cerebellar tonsils (*arrow*). B, Sagittal T1-weighted image shows ventricular enlargement and cerebellar herniation (*arrow*).

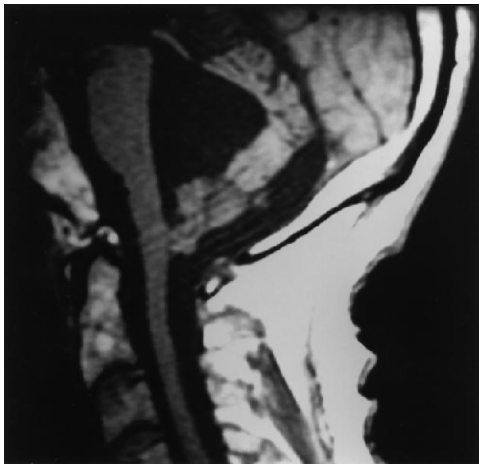


Fig 5. Sagittal T1-weighted MR image 41 days after removal of the paraspinous drain. This demonstrates ex vacuo dilatation of the fourth ventricle and return of the cerebellum to a normal position.

tinuous suction, this fistula remained patent, causing a persistent pressure gradient across the foramen magnum and leading to tonsillar herniation; and third, removal of the drain restored the normal cerebrospinal fluid flow dynamics, allowing the cerebellum to resume its normal position. We believe that cerebellar infarction was the result of transient traction, kinking, or spasm of the superior cerebellar arteries, with hemorrhage following reperfusion.

Tonsillar herniation after chronic spinal subdural-peritoneal shunting has been reported in several previous papers (4). In all of the reviewed cases, the shunts were created to correct communicating hydrocephalus and were passive systems. In other words, the excess fluid was allowed to drain according to physiologic pressure gradients. Neurologic symptoms developed after months to years but resolved (or improved) after posterior fossa decompressions or removal of the shunts. In a case described by Welch, a follow-up ventriculogram clearly demonstrated ascent of the herniated tonsils to a normal position after the patient's shunt was closed (5).

Tonsillar displacement has also been associated with the syndrome of intracranial hypotension. Rando (6) and Fishman (7) reported a total of three such patients in whom intracranial hypotension was spontaneous. Dural leaks were identified by isotope studies in all three patients, and all improved with conservative treatment. No cause of the leaks could be identified. Pannullo (8) reported six patients with intracranial hypotension and downward dis-

placement of the brain, three of whom had tonsillar herniation. Two of these had intracranial hypotension that was spontaneous and idiopathic; in the other intracranial hypotension developed after diagnostic lumbar puncture. In all three, tonsillar herniation subsequently resolved or improved.

The current case differs from these others in that the intracranial hypotension and tonsillar herniation were a complication of spinal surgery. Inadvertent opening of the dura during such procedures is not uncommon. In several large series, the reported incidence ranges from 0.3% to 5.9% (9-12). The incidence is higher in reoperation (13). When recognized at the time of surgery, dural injuries are usually repaired. If closure is not performed, most dural tears seal spontaneously in 4 to 5 days (14). This process, however, requires tamponade of cerebrospinal fluid flow by surrounding tissues. Tamponade was not present in the current case until removal of the surgical drain. In fact, continuous aspiration of fluid provided the mechanism for maintaining a high volume of flow through the dural rent.

Cerebrospinal fluid is produced at a rate of 400 to 500 mL per 24-hour period in most adults (15). The total volume is maintained by arachnoid granulations, which reabsorb cerebrospinal fluid at a rate that varies directly with cerebrospinal fluid pressure. Reabsorption ceases at a pressure below 7 cm H₂O (15). In the current case, the cause of the acute herniation was suspected because of low ventriculostomy output in the face of a very low intracranial pressure, combined with copious serous drainage from the lumbar site. The combined average output from both sites was 469 mL per 24 hours.

A definitive diagnosis of cerebrospinal fluid aspiration by the lumbar drain cannot be made in this case, because the drain was removed before scintigraphy. However, pooling of isotope in the surgical bed, together with the subsequent clinical and radiographic improvement, are highly compelling if circumstantial evidence.

In conclusion, when acute mental status changes develop after spinal surgery, the possibility of an occult dural injury with secondary tonsillar herniation should be considered along with other possible causes. This is especially true if there is a persistent high volume of drainage from the surgical site. The diagnosis can be

made promptly with scintigraphy of the neural axis.

Acknowledgments

We thank C. Mark Mehringer, MD, and Daniel Braslau, MD, for their assistance in the preparation of this manuscript.

References

1. Quinke H. Die lumbalpunktion des hydrocephalus. *Berlin klin Wochenschr* 1891;32:861–862
2. Fürbringer P. Plötzliche todesfalle nach Lumbalpunktion. *Centralblatt Innere Med* 1896;17:1–8
3. Adams RD, Victor M. *Principles of Neurology*. 5th ed. New York: McGraw Hill, 1993:11–12
4. Chumas PD, Drake JM, Del Bigio MR. Death from chronic tonsillar herniation in a patient with lumboperitoneal shunt and Crouzon's disease. *Br J Neurosurg* 1992;6:595–599
5. Welch K, Shillito J, Stränd R, Fischer EG, Winston KR. Chiari I "malformation": an acquired disorder? *J Neurosurg* 1981;55:604–609
6. Rando TA, Fishman RA. Spontaneous intracranial hypotension: report of two cases and review of the literature. *Neurology* 1992;42:481–487
7. Fishman RA, Dillon WP. Dural enhancement and cerebral displacement secondary to intracranial hypotension. *Neurology* 1993;43:609–611
8. Pannullo SC, Reich JB, Krol G, Deck MDF, Posner JB. MRI changes in intracranial hypotension. *Neurology* 1993;43:919–926
9. Swanson HS, Fincher EF. Extradural arachnoid cysts of traumatic origin. *J Neurosurg* 1947;4:530
10. Spangfort EV. The lumbar disk herniation: a computer-aided analysis of 2504 operations. *Acta Orthop Scand (Suppl)* 1972;142:1–95
11. Oppel F, Schramm J, Schirmer M, et al. Results and complicated course after surgery for lumbar disc herniation. *Adv Neurosurg* 1977;4:36–51
12. Twerdy K. Spondylo-Disicitis nach Bandschieben-operationen. *Zentralbl Neurochir* 1978;39:155–176
13. Wiesel SW. *The Multiply-Operated Lumbar Spine: Instructional Course Lecture*. St Louis: CV Mosby, 1985;34:68–77
14. Naffziger HO, Boldrey EB. Surgical treatment of the nervous system. In: Bancroft FW, ed. *Surgery of the Spinal Cord*. Philadelphia: JB Lippincott Co, 1946:534
15. Brumback RA. Anatomic and physiologic aspects of the cerebrospinal fluid space. In: Herndon RM, Brumback RA, eds. *The Cerebrospinal Fluid*. Boston: Kluwer, 1989:15–43