

Generic Contrast Agents

Our portfolio is growing to serve you better. Now you have a *choice*.



FRESENIUS
KABI

[VIEW CATALOG](#)

AJNR

The 'gooseneck' concept in microvascular retrieval.

T L Tytle, R C Prati, Jr and S T McCormack

AJNR Am J Neuroradiol 1995, 16 (7) 1469-1471

<http://www.ajnr.org/content/16/7/1469.citation>

This information is current as
of May 12, 2025.

The 'Gooseneck' Concept in Microvascular Retrieval

Timothy L. Tittle, Ronald C. Prati, Jr, and Steven T. McCormack

Summary: Two clinical applications of a fixed-loop snare microcatheter retrieval device are described, including a catheter modification for improved trackability.

Index terms: Catheters and catheterization, instruments; Interventional neuroradiology

Percutaneous devices have long been used for the retrieval of foreign bodies from major vessels. Only recently have devices been designed of a caliber practical enough for use in the neurovascular system. We describe two cases in which a microretrieval system was used to remove foreign bodies from the extracranial carotid artery and the intracranial circulation. In one case, a hybrid retrieval system allowed recovery of an otherwise nearly inaccessible malpositioned microcoil.

Case Reports

Case 1

A 48-year-old woman with cirrhosis required a transjugular intrahepatic portosystemic shunt for repeated episodes of variceal bleeding. After several unsuccessful attempts to access the right internal jugular vein with a microintroduction system (Cook, Bloomington, Ind), the common carotid artery was inadvertently entered and the 0.018-in (0.4-mm) guide wire took a cephalad course. On retraction of the wire, resistance was noted and it fractured with the terminal 4 cm embolizing to the carotid bifurcation (Fig 1A). The shunt procedure was aborted, and from a transfemoral approach, a 5.5F Headhunter 1 catheter (Cook) with a 0.038-in (0.9-mm) inner lumen was advanced into the right common carotid artery. In a coaxial fashion, a "Goose Neck" Amplatz 4-mm microsnare (Microvena, White Bear Lake, Minn) was advanced to encircle the caudal end of the severed guide wire. The snare was then closed by advancing the retrieval catheter over the snare (Fig 1B). The severed wire and catheters were then withdrawn and removed as a unit from the common femoral artery.

Case 2

A 3-year-old boy with a vein of Galen malformation, choroidal type, was undergoing embolization of the left anterior choroidal artery with 3-mm-diameter braided occlusive devices (BOD; Target Therapeutics, Fremont, Calif). Several similar coils had previously been placed in this artery when, after an unexpected interruption, it was noted that the delivery catheter had flipped into the supraclinoid internal carotid artery and a coil had migrated out of the catheter lodging at the junction of the supraclinoid internal carotid artery and the A1 segment (Fig 2A and B). A Retriever-18 endovascular snare (Target Therapeutics) was initially used in a coaxial fashion through a 5.5F Headhunter 1 catheter positioned distally in the left cervical internal carotid artery. Advancement of the microcatheter through the tortuous carotid siphon proved extremely difficult, and after two or three closures of the loop without grasping the coil, the loop could no longer be advanced or retracted. The retrieval was temporarily aborted, and a 6F sheath was left in the femoral artery. The patient was immediately given a bolus of heparin (60 U/kg) followed by a heparin drip at approximately 12 U/kg per hour. The next day, after receiving the Goose Neck microsnare (Microvena), a 5.5F Headhunter 1 catheter (Cook) was advanced through the sheath into the distal left cervical internal carotid artery and the snare was advanced in a coaxial fashion. This time the snare system would not negotiate the tortuous carotid siphon. The Microvena guiding catheter was then exchanged for a 150-cm Fastracker 18 catheter (Target) and the 2-mm loop snare cable system was easily advanced into position. The malpositioned coil was retrieved without complication. Visual inspection of the retrieved coil revealed no associated thrombus.

Discussion

With an almost exponential increase in the use of endovascular devices in head and neck vessels, there has been a corresponding need for an effective microretrieval system. Recently, Target Therapeutics has marketed a single-wire loop snare consisting of a variable-stiffness

Received March 14, 1994; accepted after revision July 13.

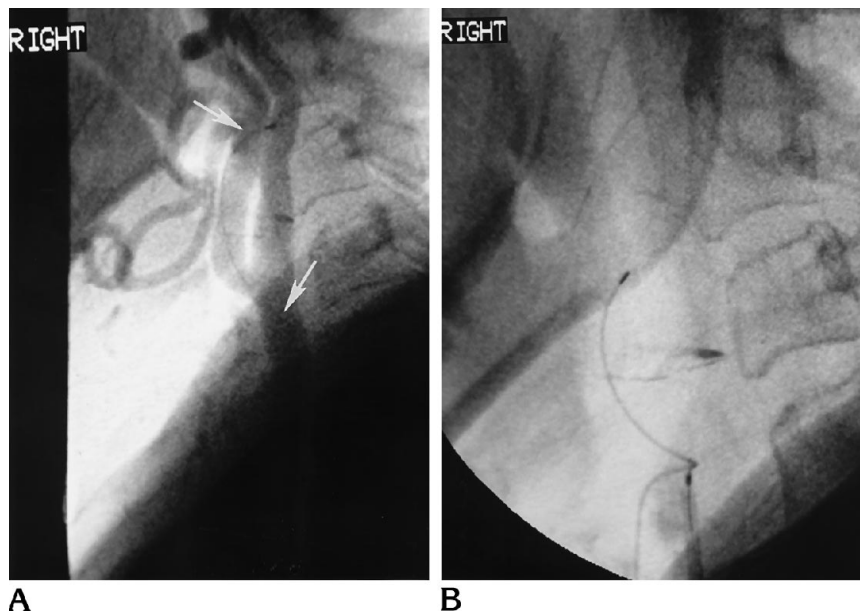
From the Department of Radiological Sciences, University of Oklahoma Health Sciences Center, Oklahoma City.

Address reprint requests to Timothy L. Tittle, MD, Department of Radiological Sciences, University of Oklahoma Health Sciences Center, UH-1NP606, PO Box 26901, Oklahoma City, OK 73190-3020.

AJNR 16:1469-1471, Aug 1995 0195-6108/95/1607-1469 © American Society of Neuroradiology

Fig 1. A, Lateral digital subtraction angiogram of the right carotid bifurcation shows severed guide wire segment (arrows) within the common and external carotid arteries.

B, Goose Neck Amplatz microsnares grasps the midaspect of the guide wire.



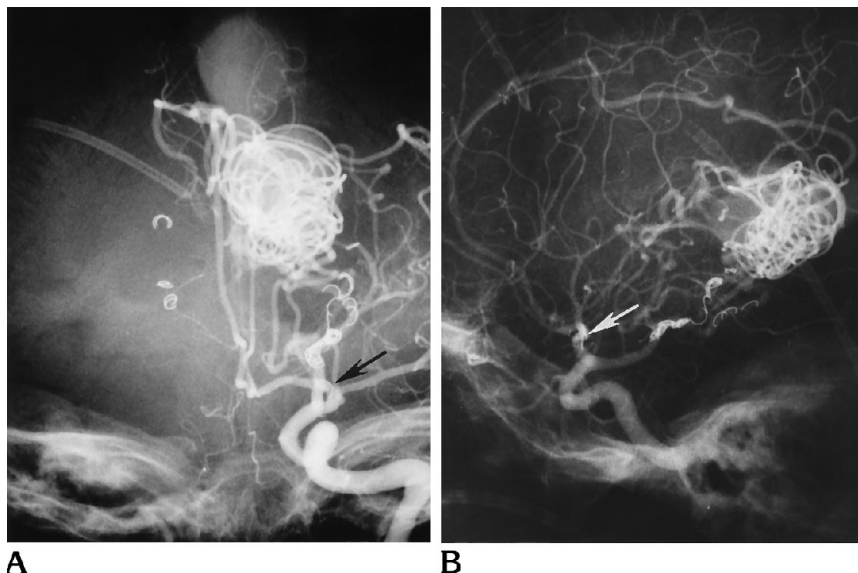
polypropylene and polyethylene catheter that tapers from 3F to 2.2F (Tracker 18) or 2.6F to 2.0F (Tracker 10) through which a stainless steel wire is affixed to the platinum tip marker and looped back through the catheter lumen to form a single-wire loop snare. By retracting the wire the loop is closed, grasping the foreign body. This system has been successfully used to retrieve a severed 0.016-in (0.4-mm) wire and a 3F catheter from the distal left vertebral and basilar arteries, respectively (1). In another case, this retrieval device was used to remove a severed 3F catheter from the external carotid

and occipital arteries (1). The same retrieval device was used successfully 91% of the time in a canine model to retrieve a variety of foreign objects from the renal, pulmonary, hepatic, brachiocephalic, subclavian, carotid, and maxillary arteries (2).

The nitinol gooseneck snare concept has been used in large vessels (3–8), but a smaller caliber microsnares has become commercially available only recently (Fig 3). Both systems use a nickel-titanium (nitinol) wire oriented at a right angle to the catheter tip. The radiopaque loop of the microsnares is available in 2- and

Fig 2. A, Anteroposterior left internal carotid artery angiogram shows malpositioned coil (arrow) at the junction of the supraclinoid internal carotid artery and A1 segment.

B, Lateral angiogram shows the malpositioned coil (arrow).



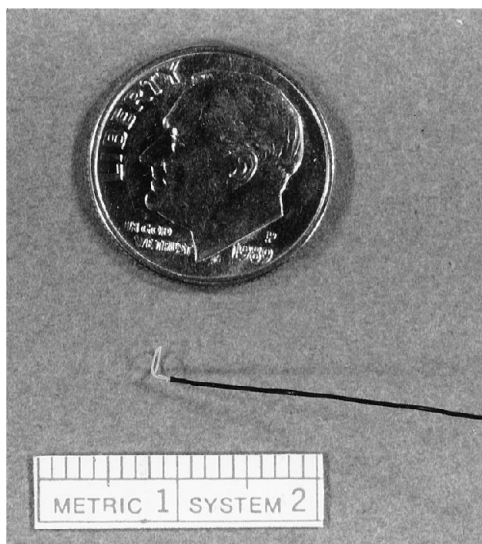


Fig 3. Distal wire core and loop of the 2-mm Goose Neck Amplatz microsnare.

4-mm diameters of 175-cm cable length. The packaged catheter has a radiopaque tip and is 150 cm long.

A major concern of any retrieval system is the ease with which it can be maneuvered into position. In their canine model, Graves et al (2) did not mention encountering accessibility difficulty with the variable-loop microsnare of the Target design. Our limited experience is characterized by moderate difficulty in negotiating a tortuous course. Furthermore, opening and closing of the loop became progressively more difficult and exacerbated this steering problem, rendering the snare useless and necessitating its removal. Smith et al (1) also found that the system did not open and close as easily as larger systems did.

An additional advantage of a nonfixed wire system such as the Microvena snare is that it is exchangeable. This can be helpful when the foreign object cannot be retrieved but continued access is desired.

Although currently available systems are adequate for most cases involving endovascular retrieval, only a marriage of two separate systems, the Microvena loop cable and the Fastracker catheter, allowed removal of the small coil from the intracranial circulation. The nearly frictionless outer surface of the Fastracker catheters allows for far easier advancement through tortuous vessels. The inner catheter coating fosters easier retractability of the loop snare with resultant longer functional life, which is invaluable if several attempts are needed to grasp the

foreign body. The platinum catheter tip enables accurate determination of the relationship between the loop snare and the end of the catheter. The fixed 90° angle of the loop snare to the wire cable facilitates entrapment of the foreign body within the loop. By torquing the fixed loop, steerability is added that is not found in the variable-loop snare. This hybrid system should not be taken as the ultimate device for microvascular retrieval of foreign bodies. Care should be executed when frictionless catheters such as the Fastracker are used, because we have found them more likely than the more conventional catheters to spring out of position when under tension in serpiginous vessels.

In a rapidly advancing technologic field such as interventional neuroradiology, a system for the retrieval of malpositioned or embolized foreign objects is critical. Although the optimal retrieval device might not be available yet, the hybridized system of the Fastracker catheter and the Goose Neck microsnare cable appears to be the best currently available package.

Acknowledgment

We thank Sidney P. Traub, MD, for assistance in making this manuscript possible and Van V. Halbach, MD, for suggesting the use of the loop snare.

References

1. Smith TP, Graves VB, Halbach VV, et al. Microcatheter retrieval device for intravascular foreign body removal. *AJNR Am J Neuroradiol* 1993;14:809-811
2. Graves VB, Rappe AH, Smith TP, Sepetka I, Ahuja A, Strother CM. An endovascular retrieving device for use in small vessels. *AJNR Am J Neuroradiol* 1993;14:804-808
3. Saeed M, Knowles HJ Jr, Brems JJ, Takiff H. Percutaneous retrieval of a large Palmaz stent from the pulmonary artery. *J Vasc Interv Radiol* 1993;4:811-814
4. Cekirge S, Weiss JP, Foster RG, Neiman HL, McLean GK. Percutaneous retrieval of foreign bodies: experience with the nitinol gooseneck snare. *J Vasc Interv Radiol* 1993;4:805-810
5. Siegel EL, Robertson EF. Percutaneous transfemoral retrieval of a free-floating titanium Greenfield filter with an Amplatz Goose Neck snare. *J Vasc Interv Radiol* 1993;4:565-568
6. Cekirge S, Foster RG, Weiss JP, McLean GK. Percutaneous removal of an embolized Wallstent during a transjugular intrahepatic portosystemic shunt procedure. *J Vasc Interv Radiol* 1993;4:559-560
7. Cohen GS, Ball DS. Delayed Wallstent migration after a transjugular intrahepatic portosystemic shunt procedure: relocation with a loop snare. *J Vasc Interv Radiol* 1993;4:561-563
8. Yedlicka JW Jr, Carlson JE, Hunter DW, Castaneda-Zuniga WR, Amplatz K. Nitinol gooseneck snare for removal of foreign bodies: experimental study and clinical evaluation. *Radiology* 1991;178:691-693